



Mink Dissection Review

Menu

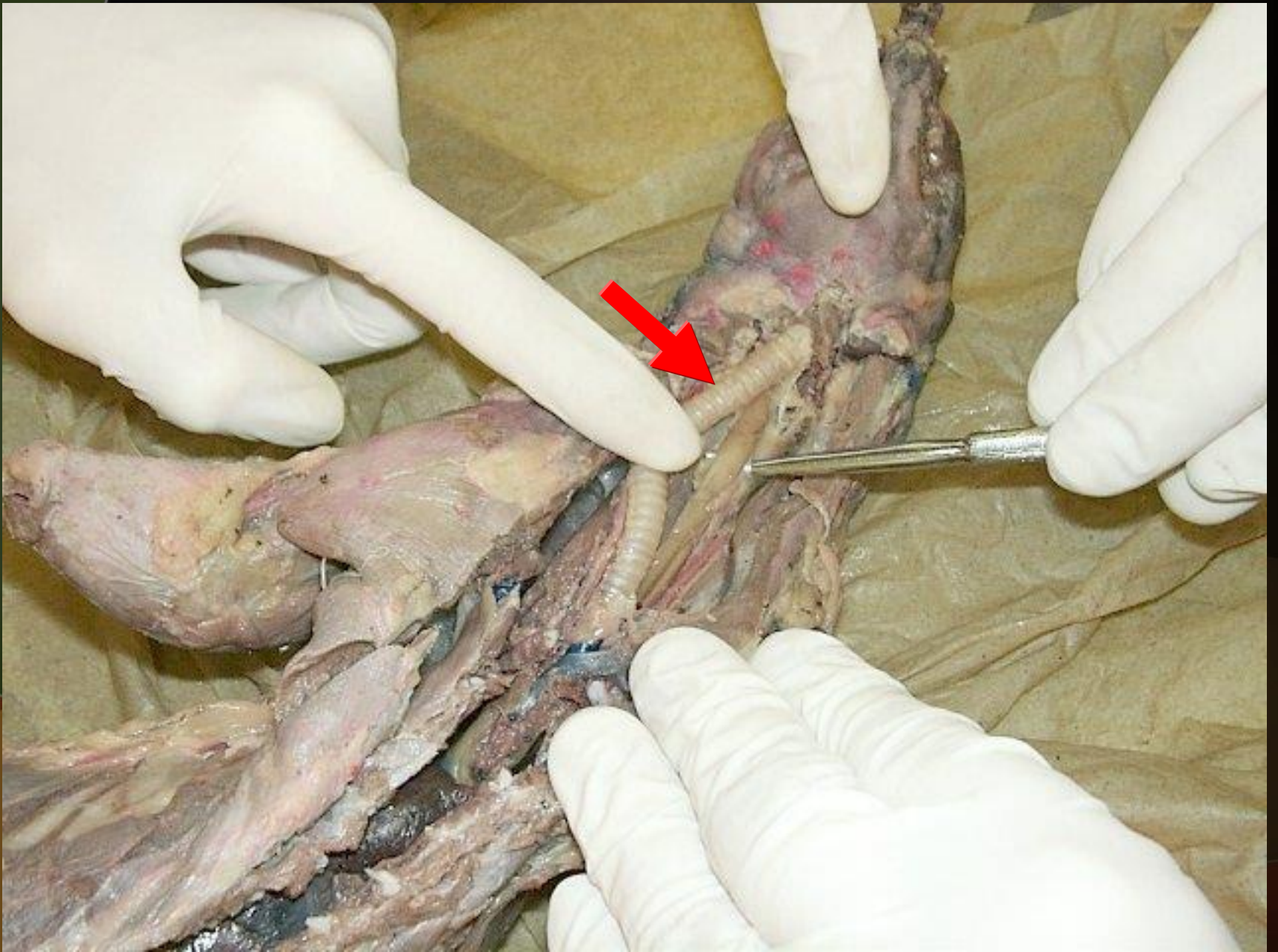
- Neck & Thoracic Cavity
- Abdominal Cavity
- Heart
- Blood Vessels
- Urinary System
- Reproductive Systems



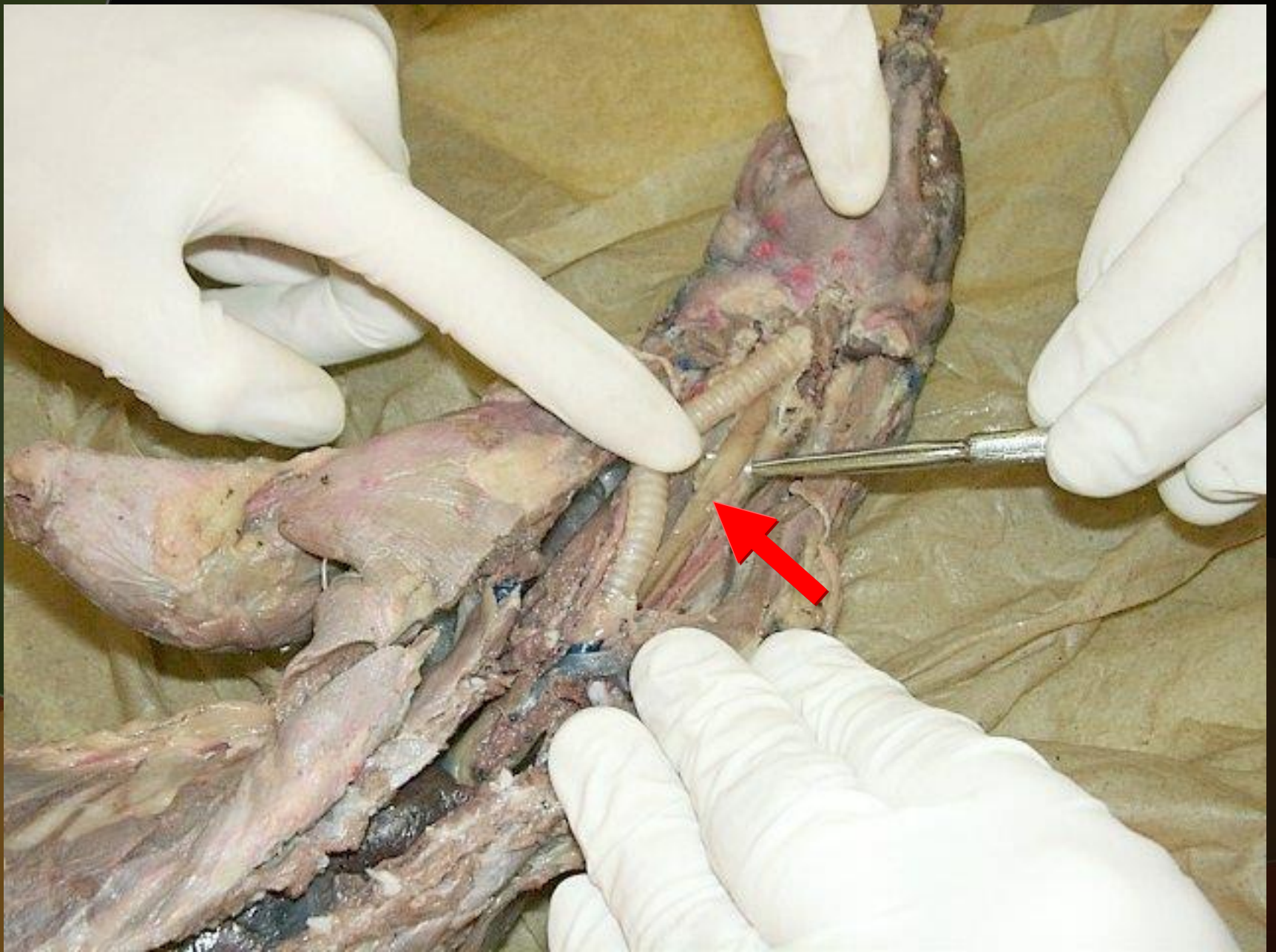
Neck & Thoracic Cavity



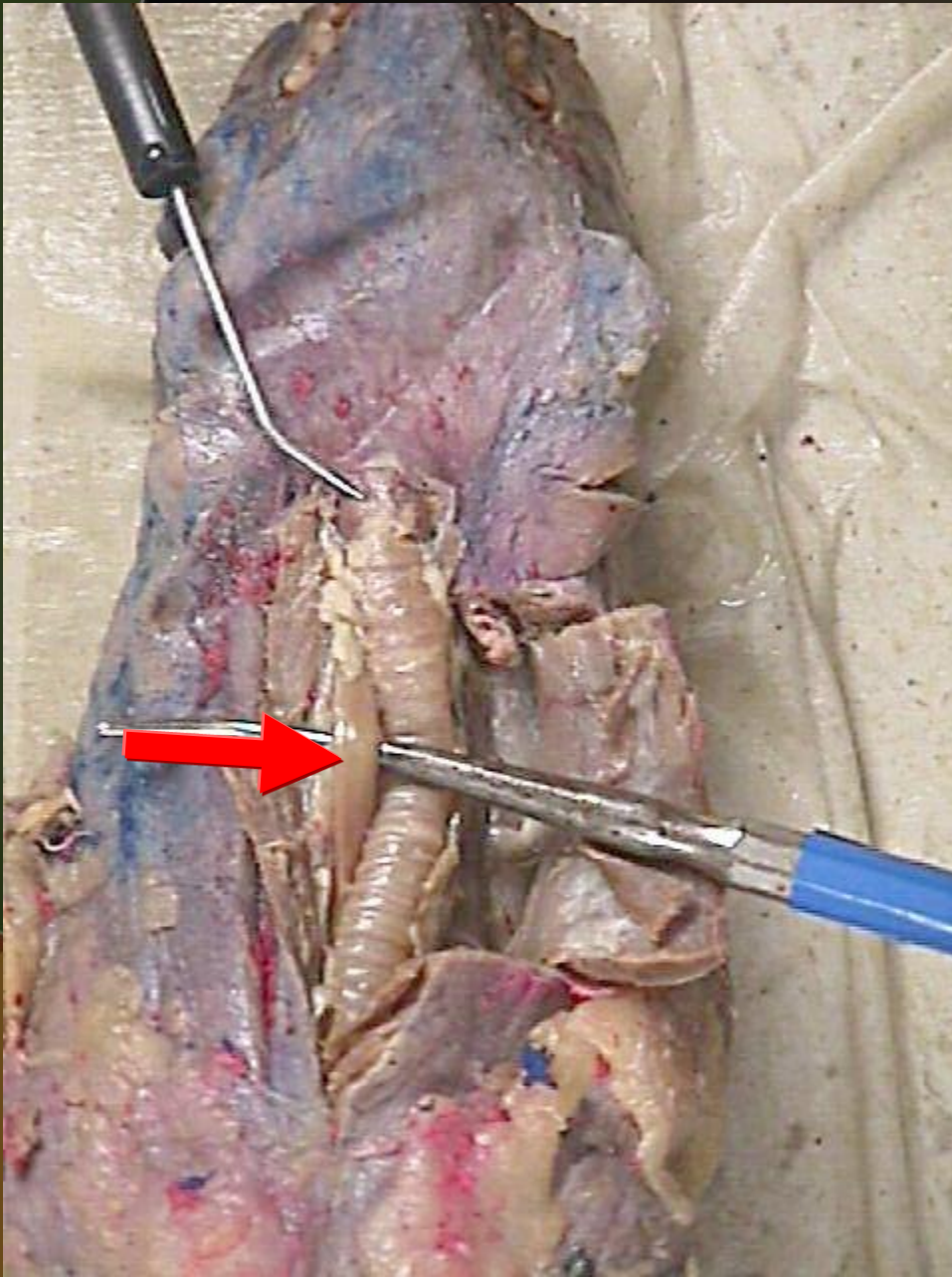
Trachea



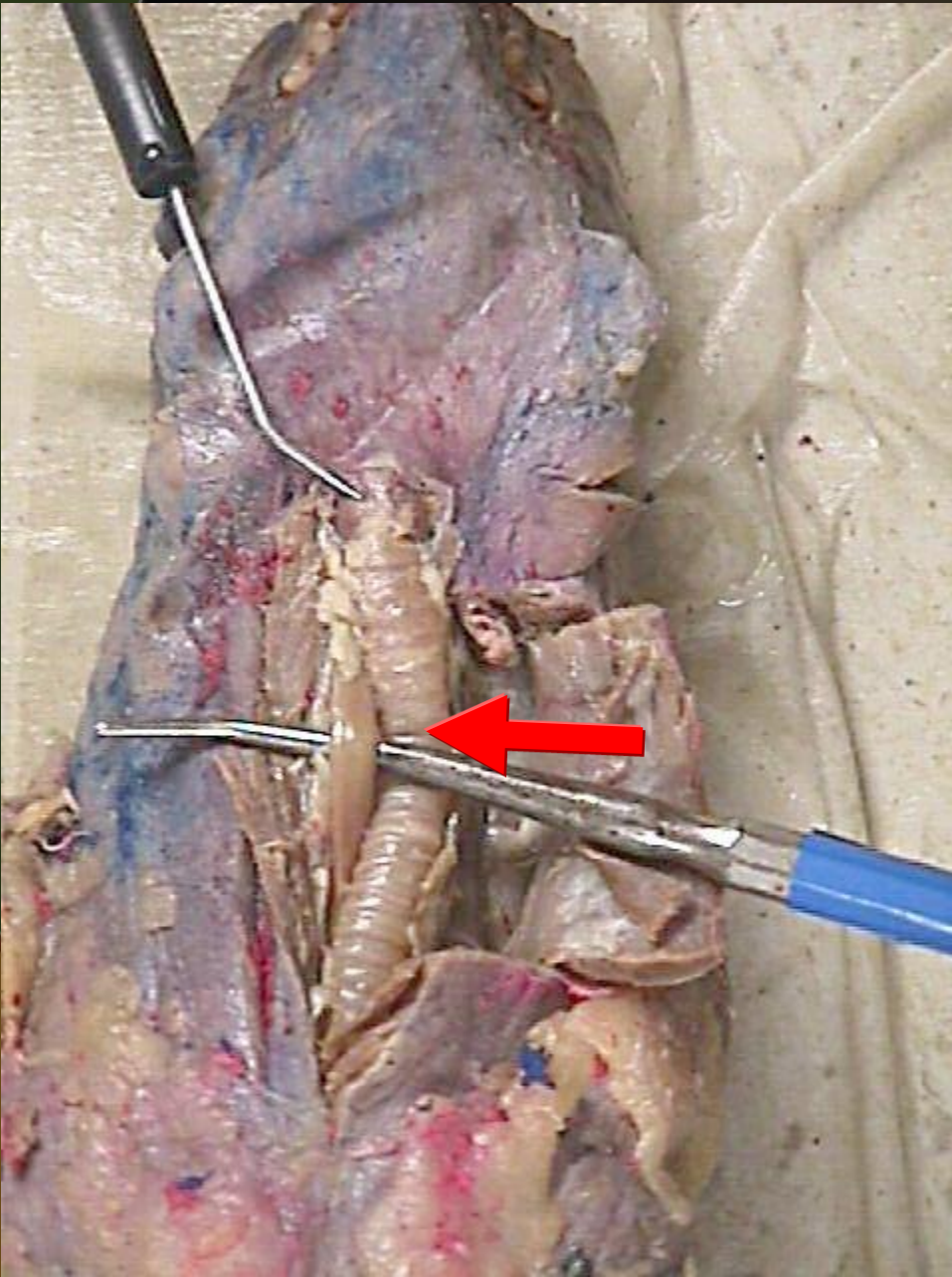
Esophagus



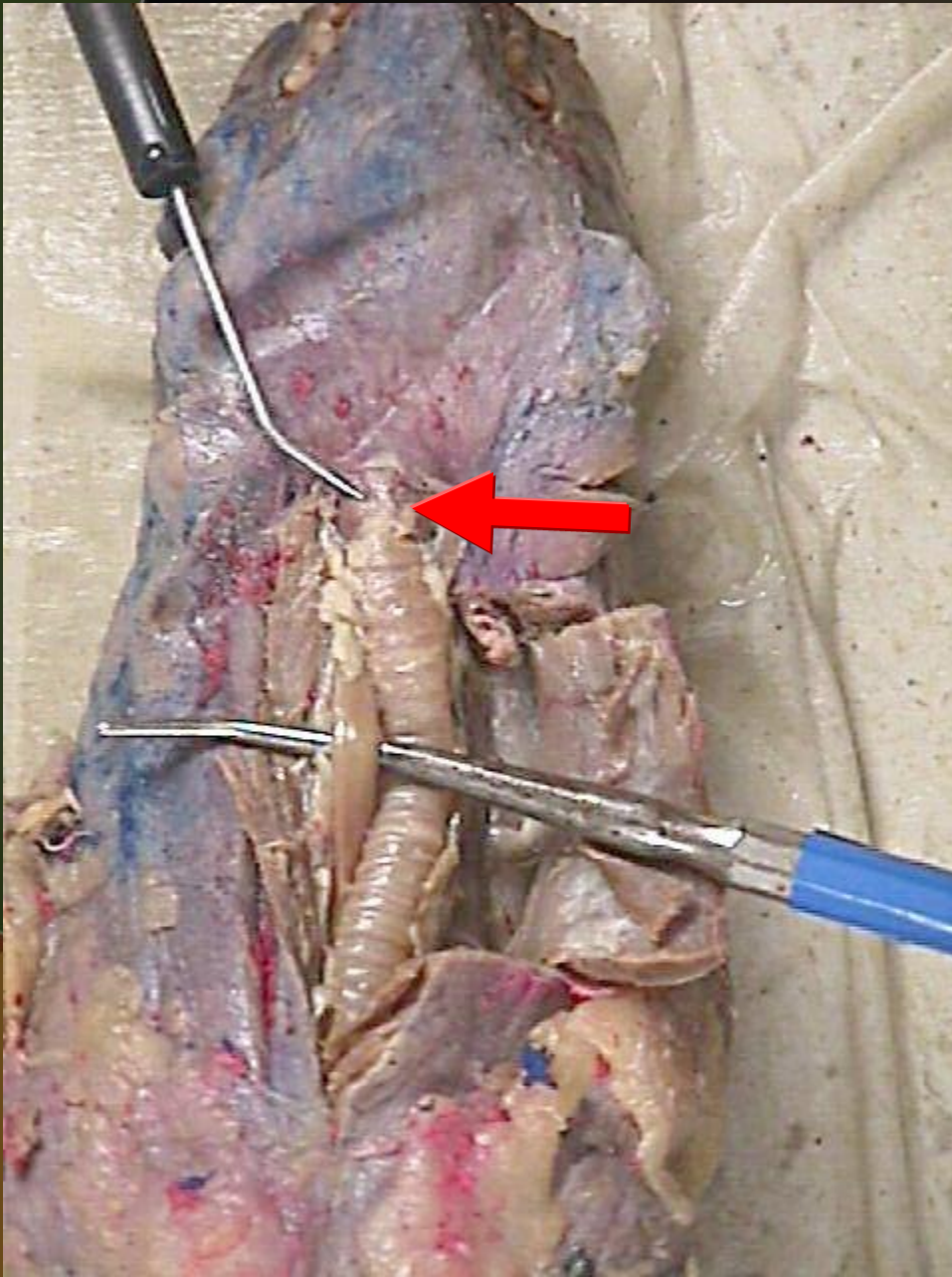
Esophagus



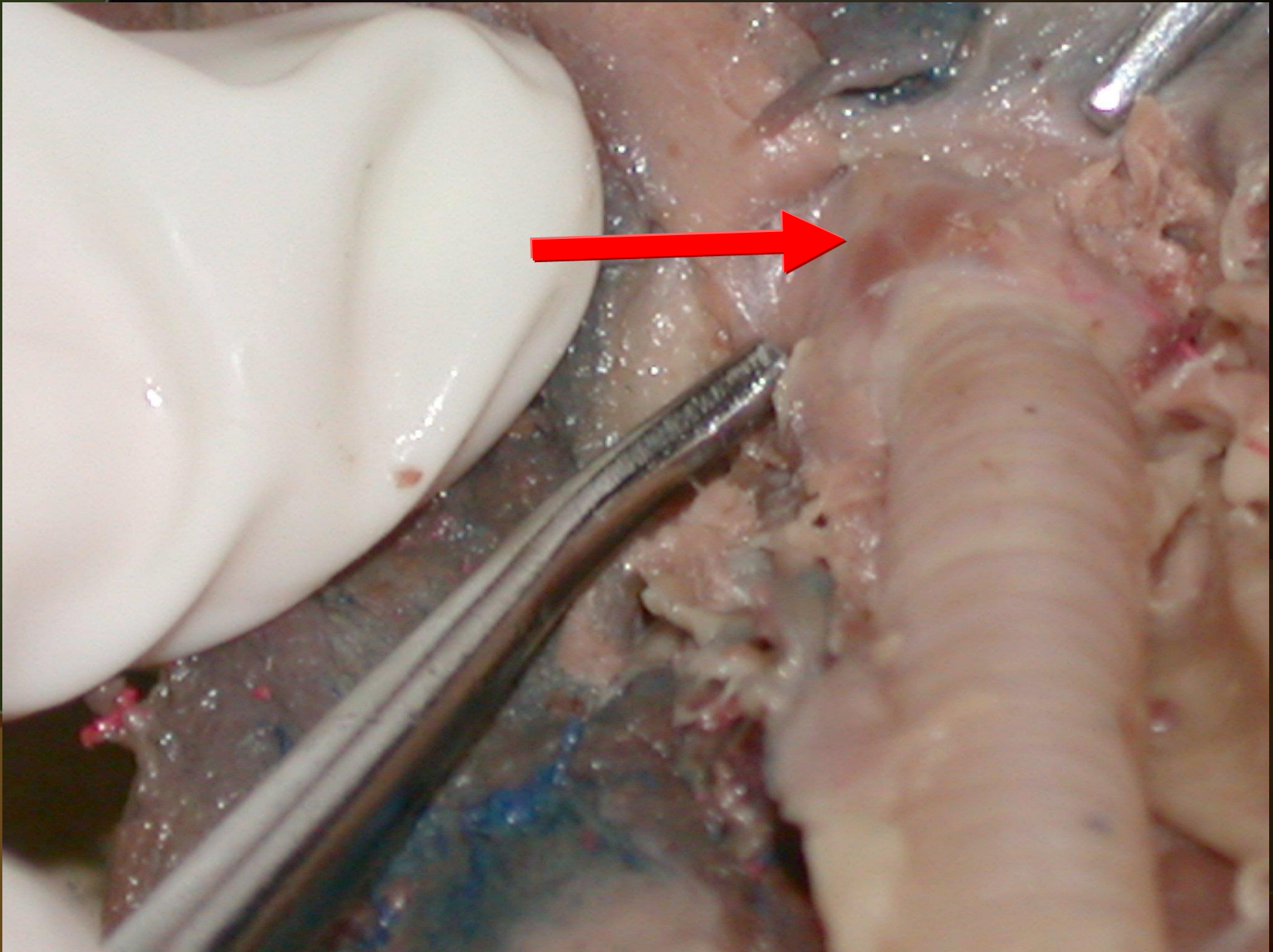
Trachea



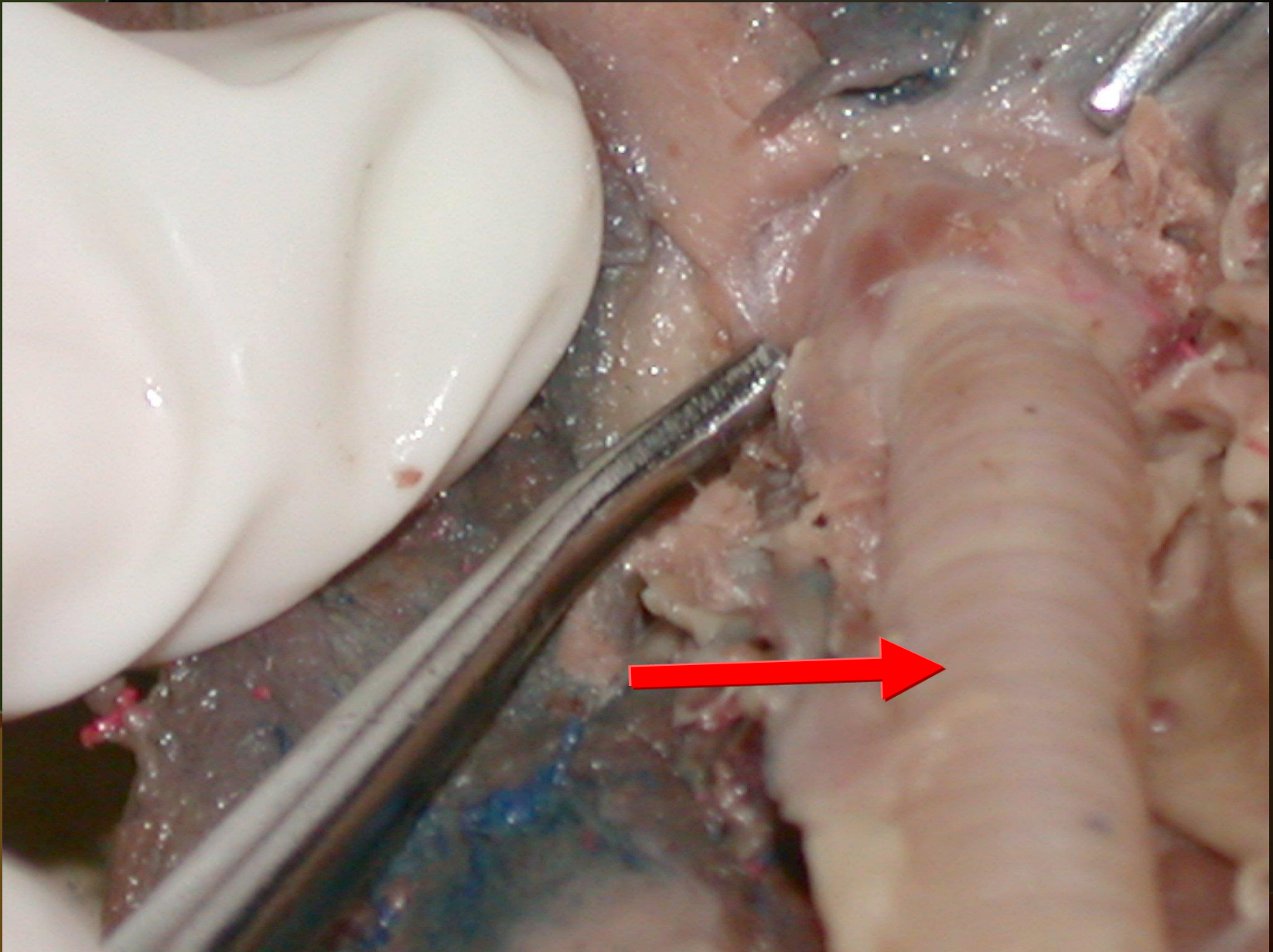
Larynx



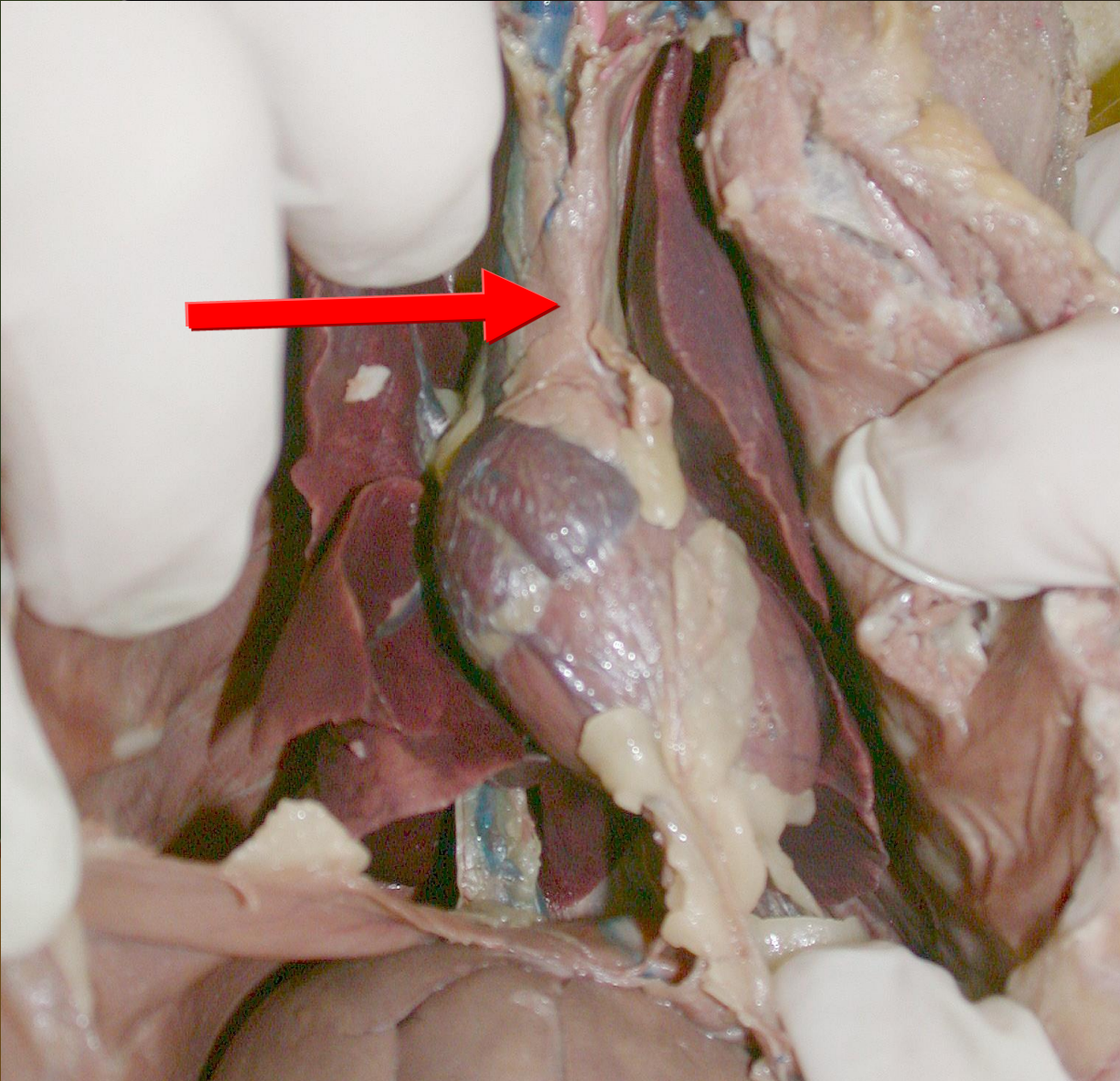
Larynx



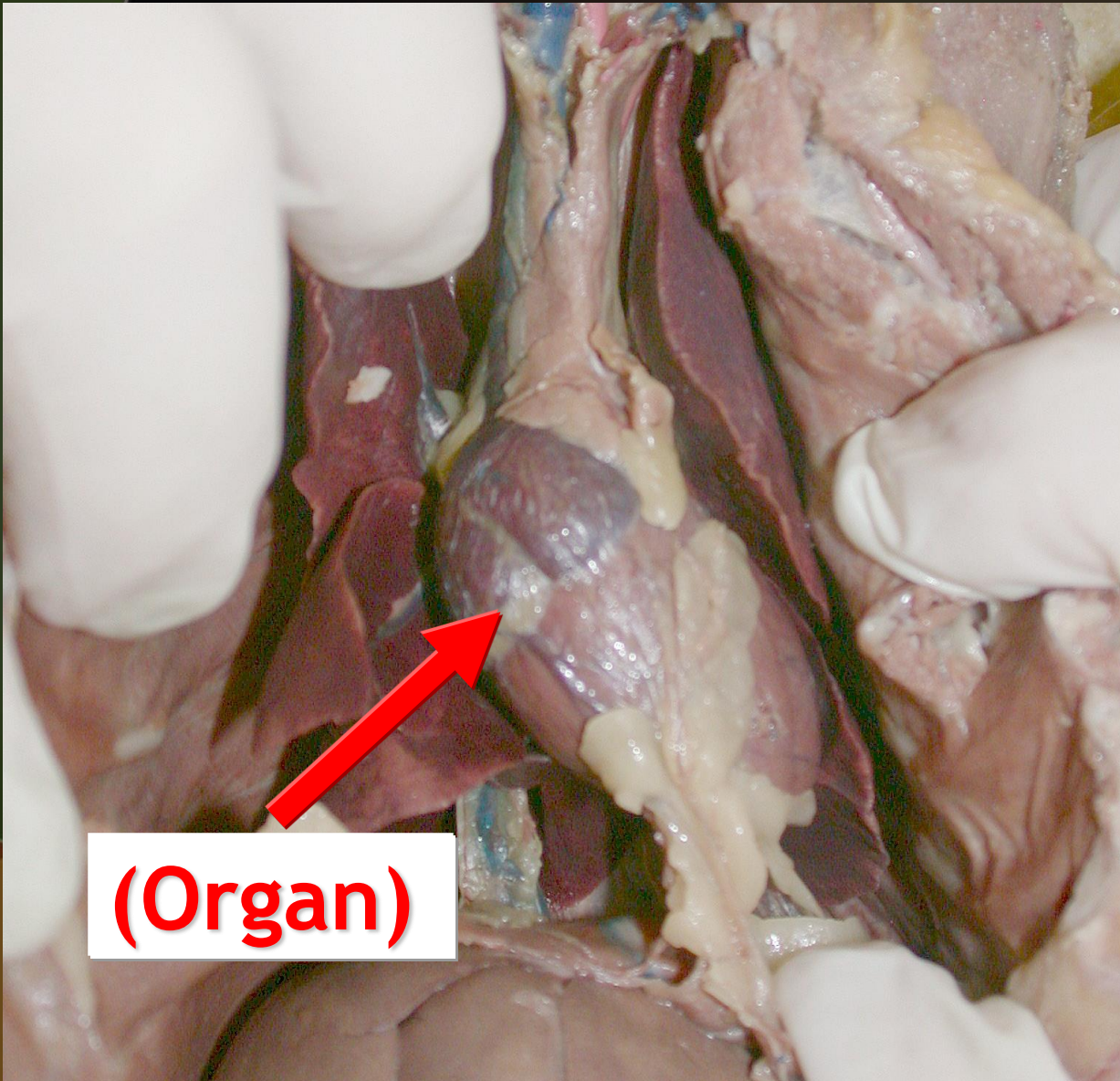
Trachea



Thymus gland

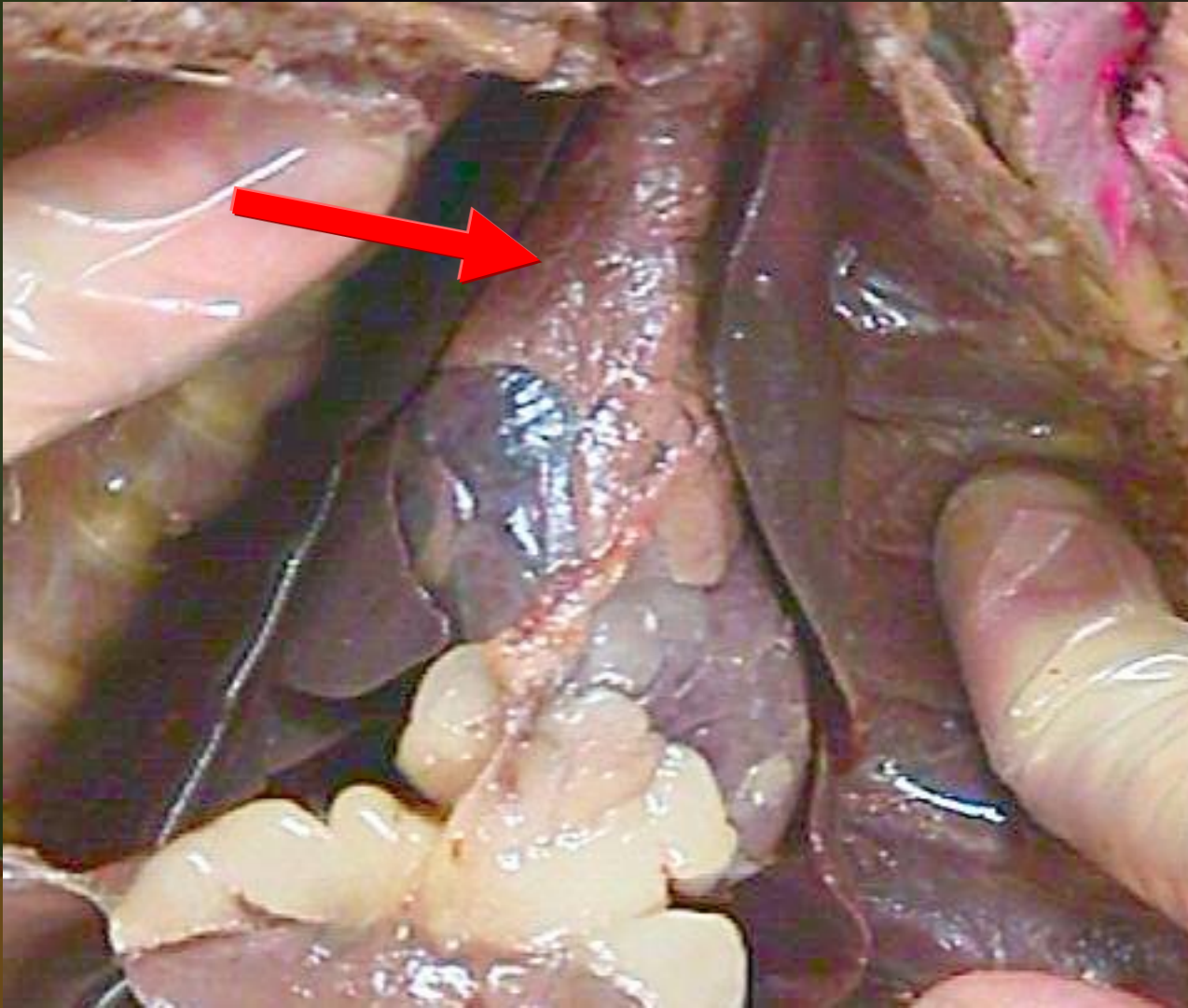


Heart

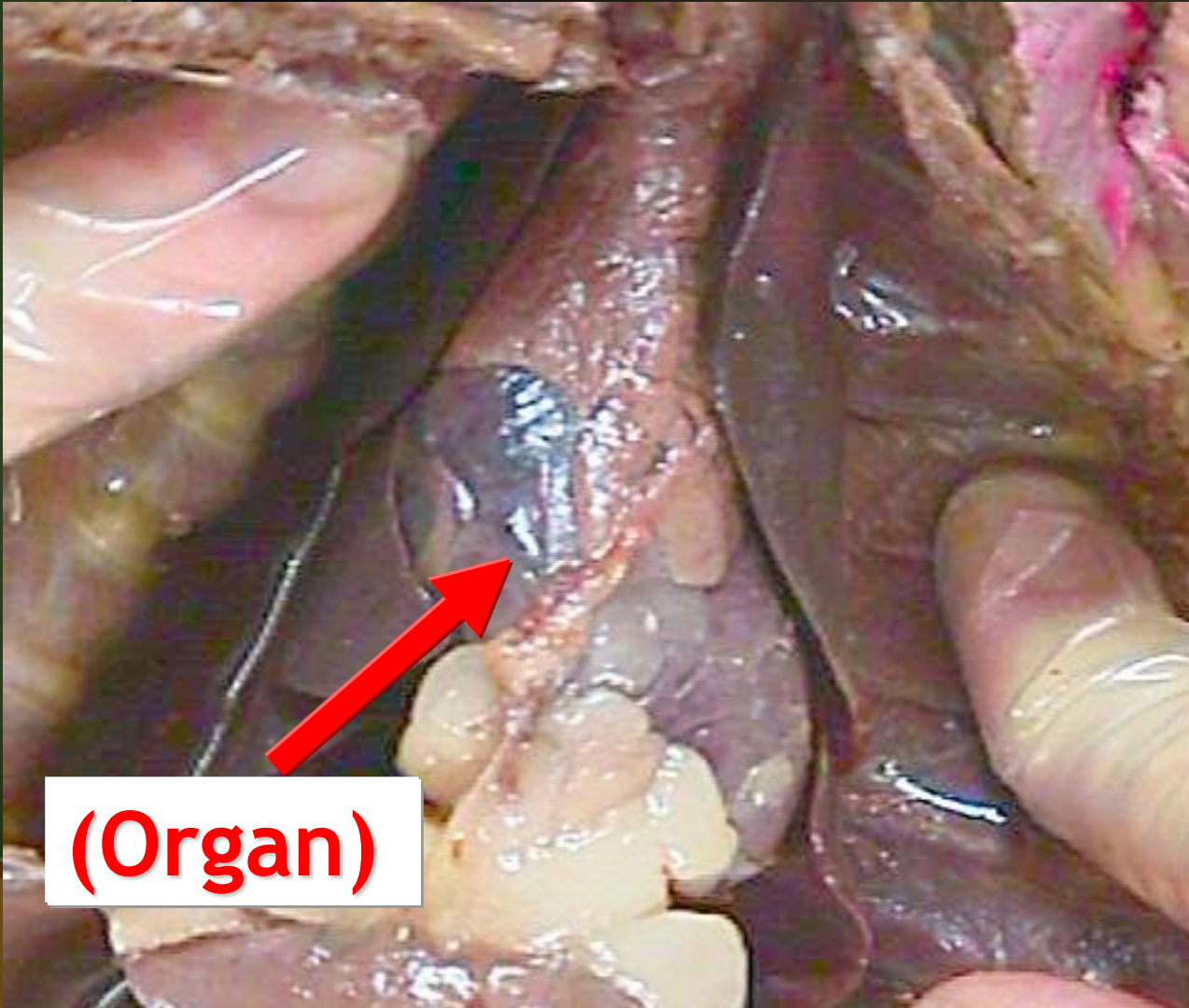


(Organ)

Thymus gland



Heart

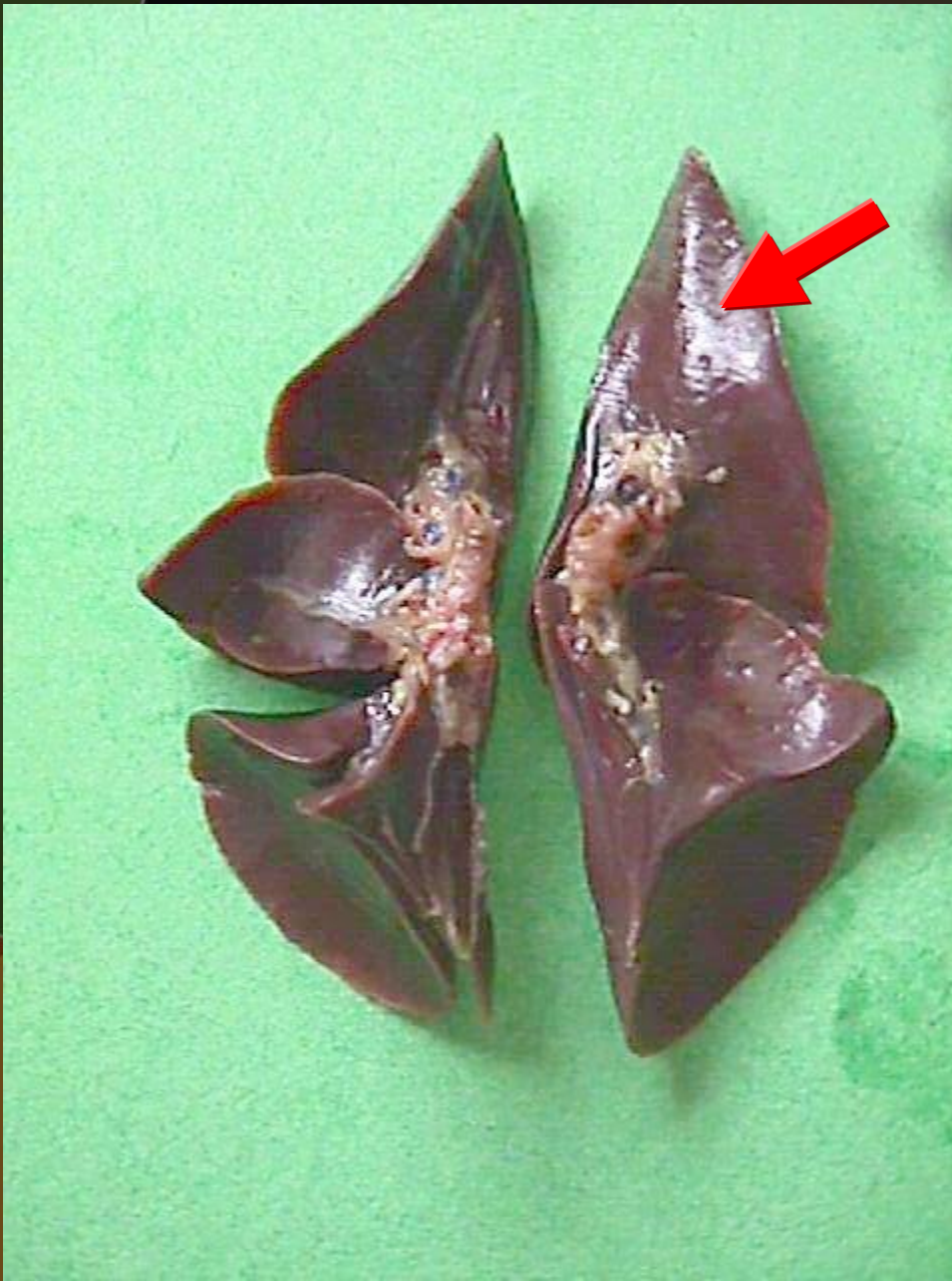

(Organ)

Right apical lobe of the lung



Left apical lobe of the lung



Right cardiac lobe of the lung



Right diaphragmatic lobe of the lung



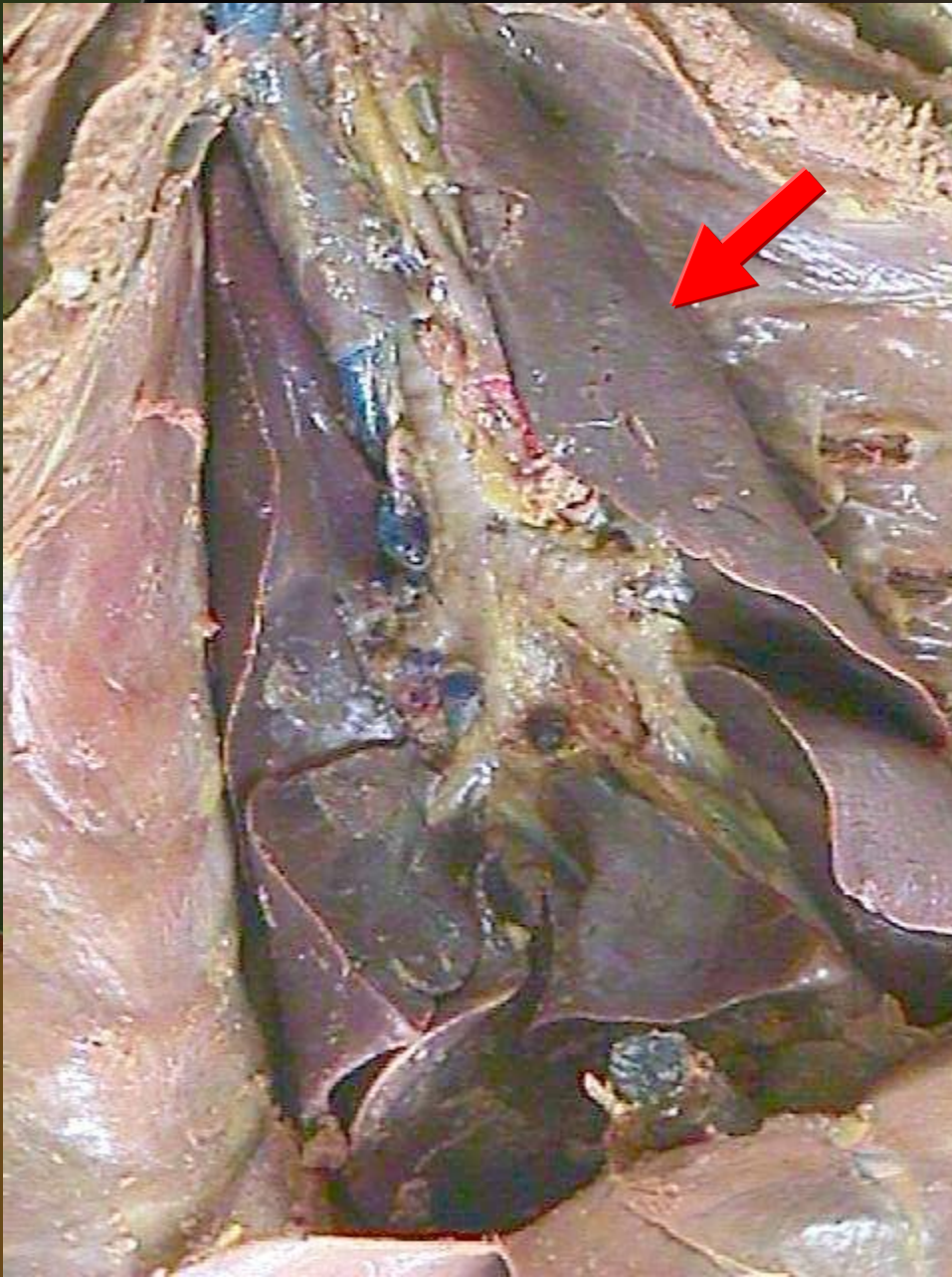
Left diaphragmatic lobe of the lung



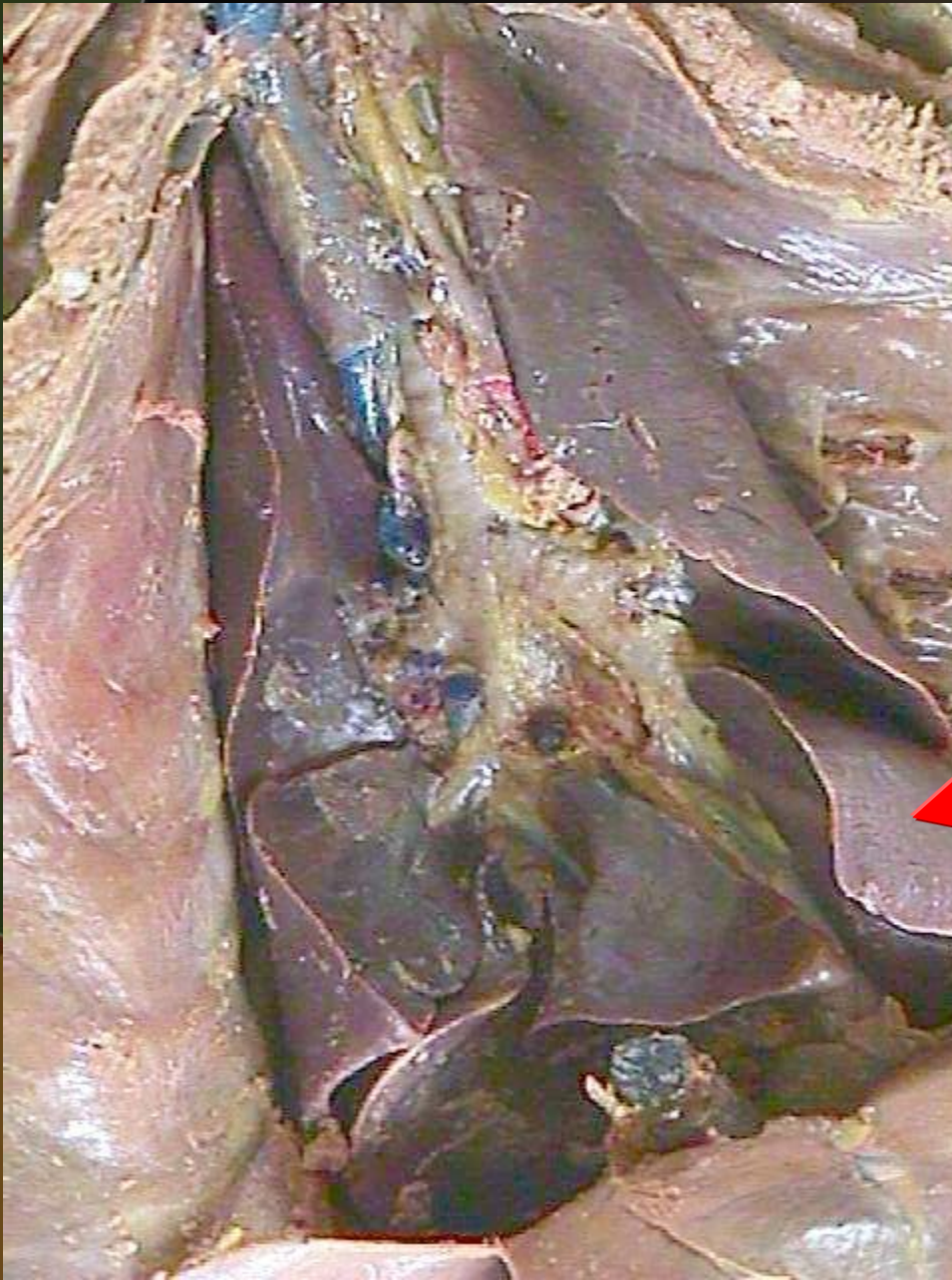
Intermediate lobe of the lung



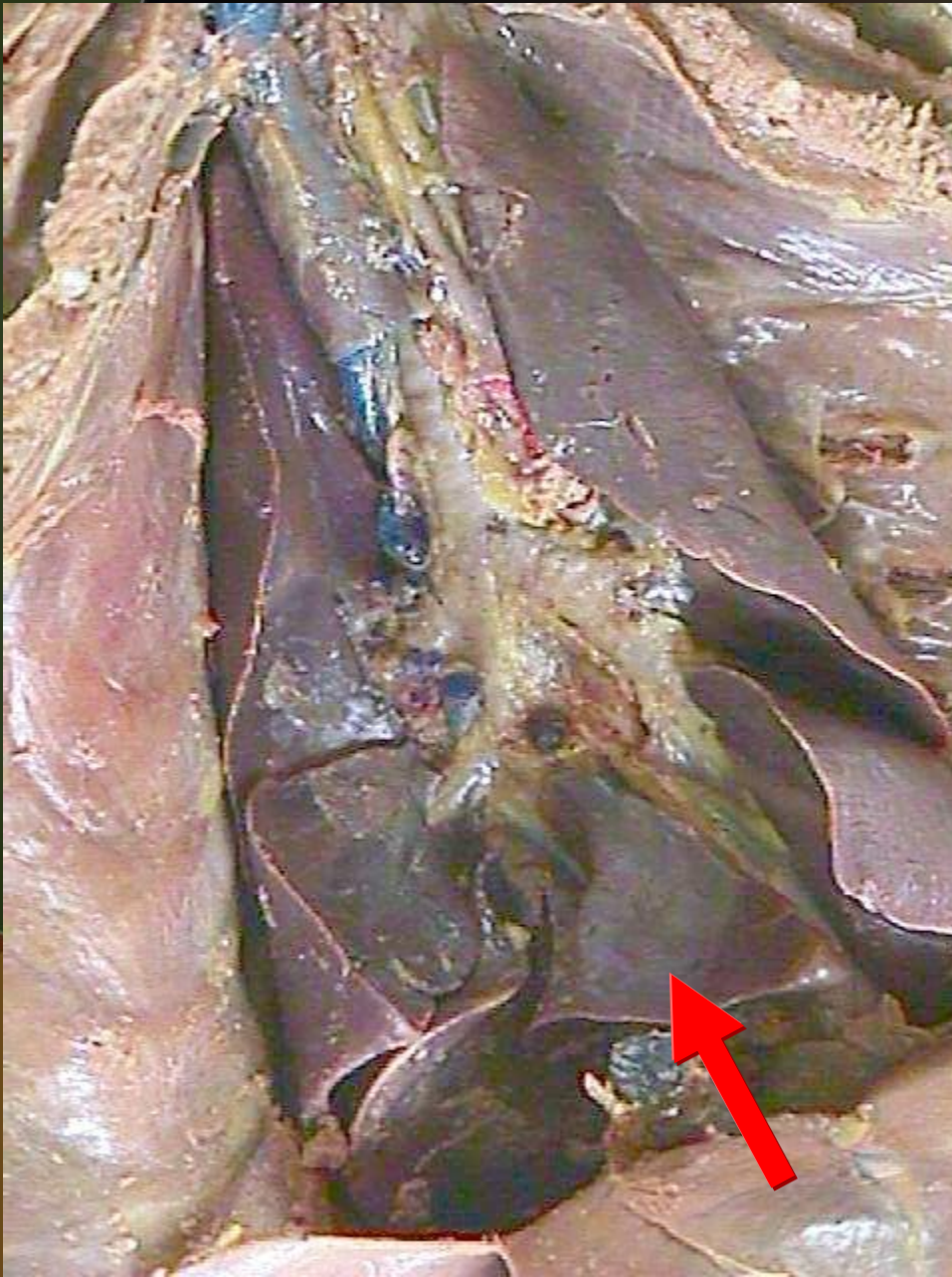
Left apical lobe of the lung



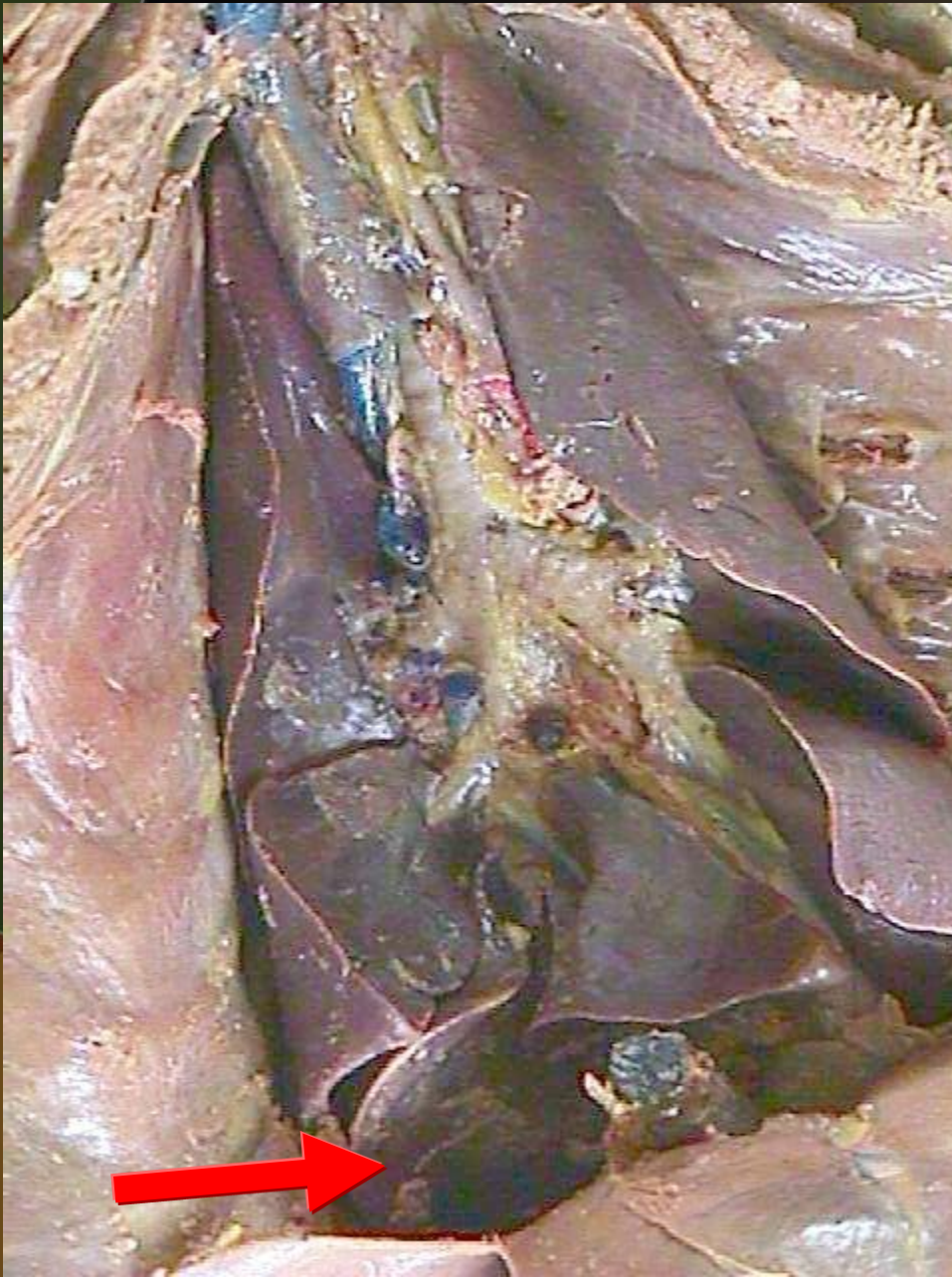
Left diaphragmatic lobe of the lung



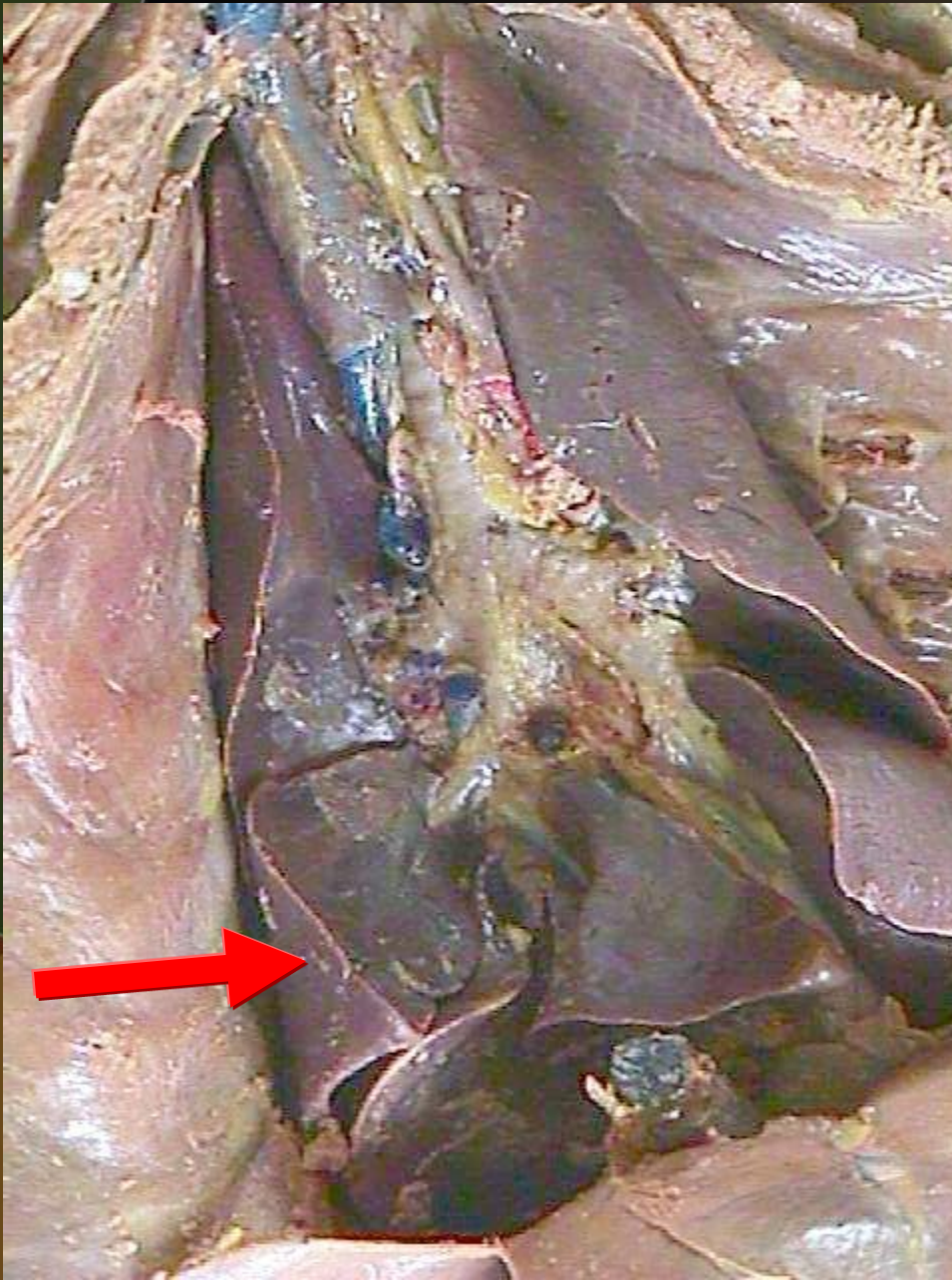
Intermediate lobe of the lung



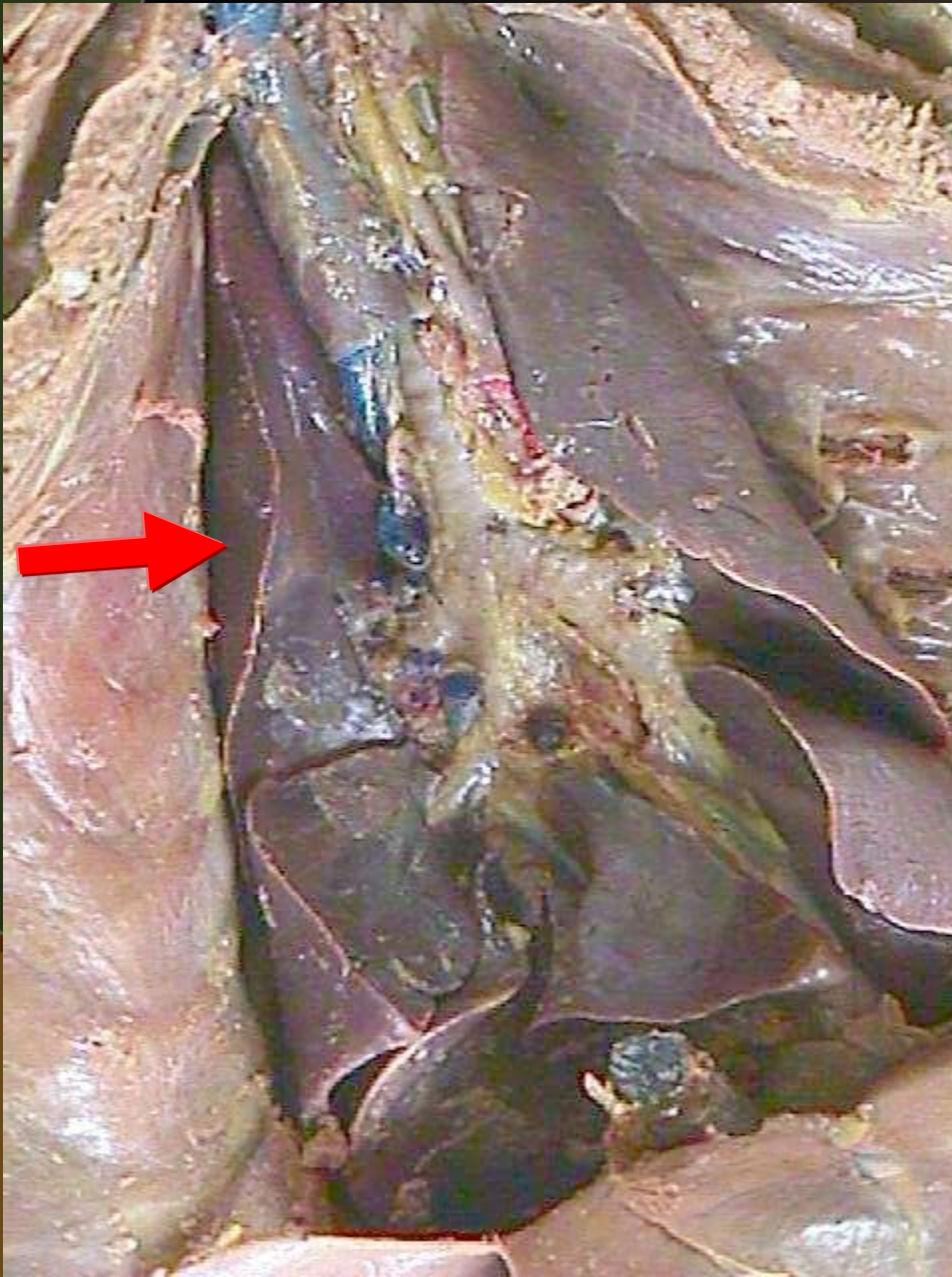
Right diaphragmatic lobe of the lung



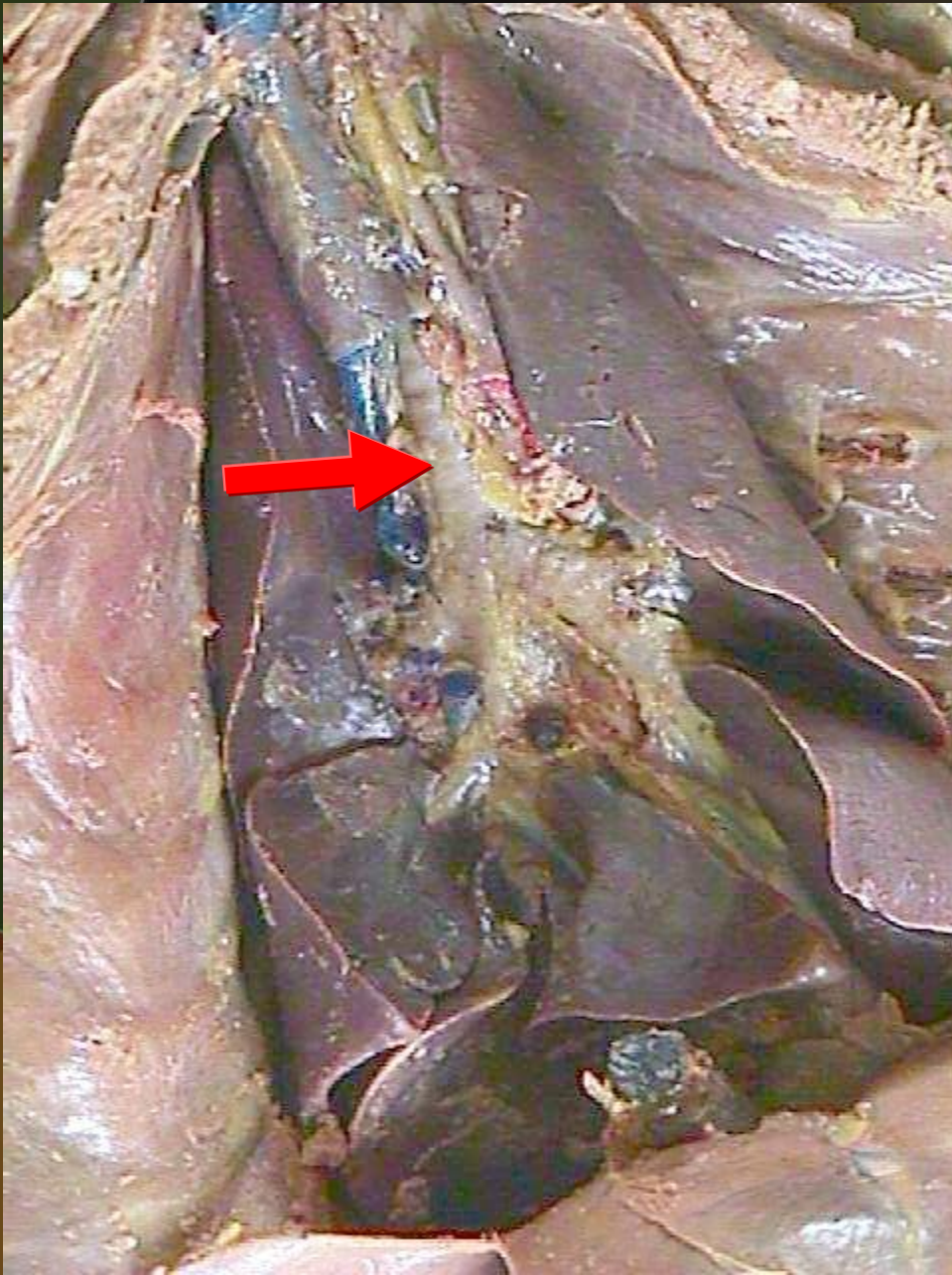
Right cardiac lobe of the lung



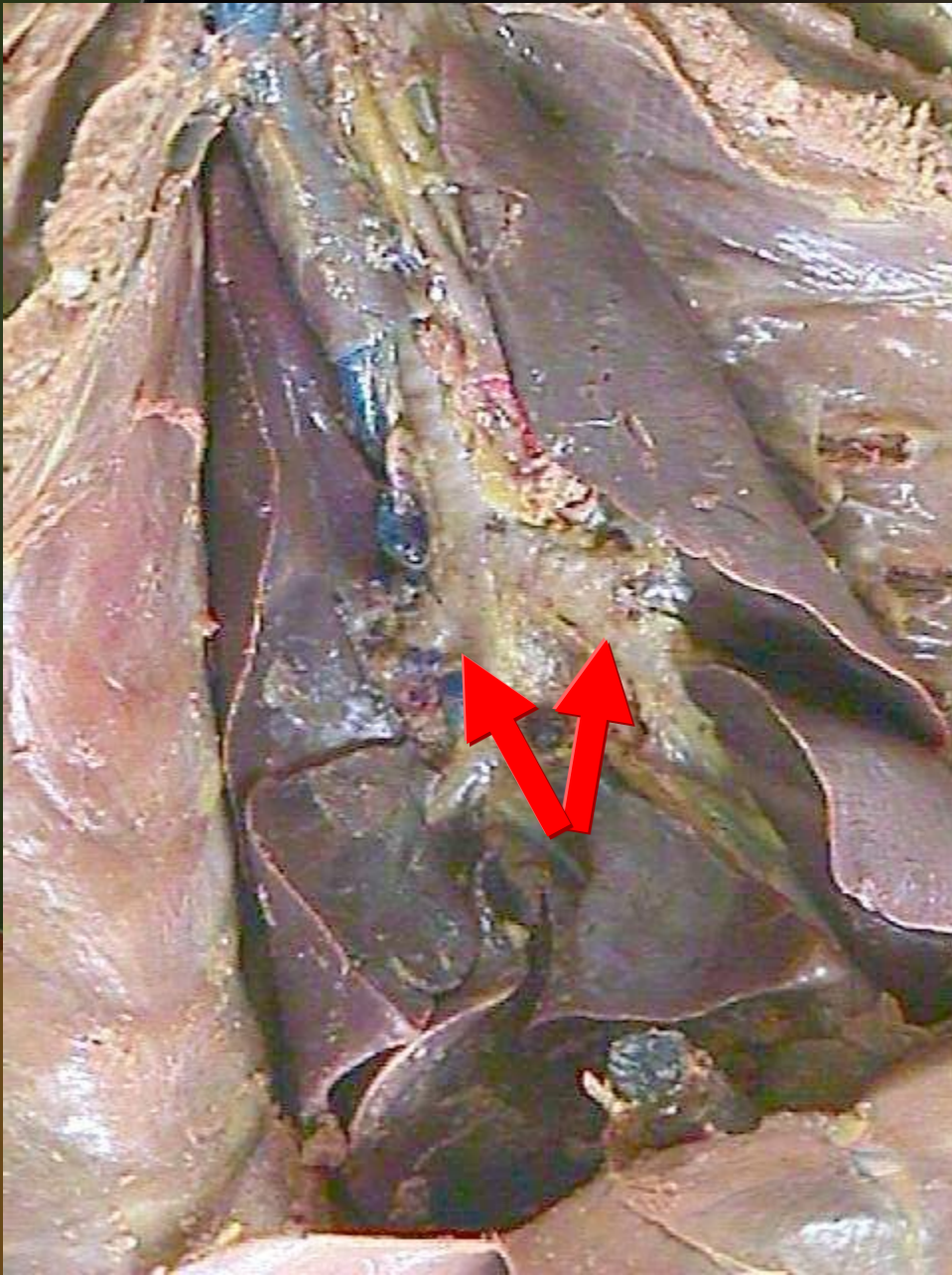
Right apical lobe of the lung



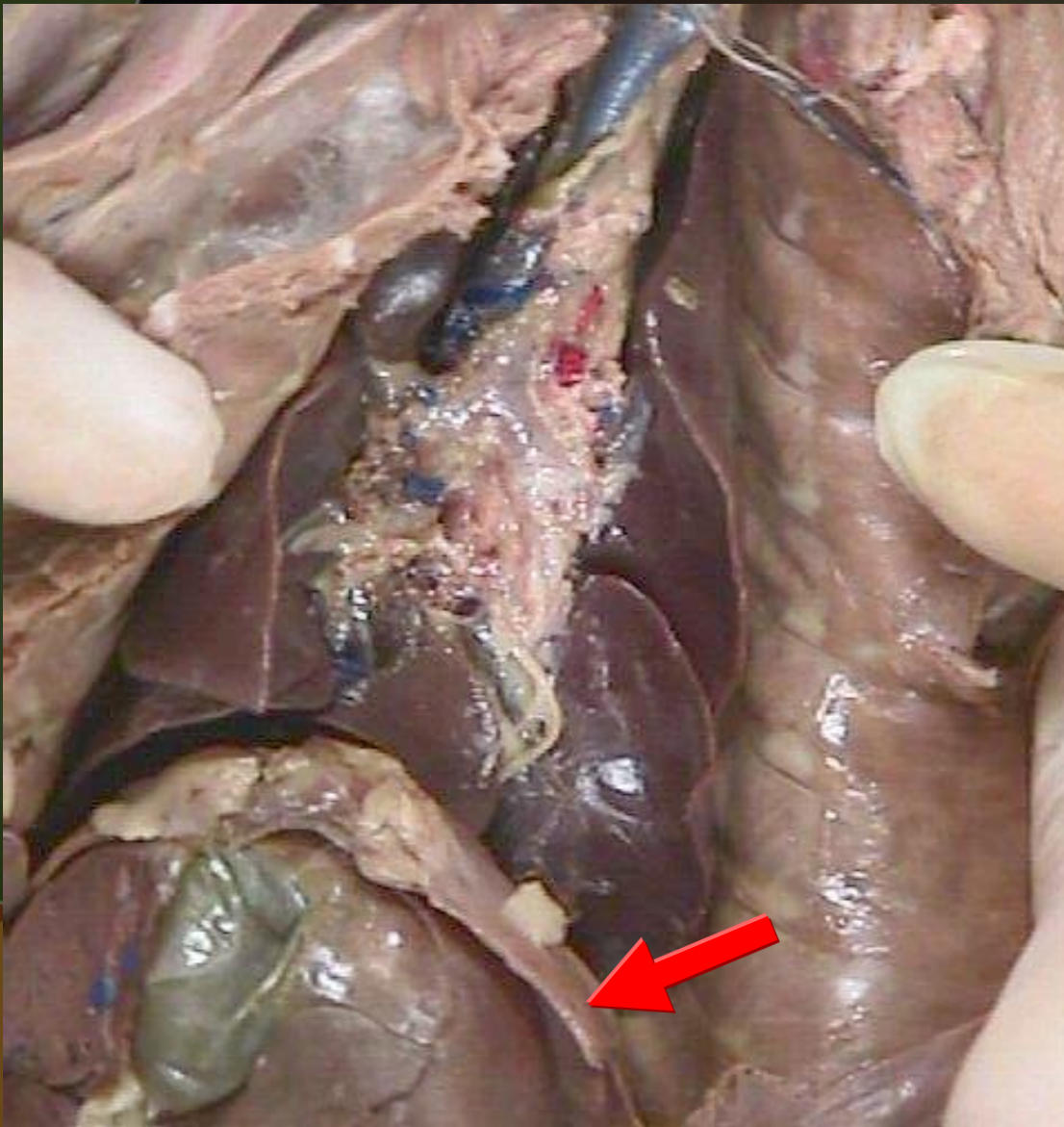
Trachea



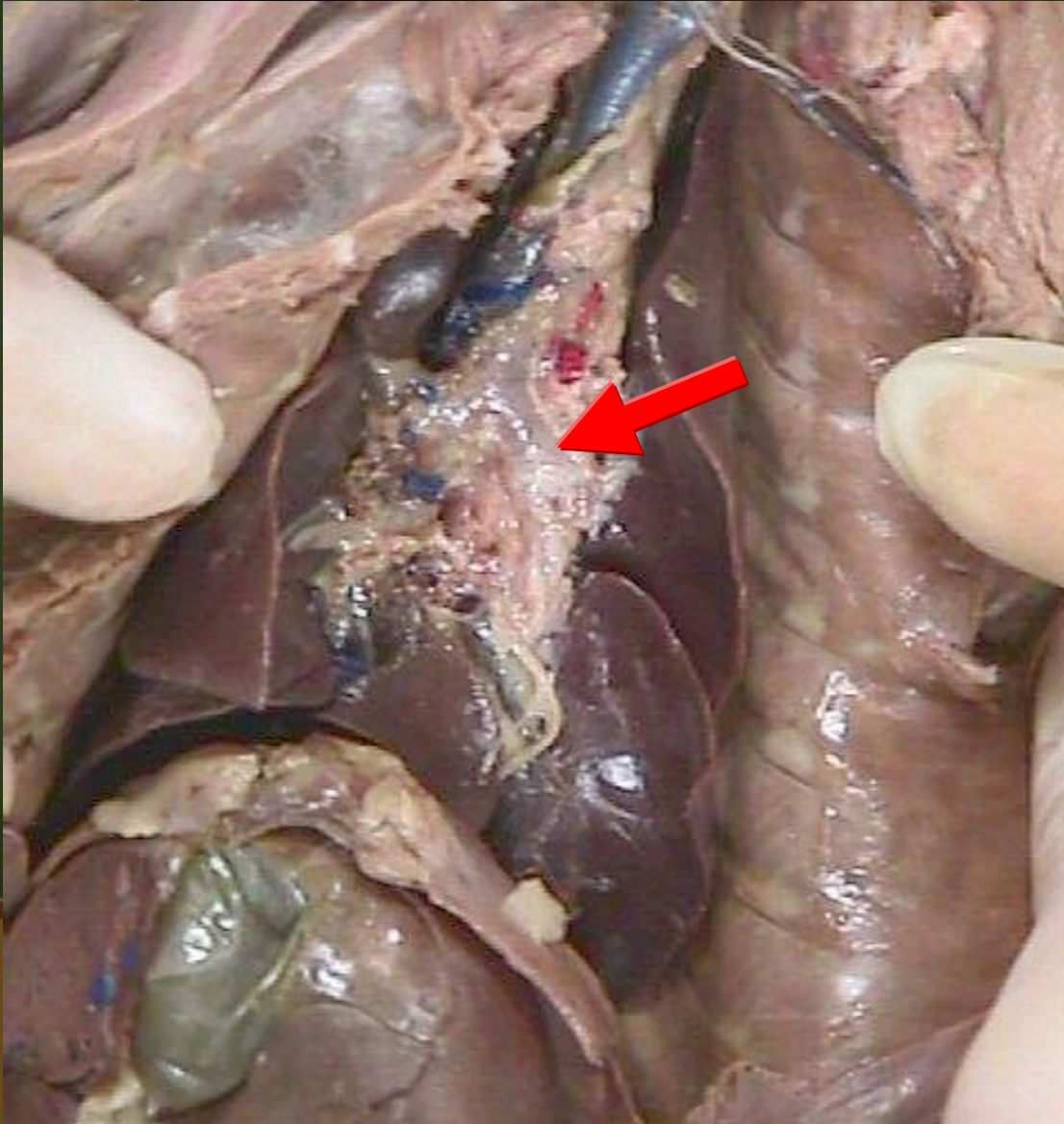
Bronchi



Diaphragm



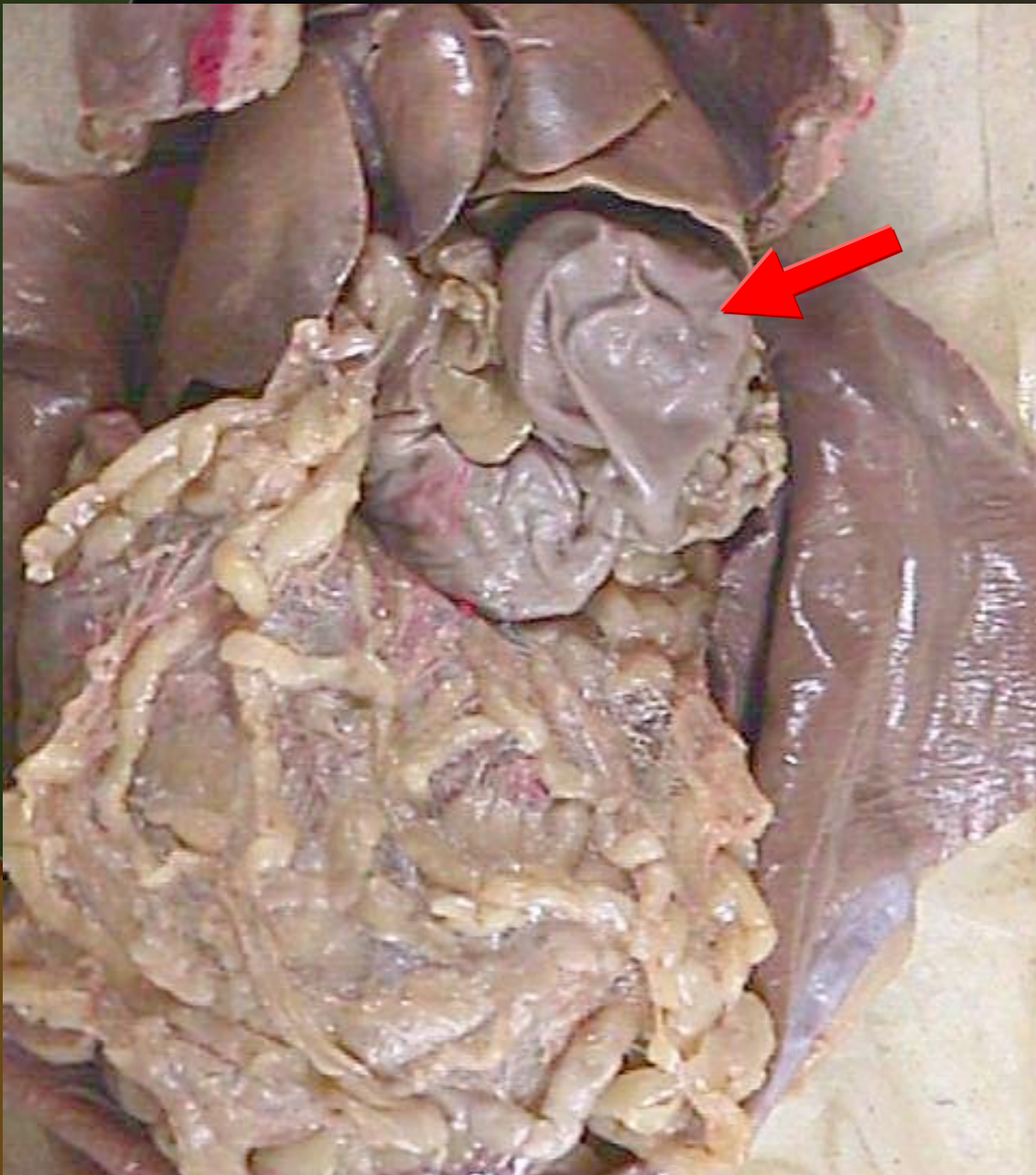
Bronchi



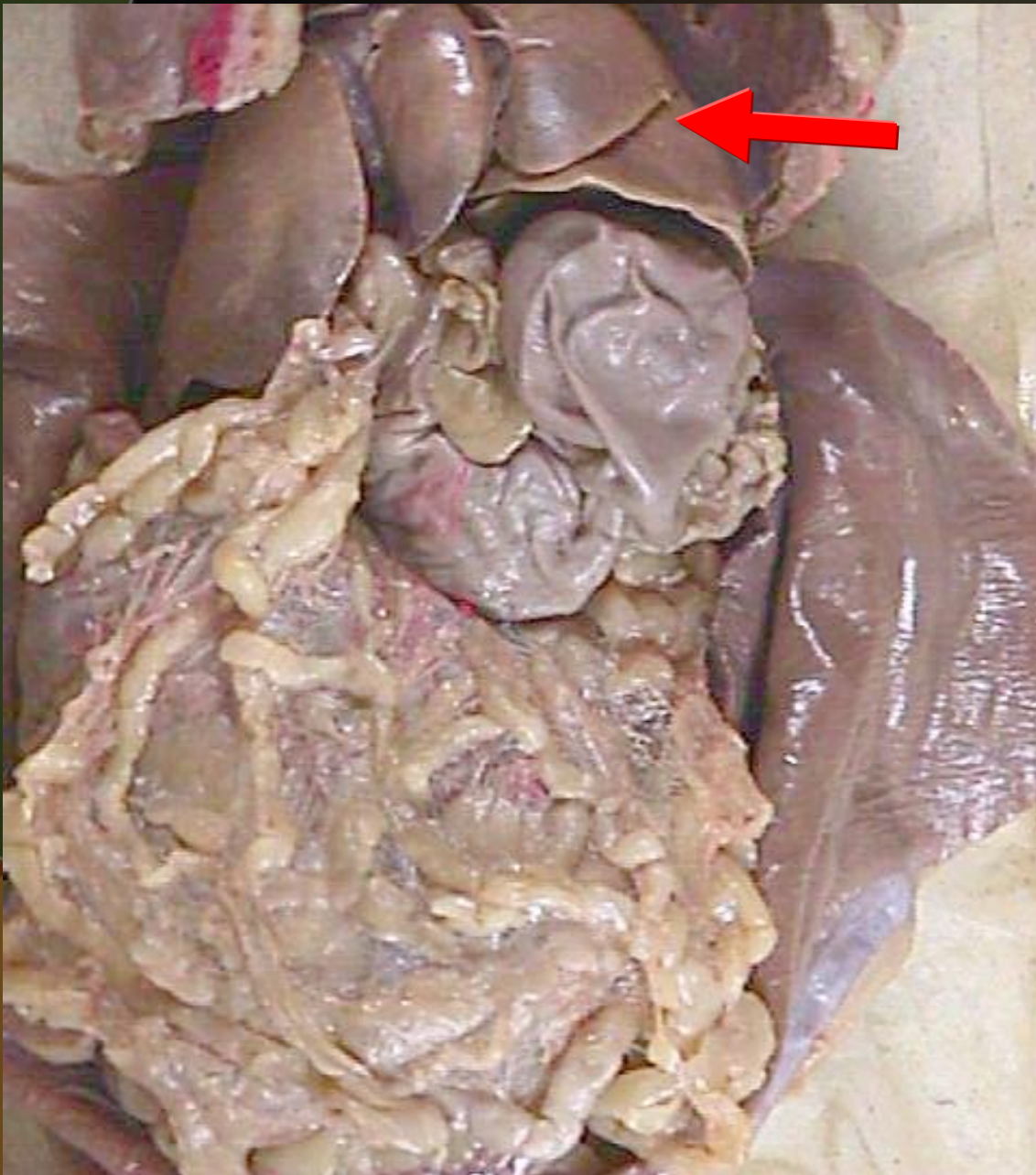
Abdominal Cavity



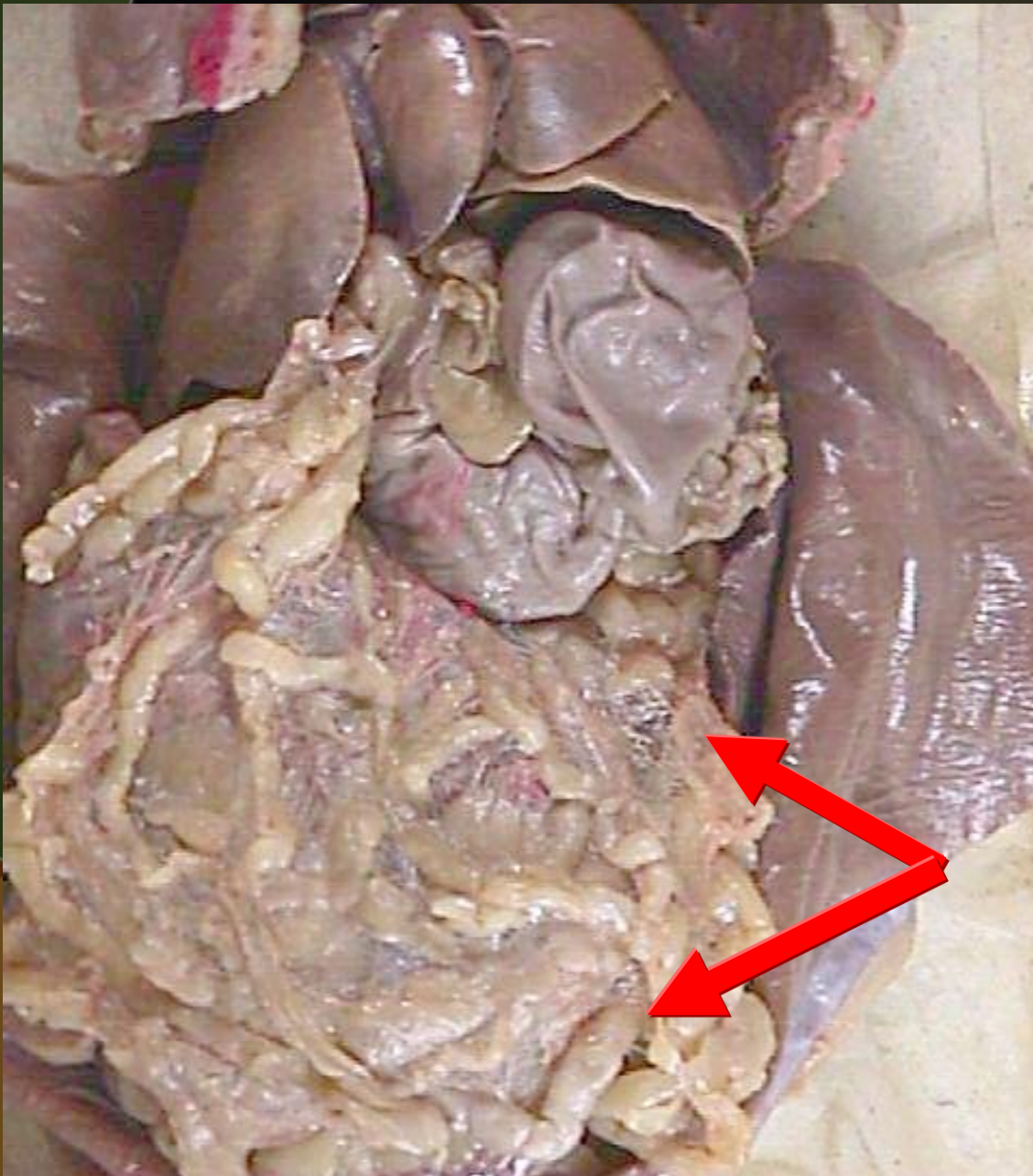
Stomach



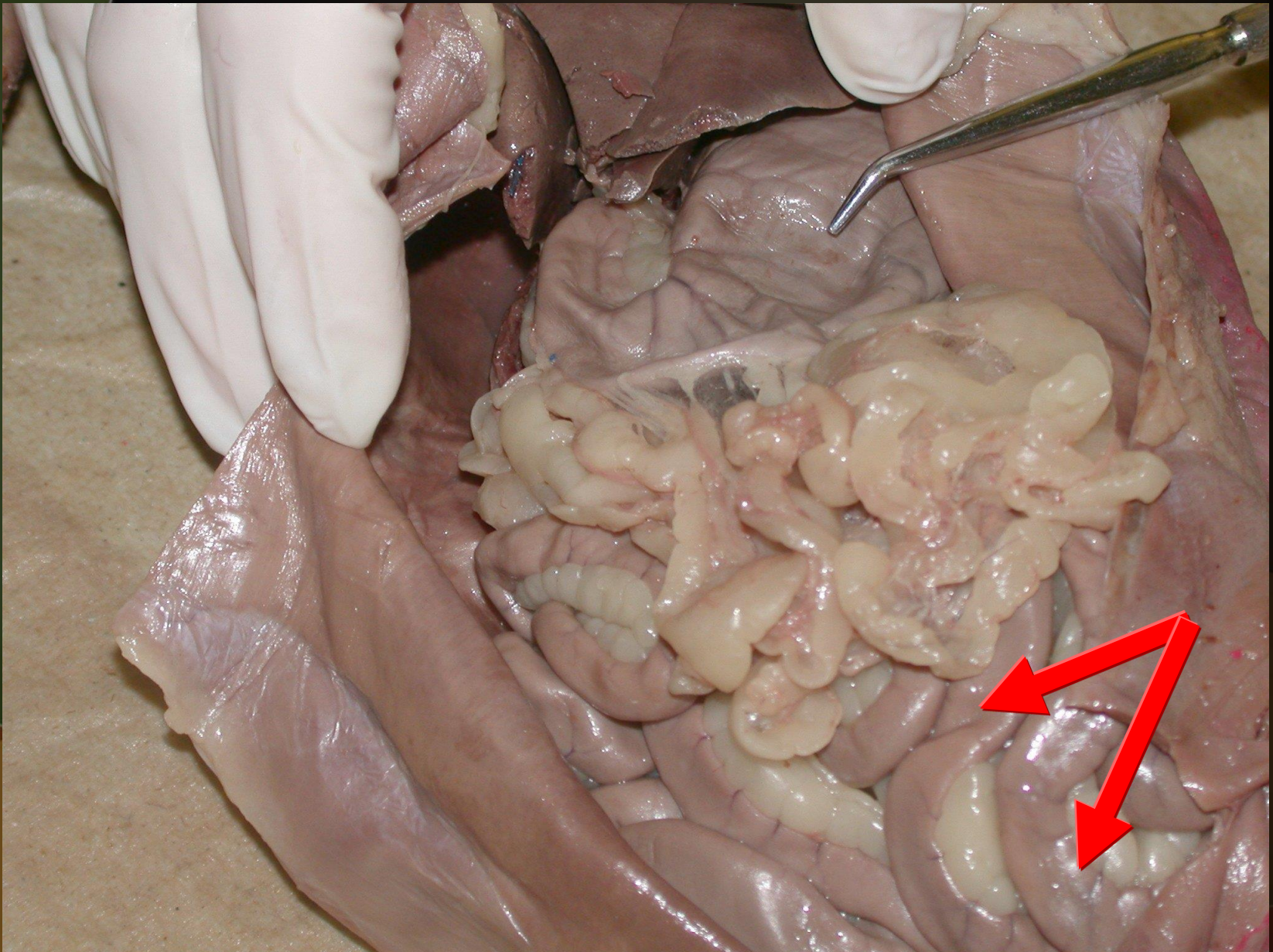
Liver



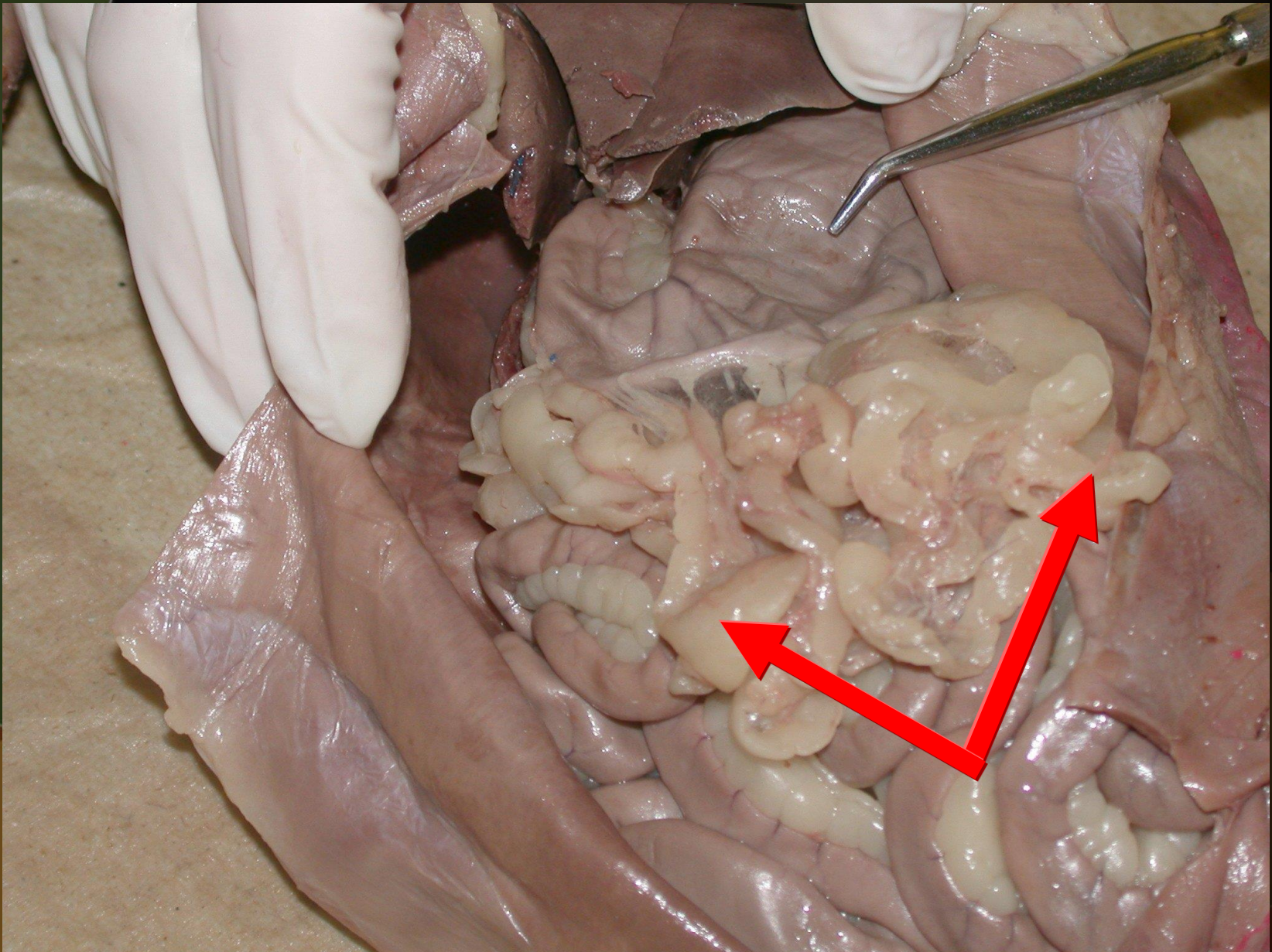
Greater omentum



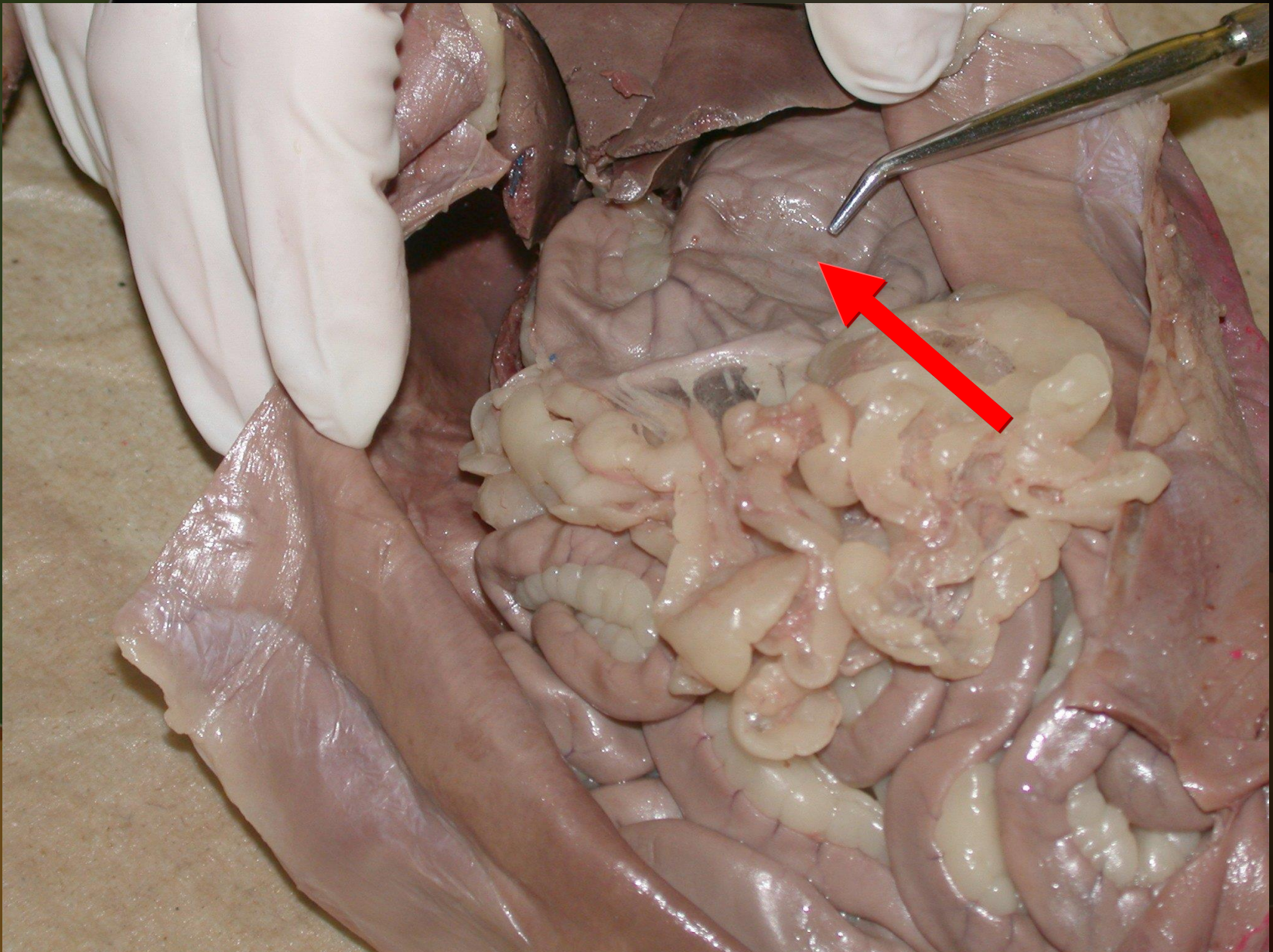
Intestines



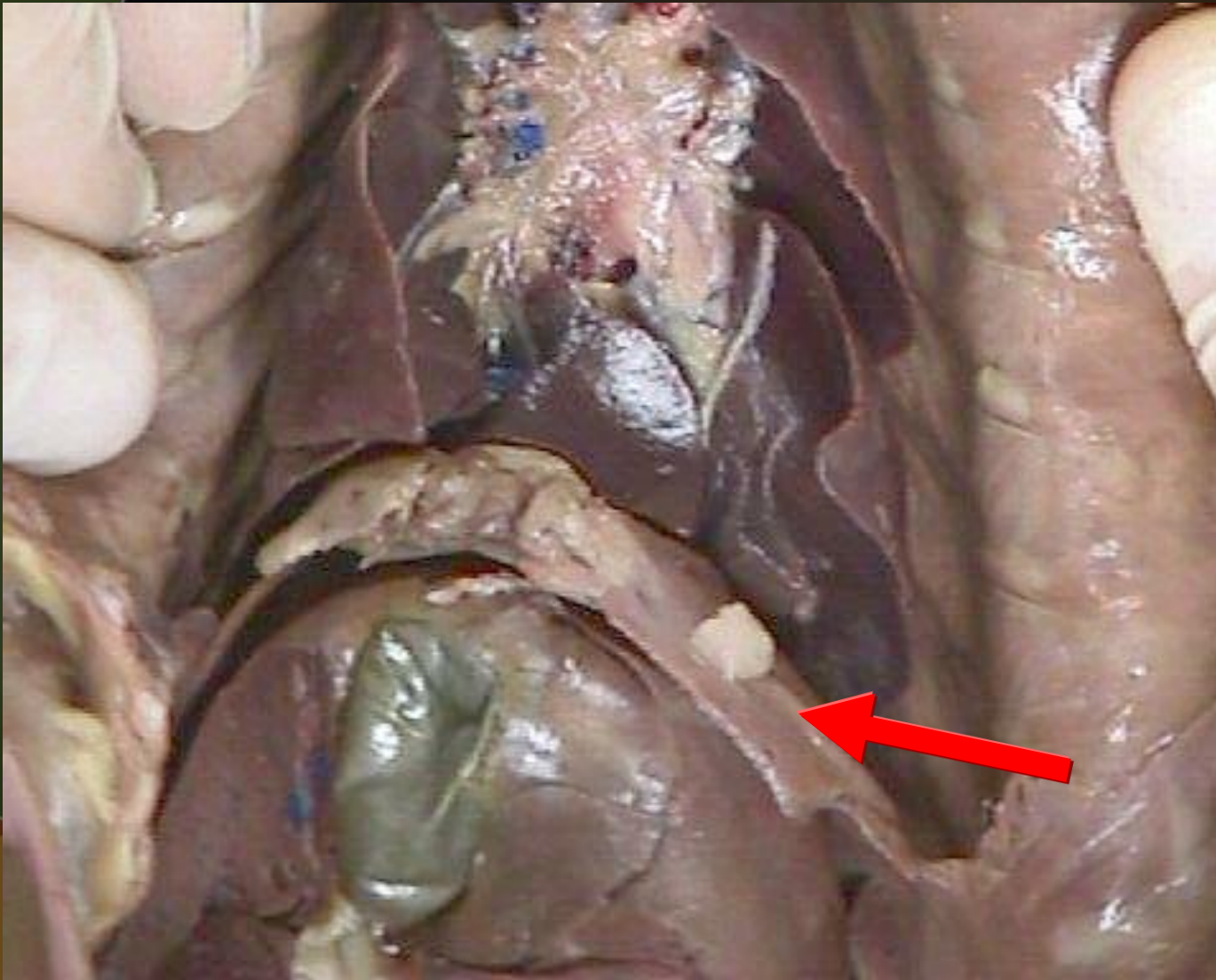
Greater omentum



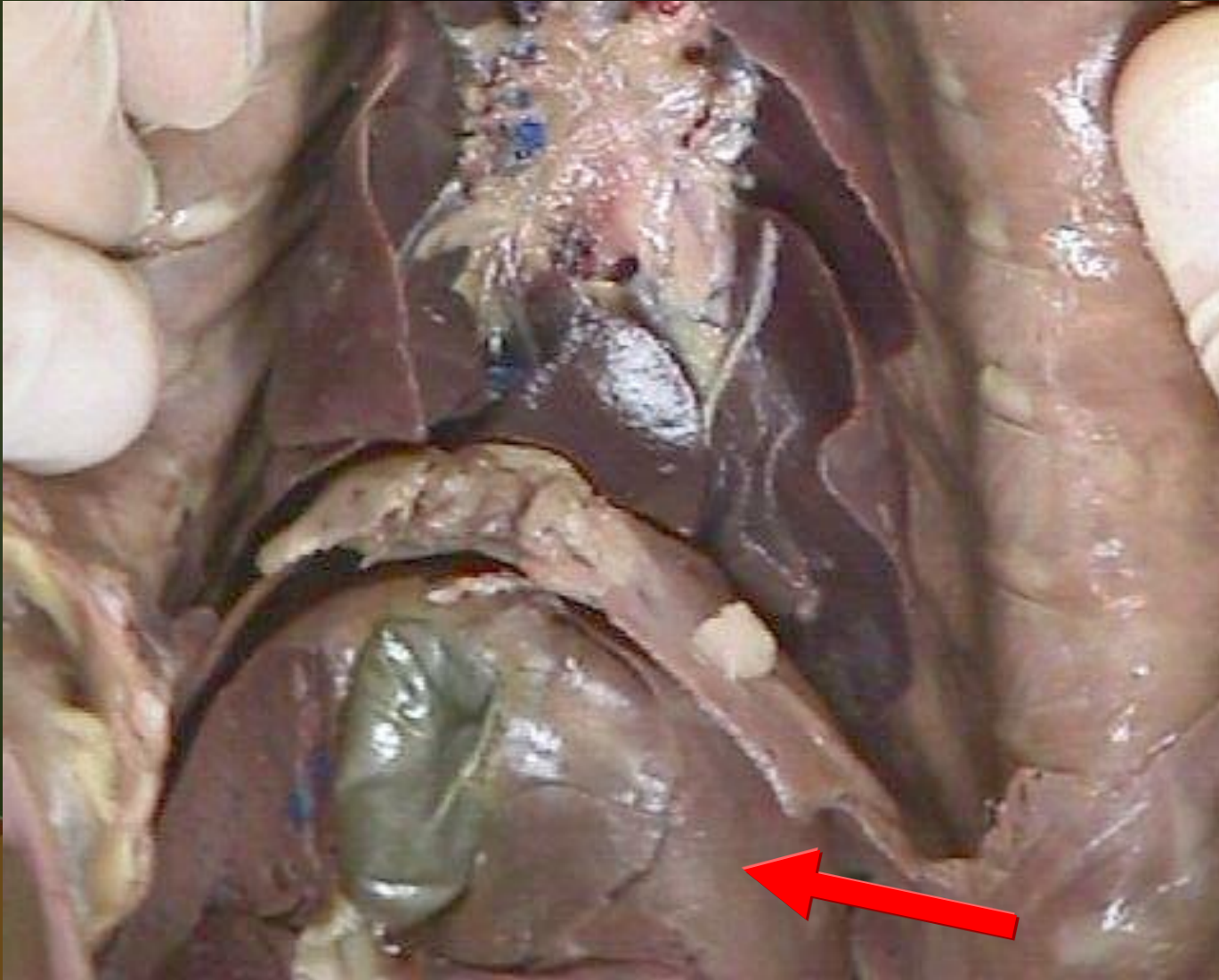
Stomach



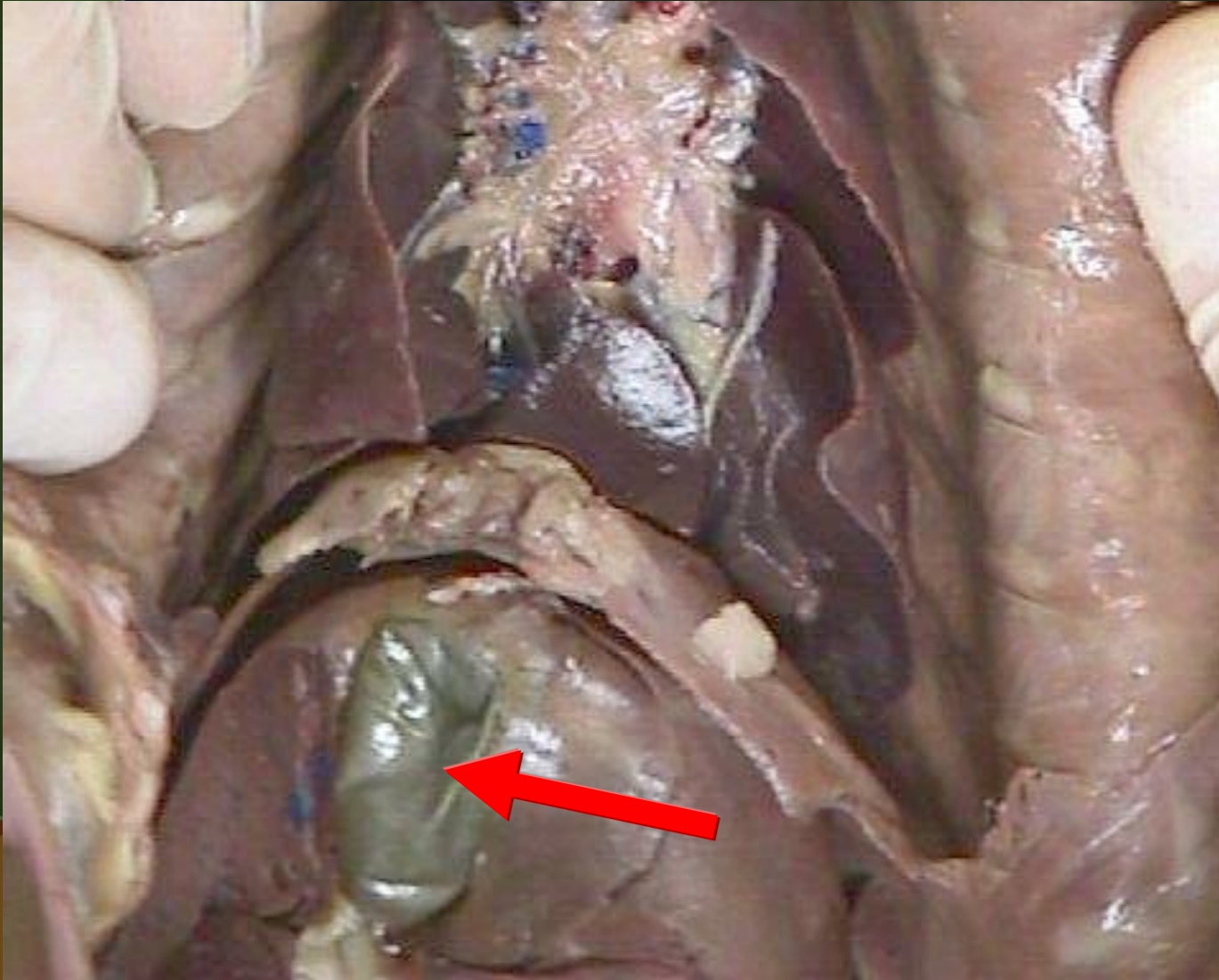
Diaphragm



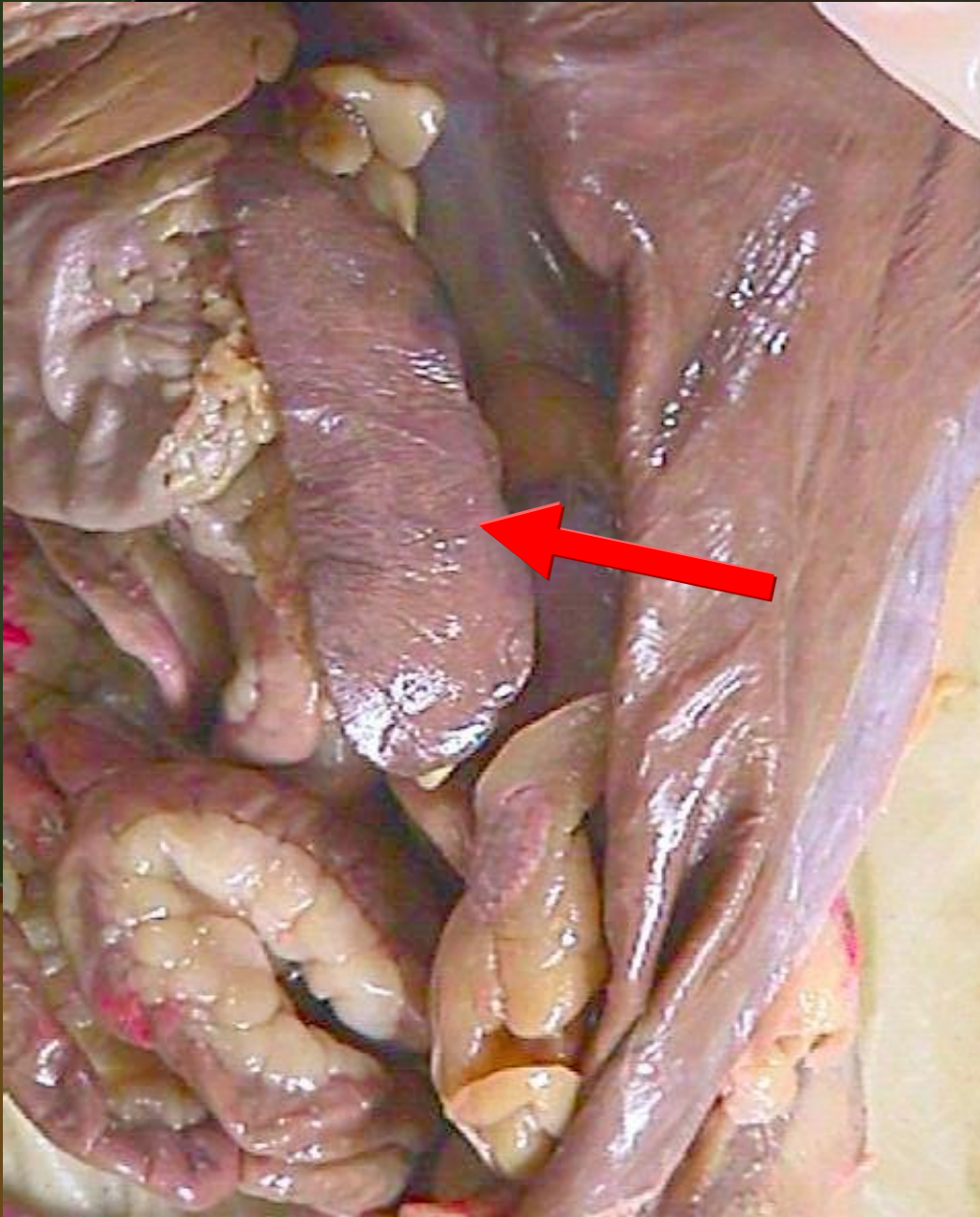
Liver



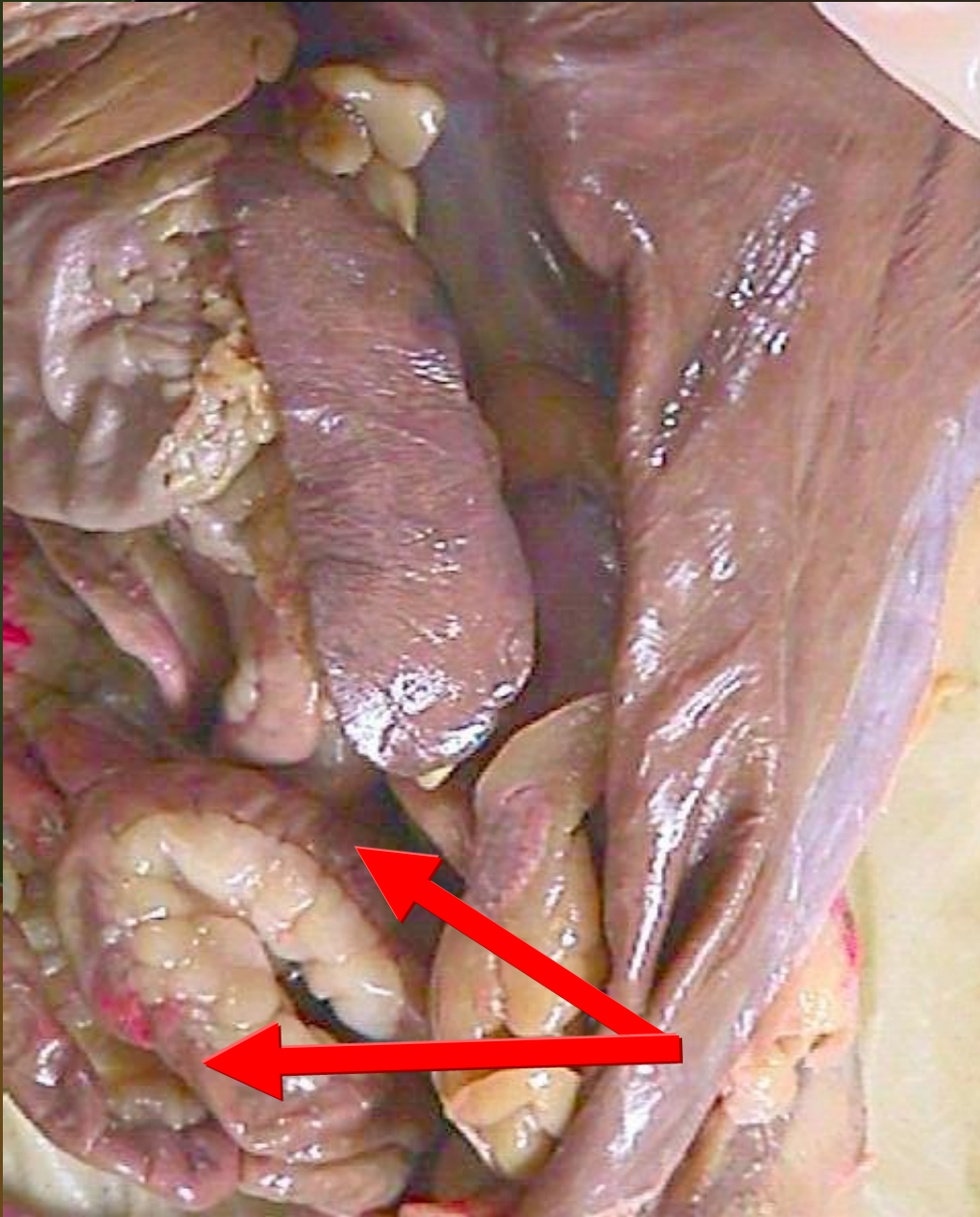
Gall bladder



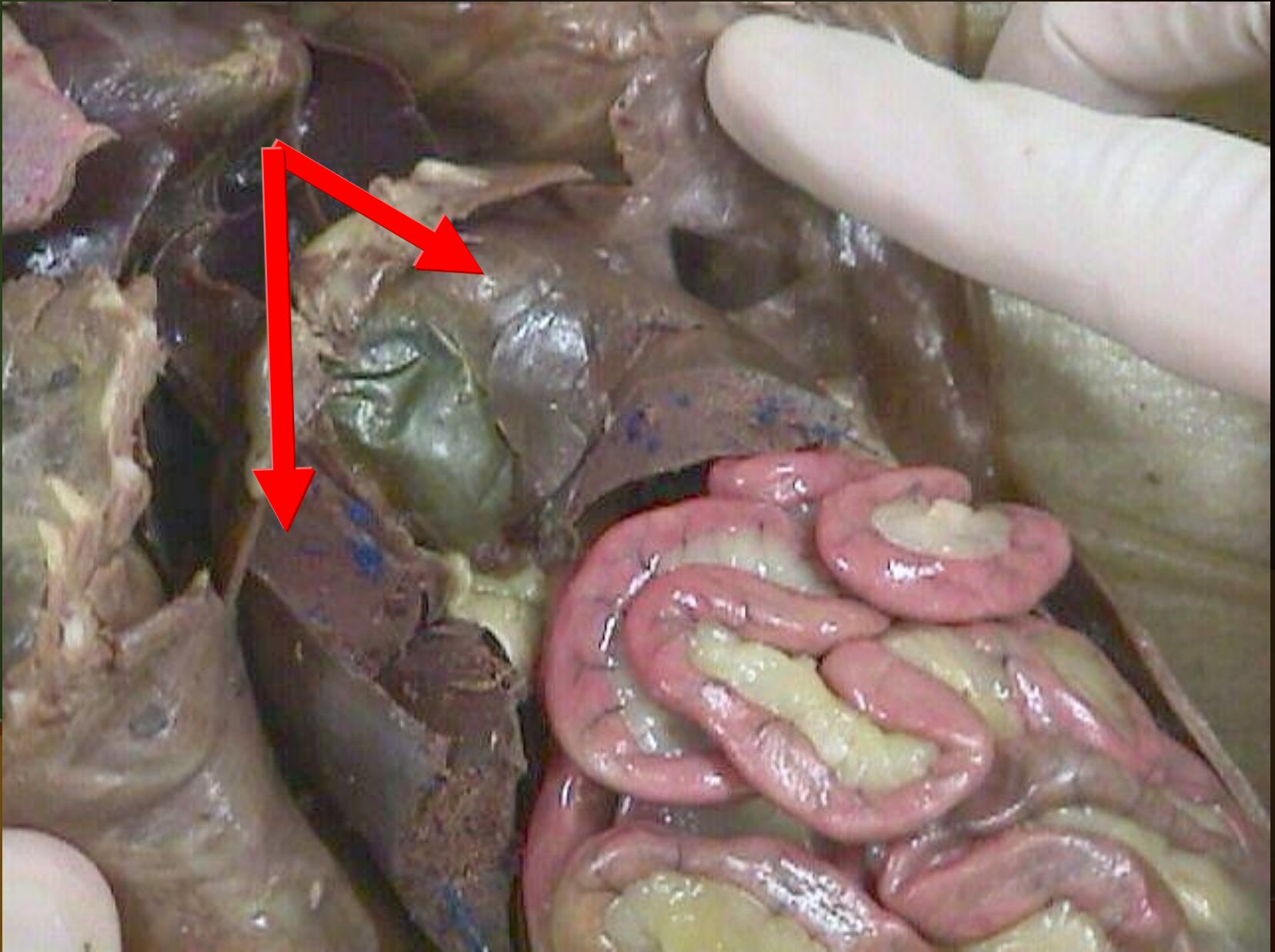
Spleen



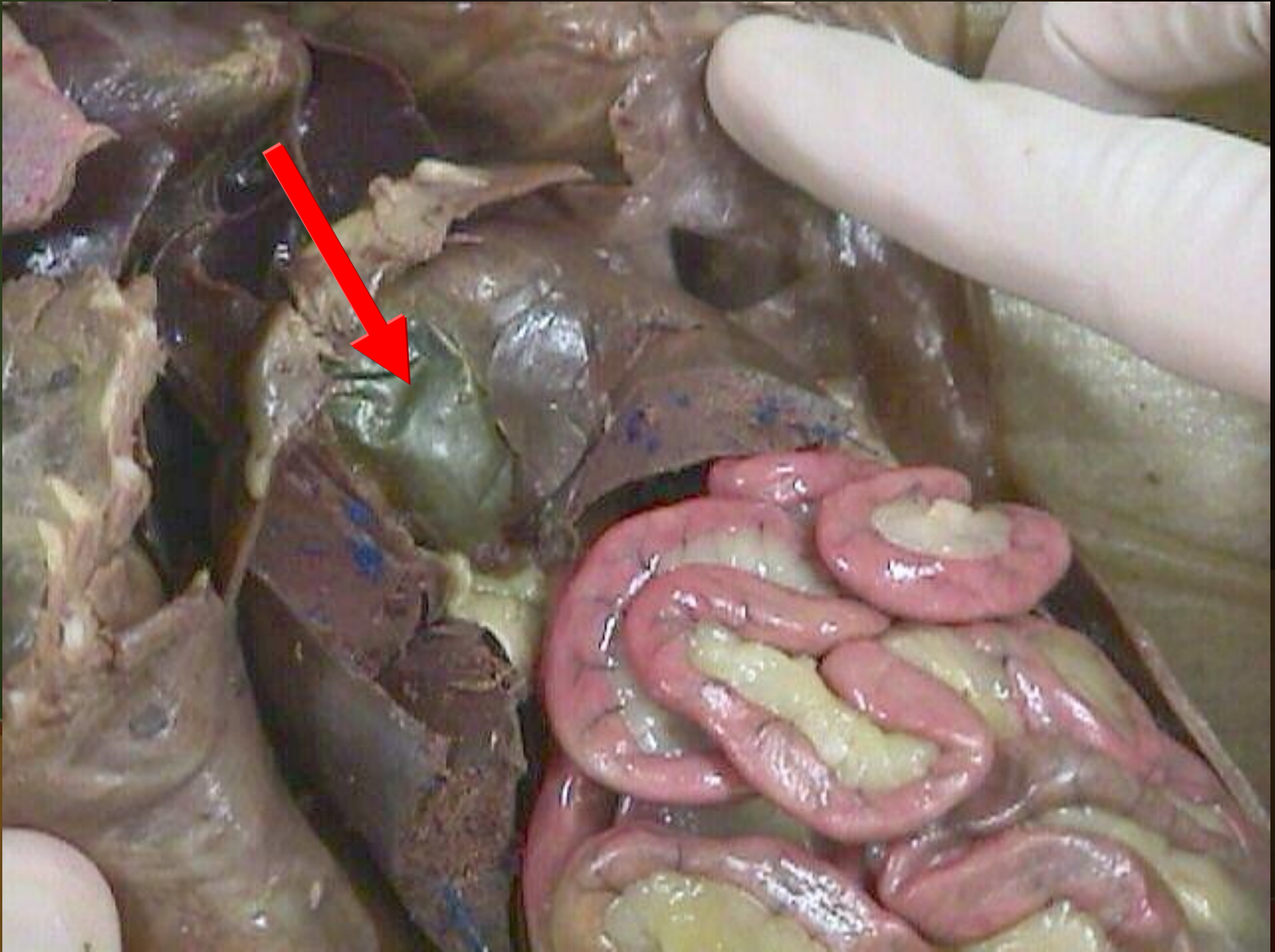
Intestines



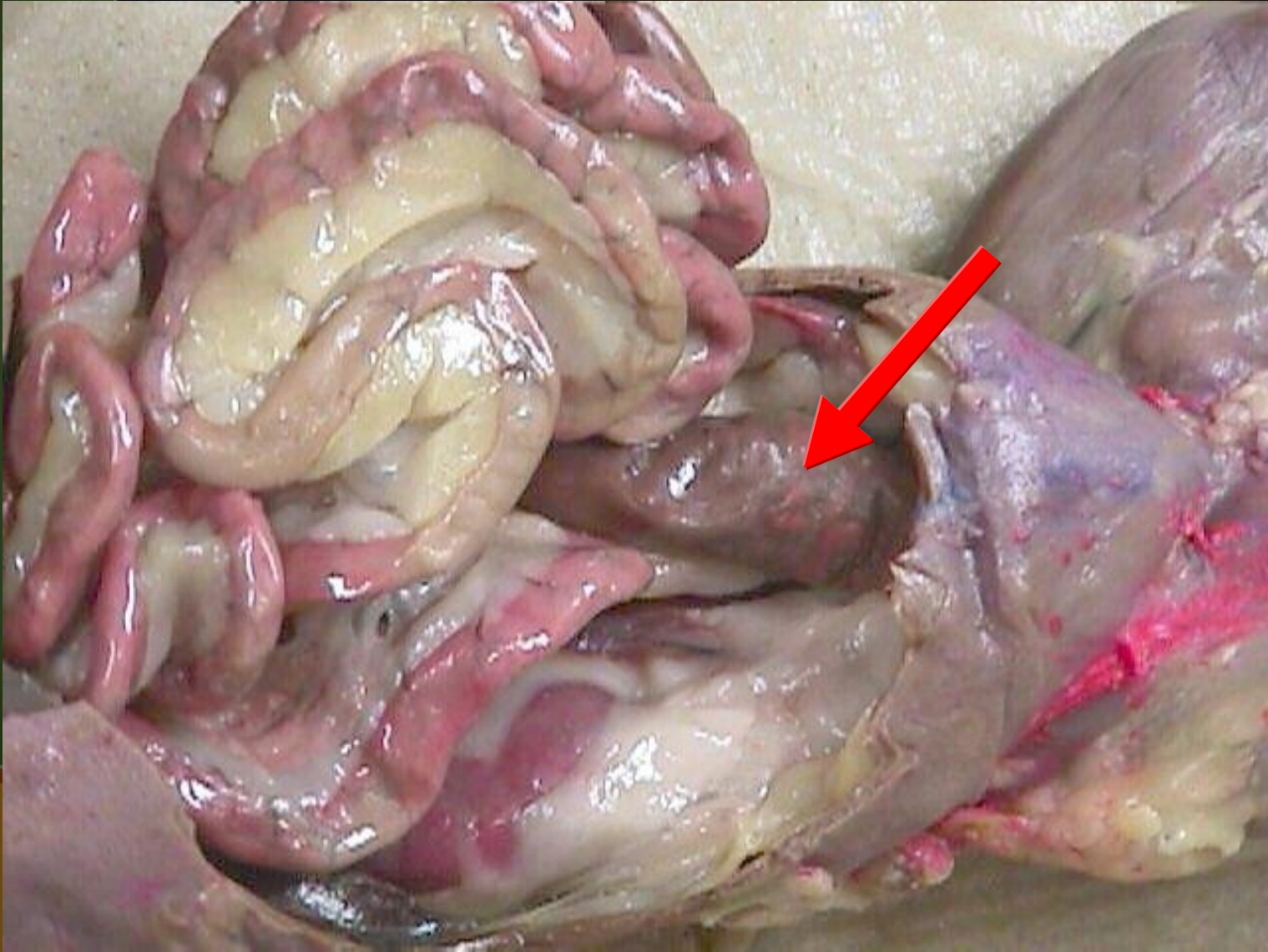
Liver



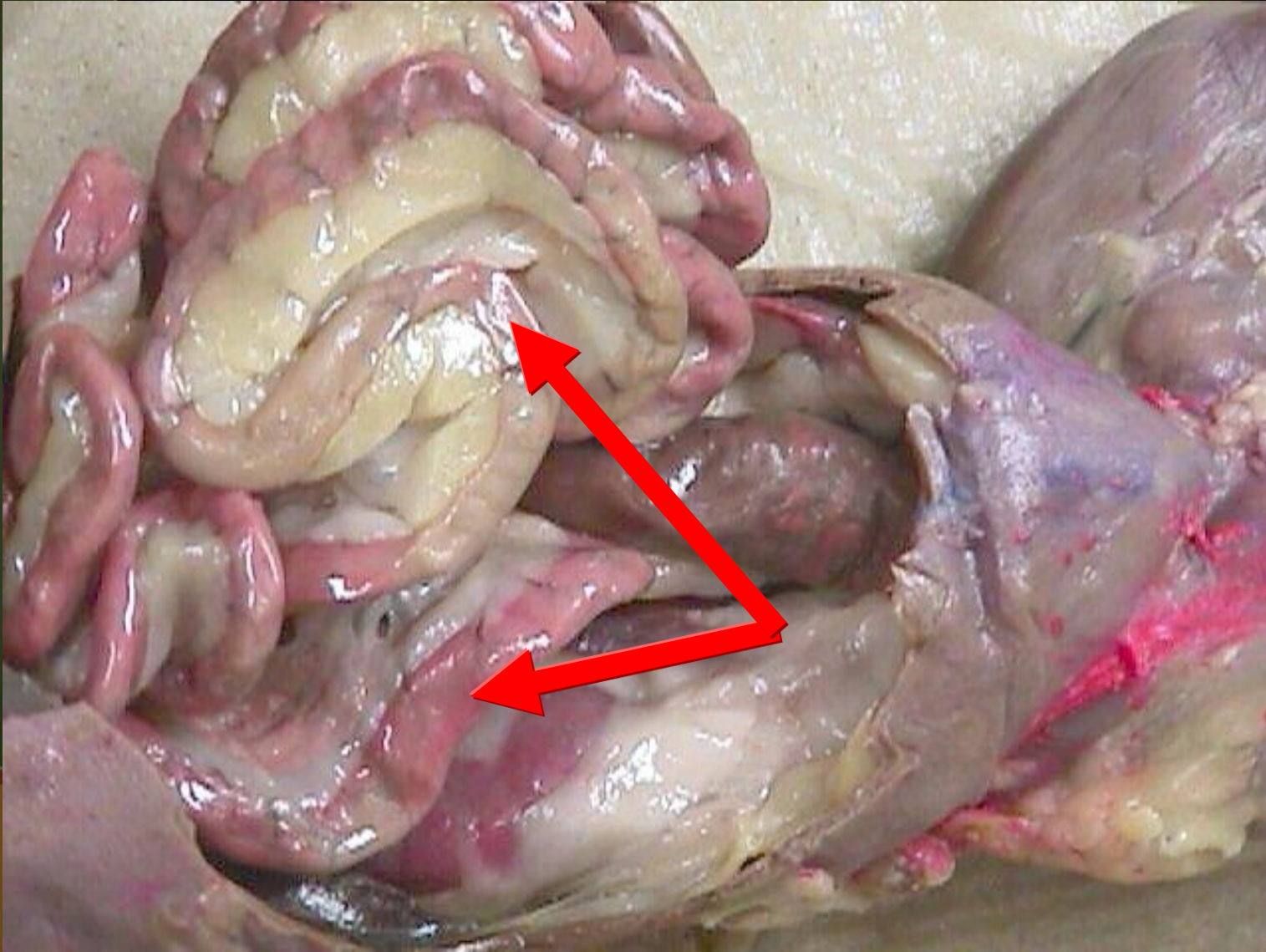
Gall bladder



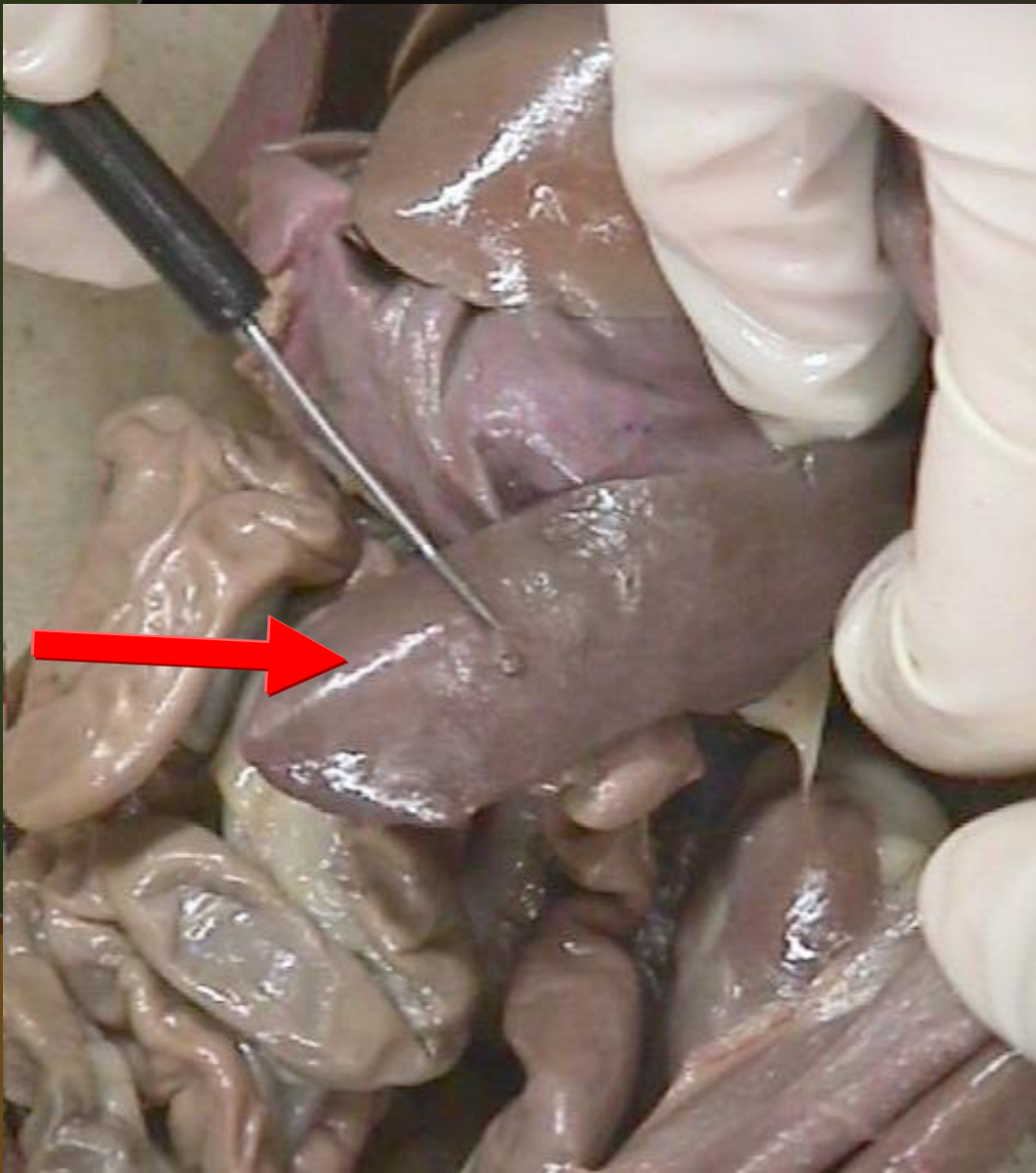Rectum



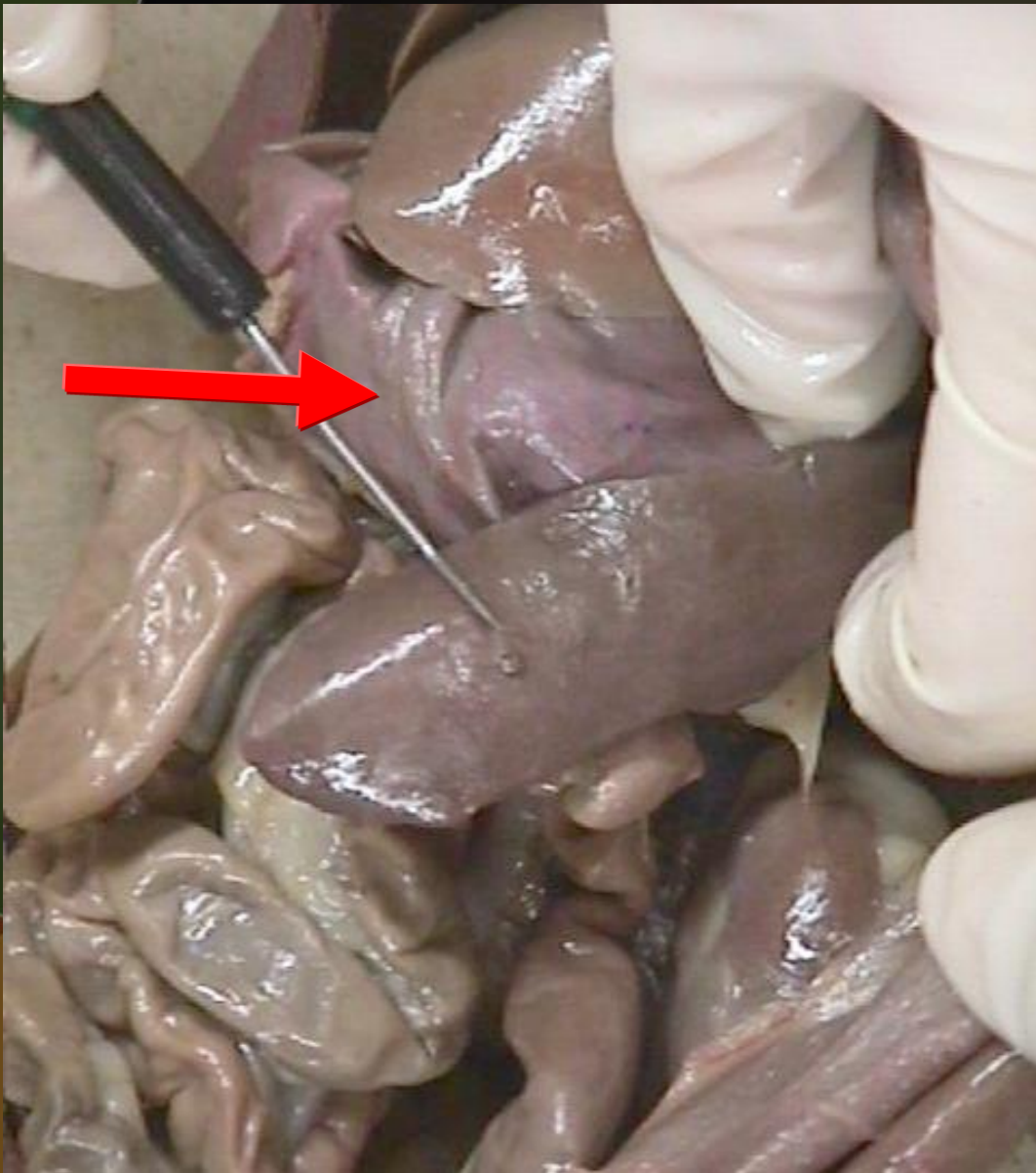Intestines



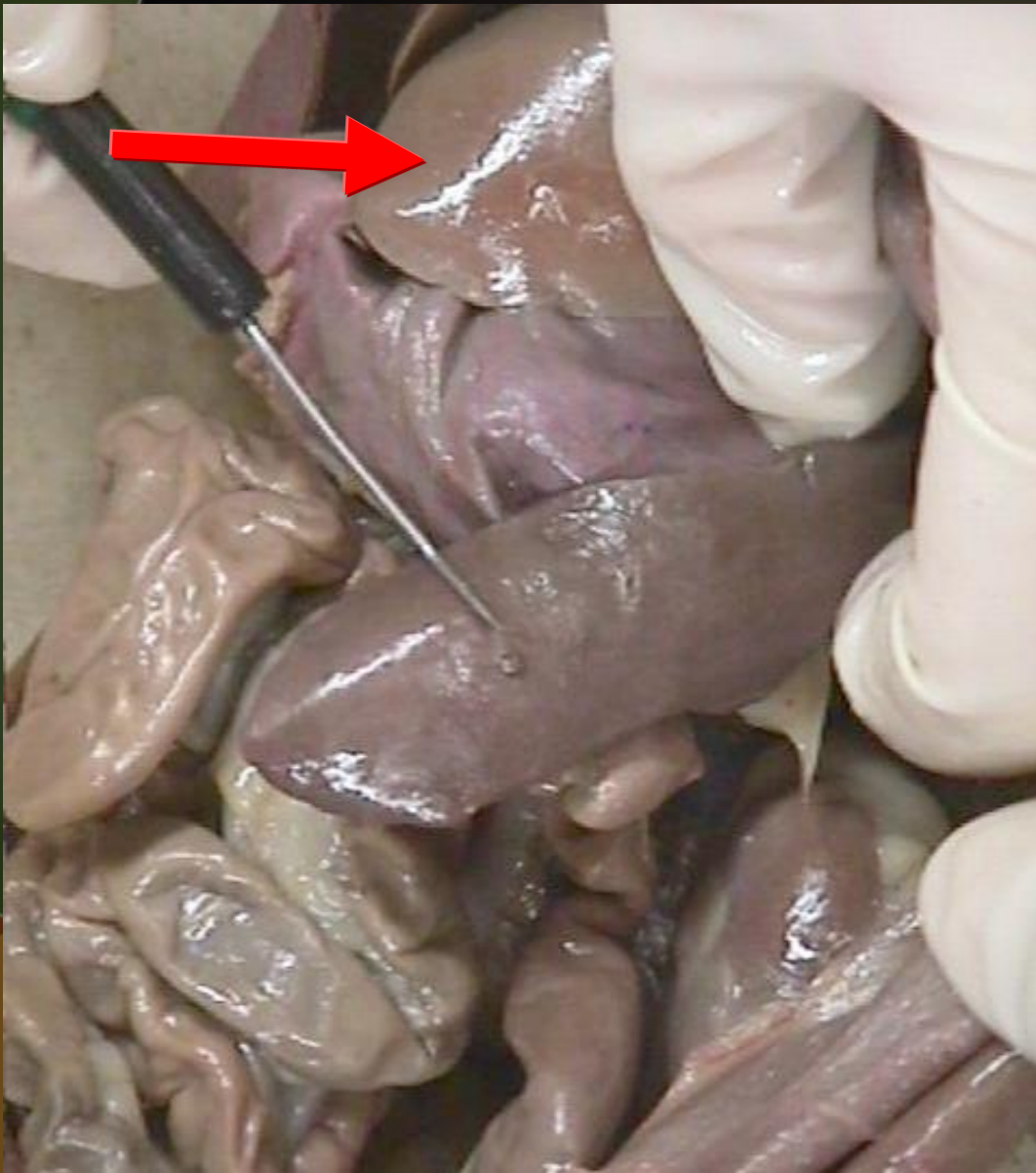Spleen



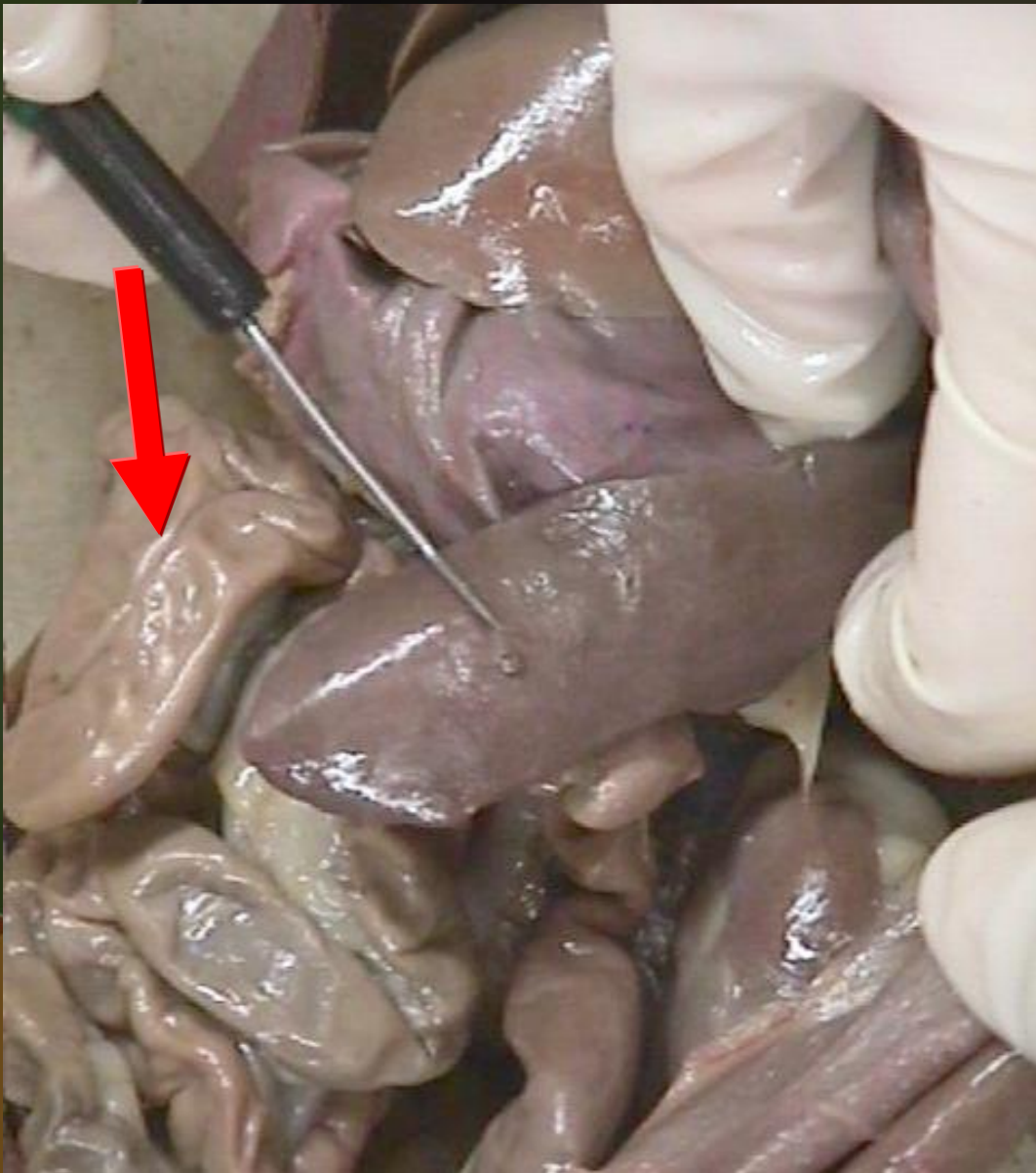Stomach



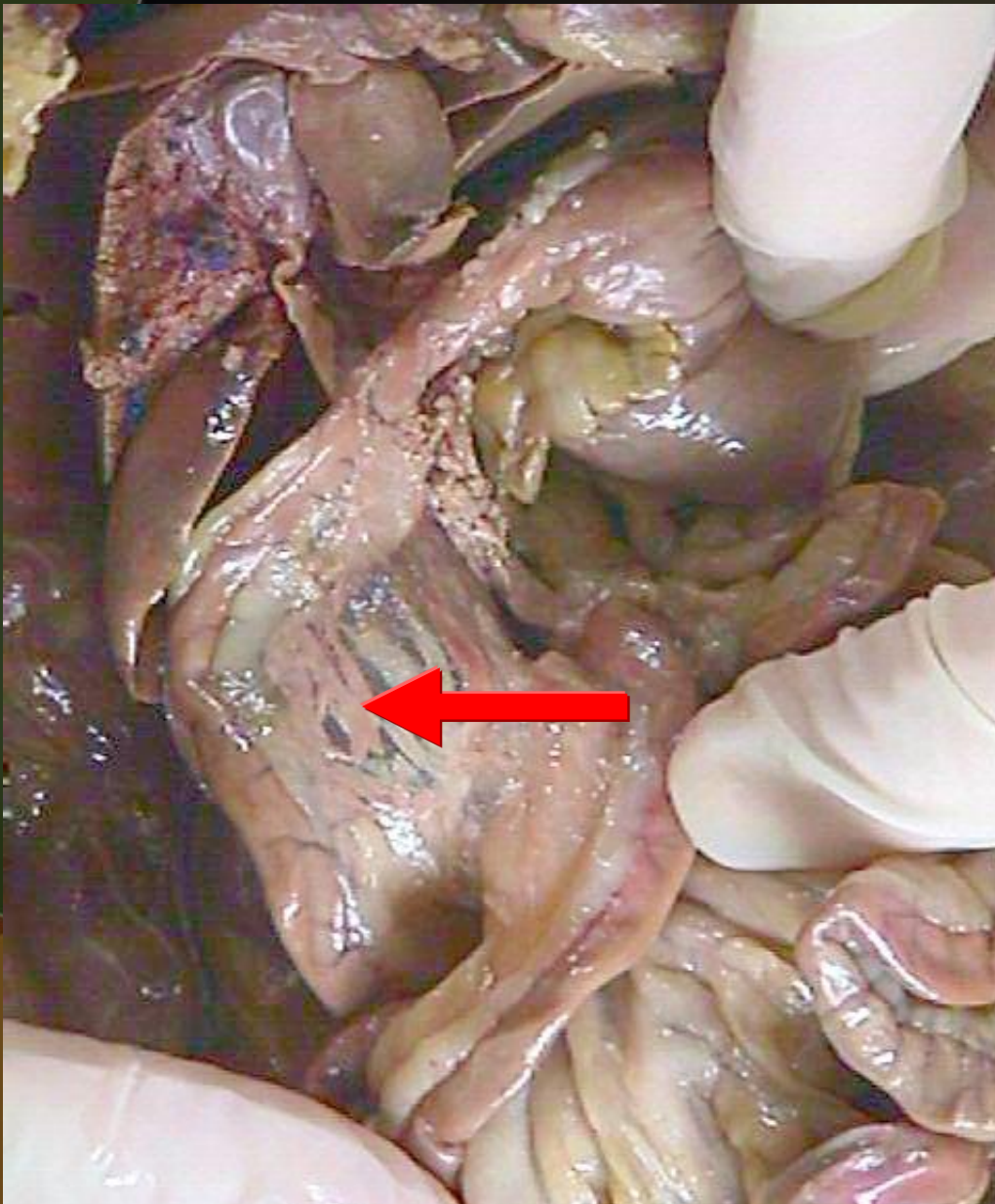
Liver



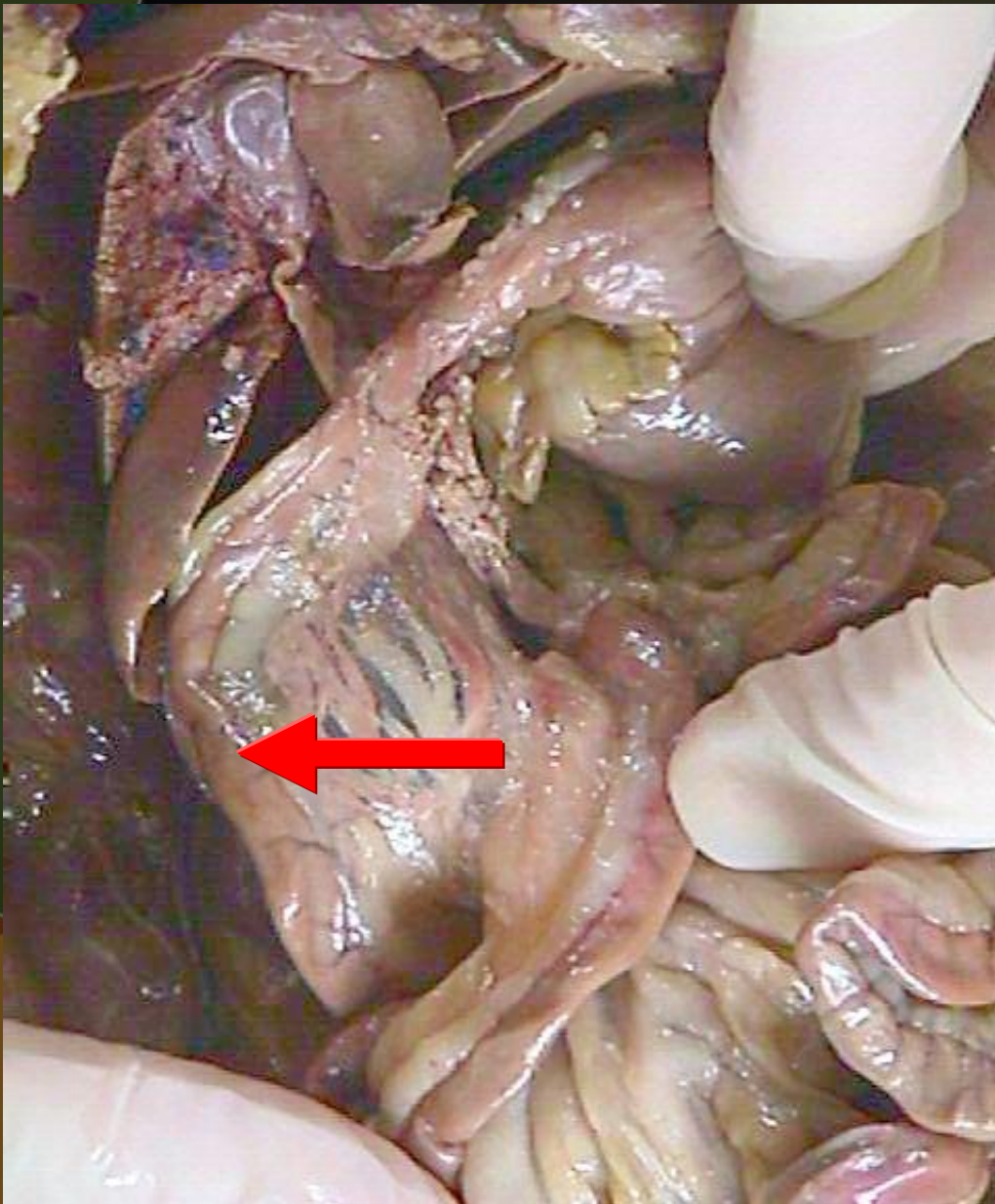
Intestines



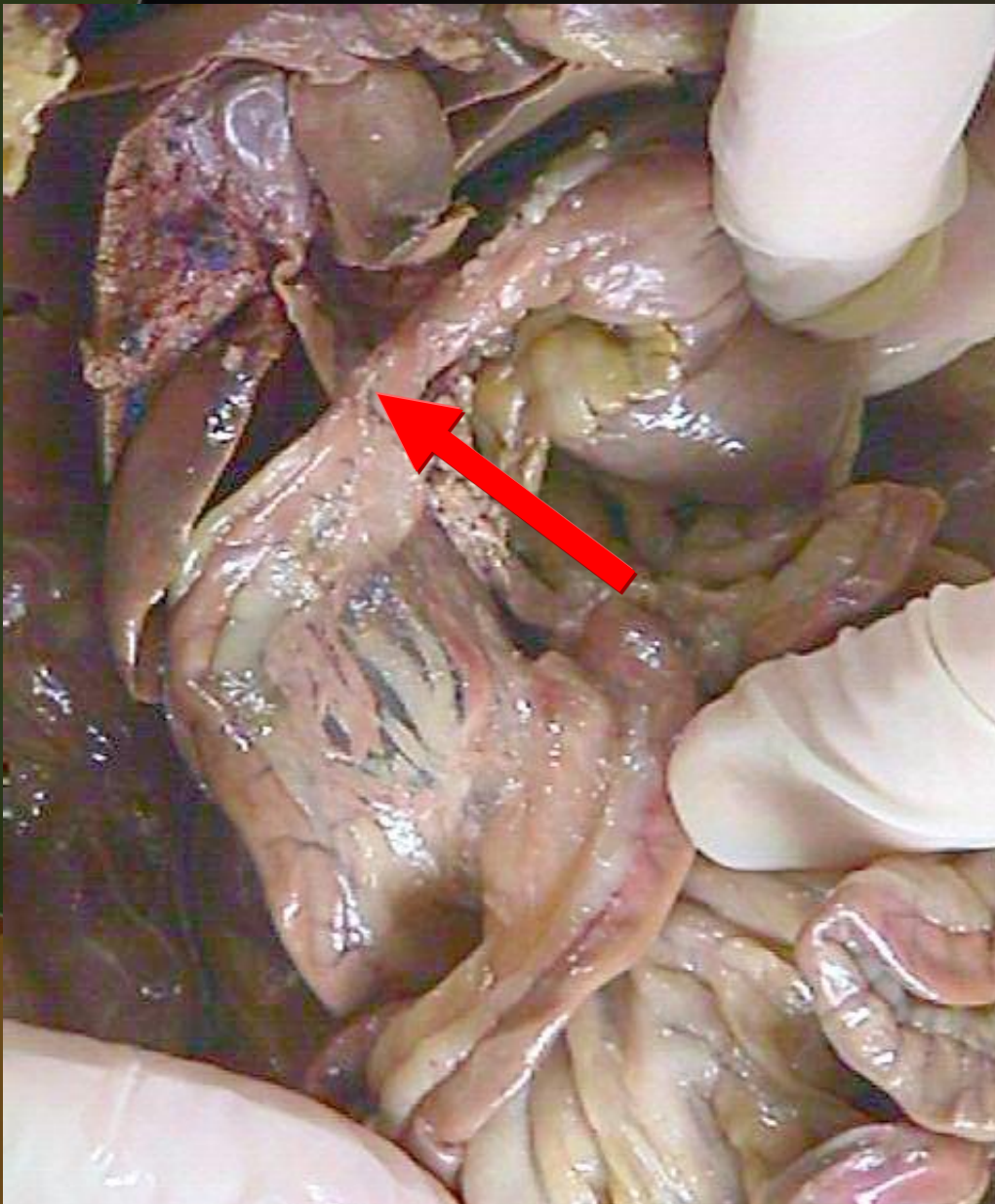
Pancreas



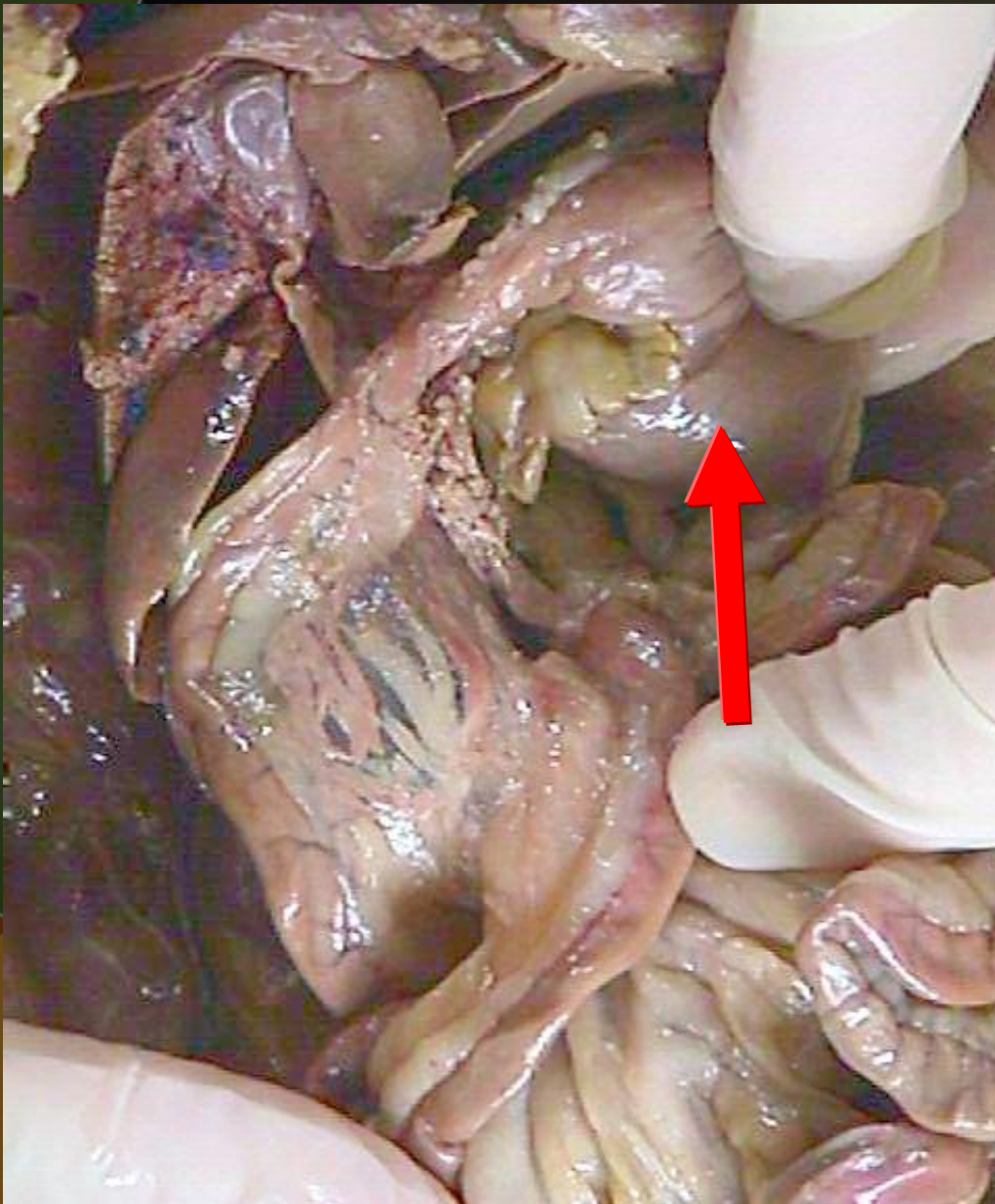
Duodenum



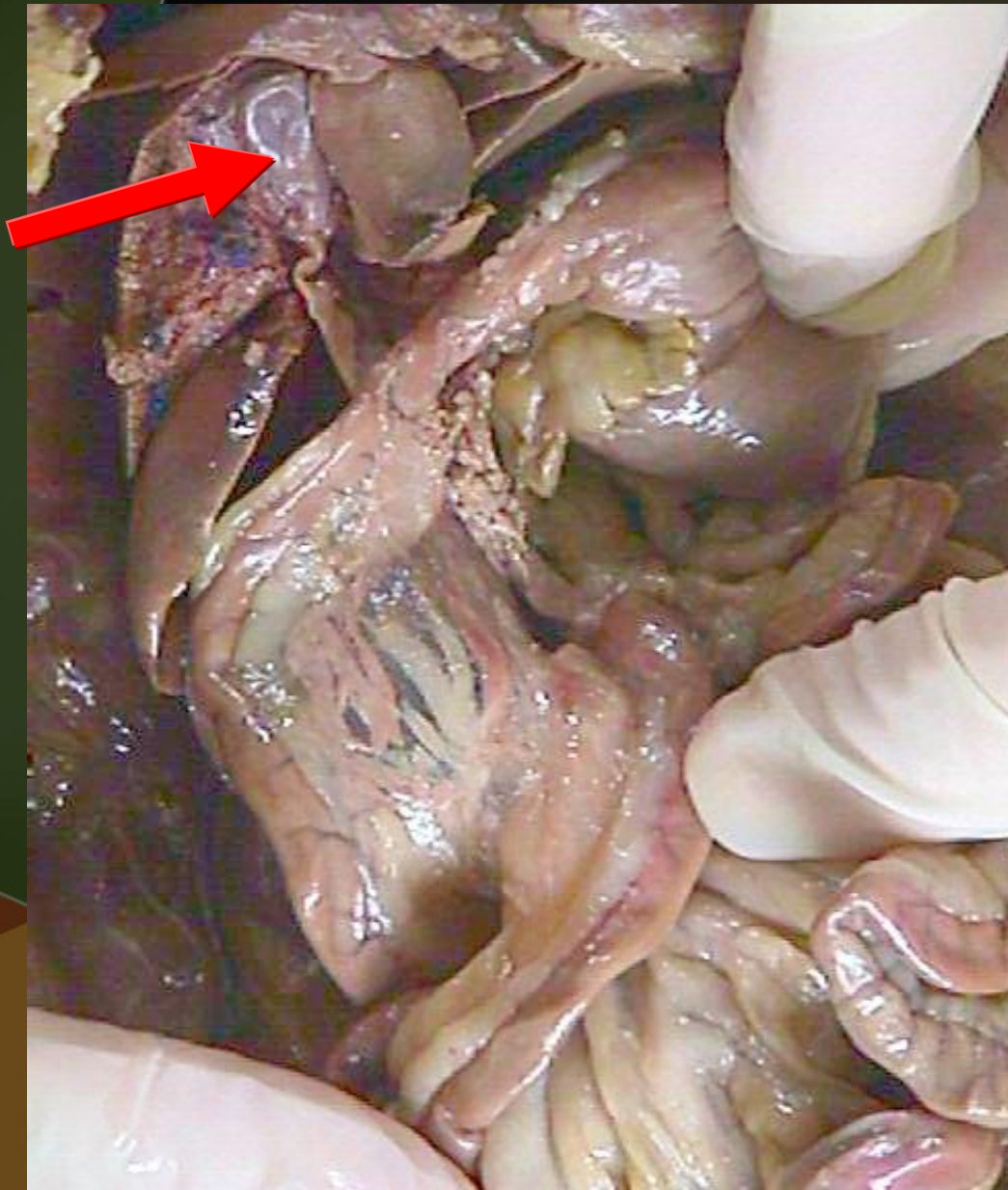
Pyloric sphincter



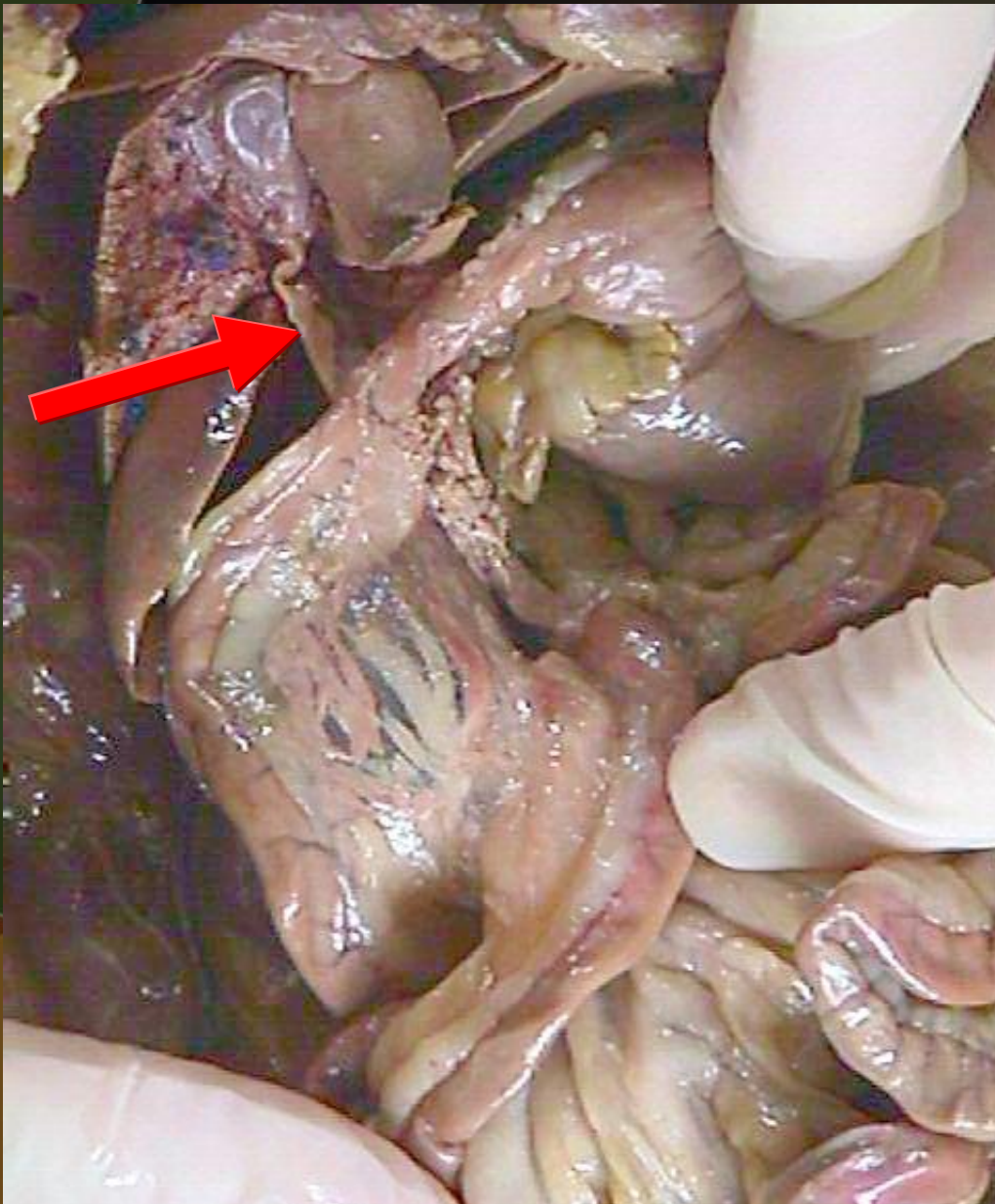
Stomach



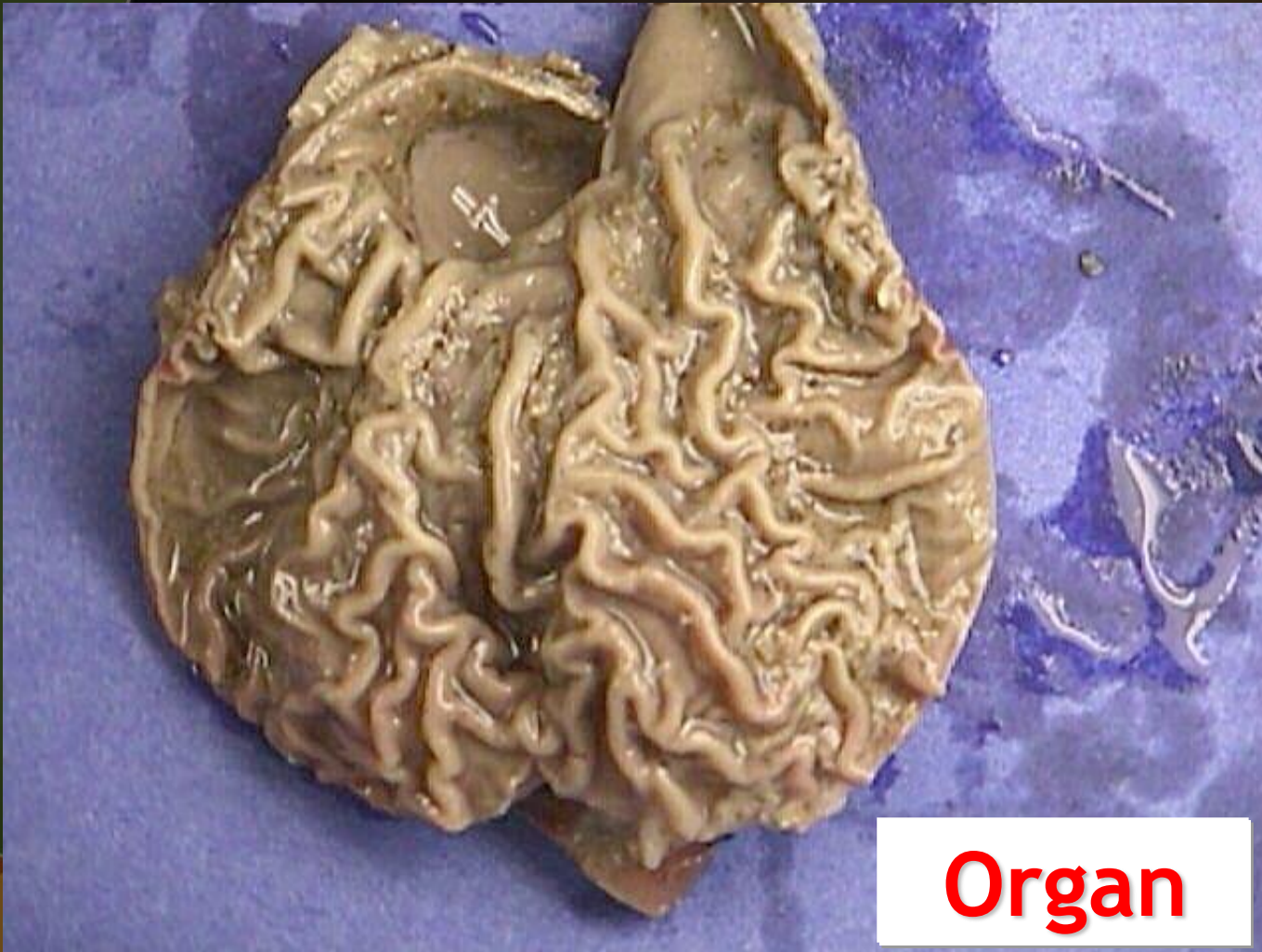
Gall bladder



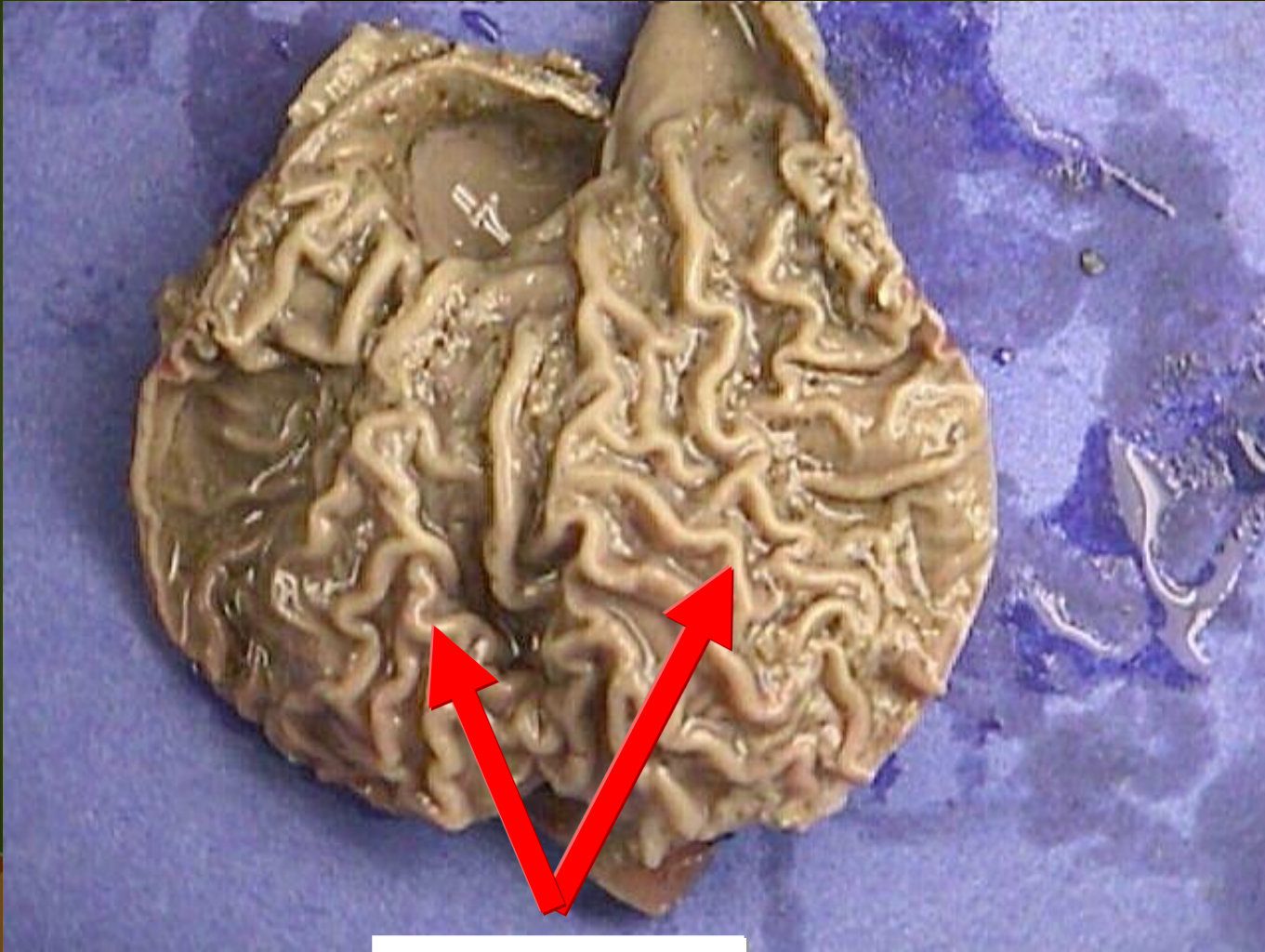
Cystic duct



Stomach

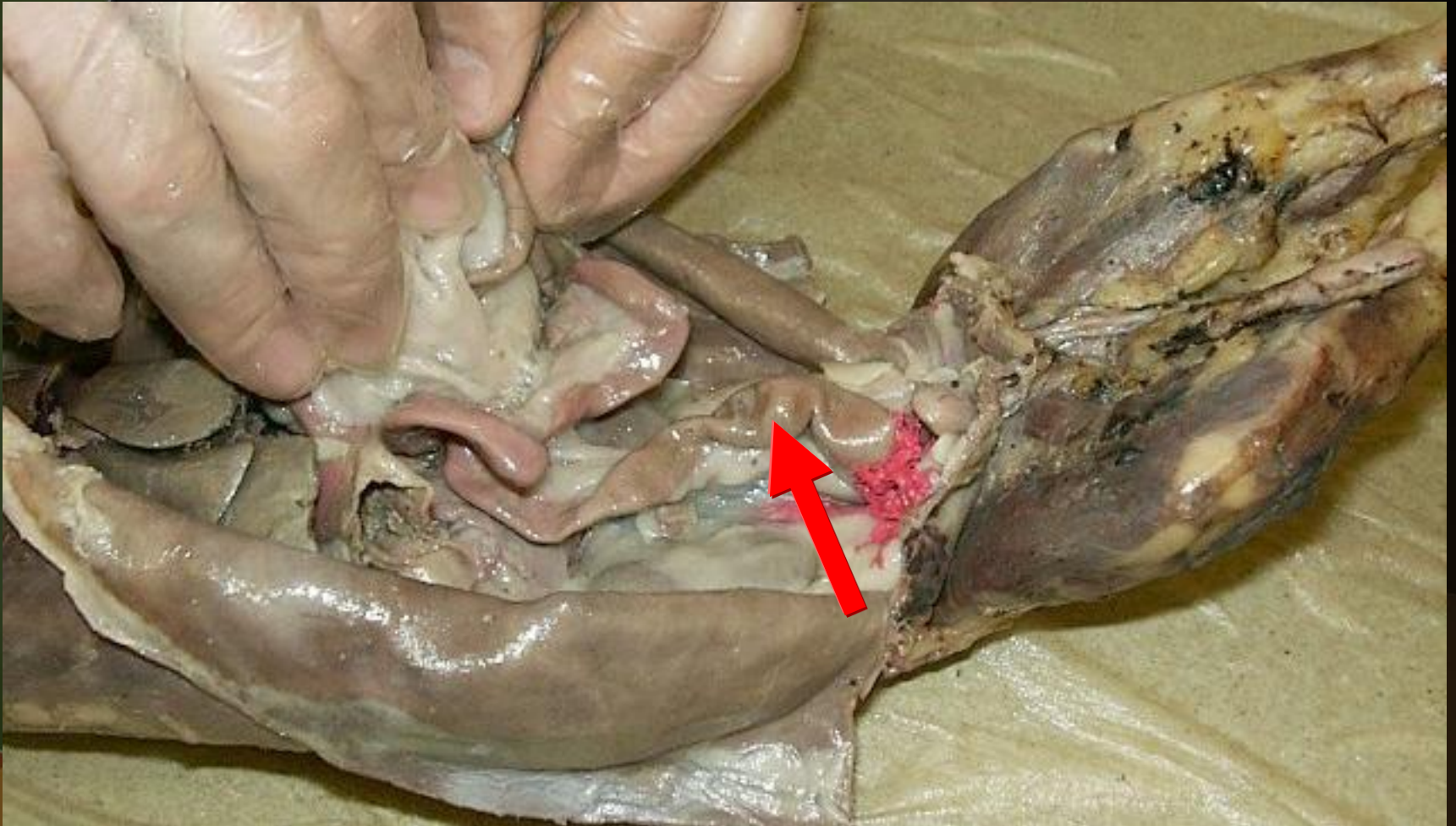


Gastric rugae

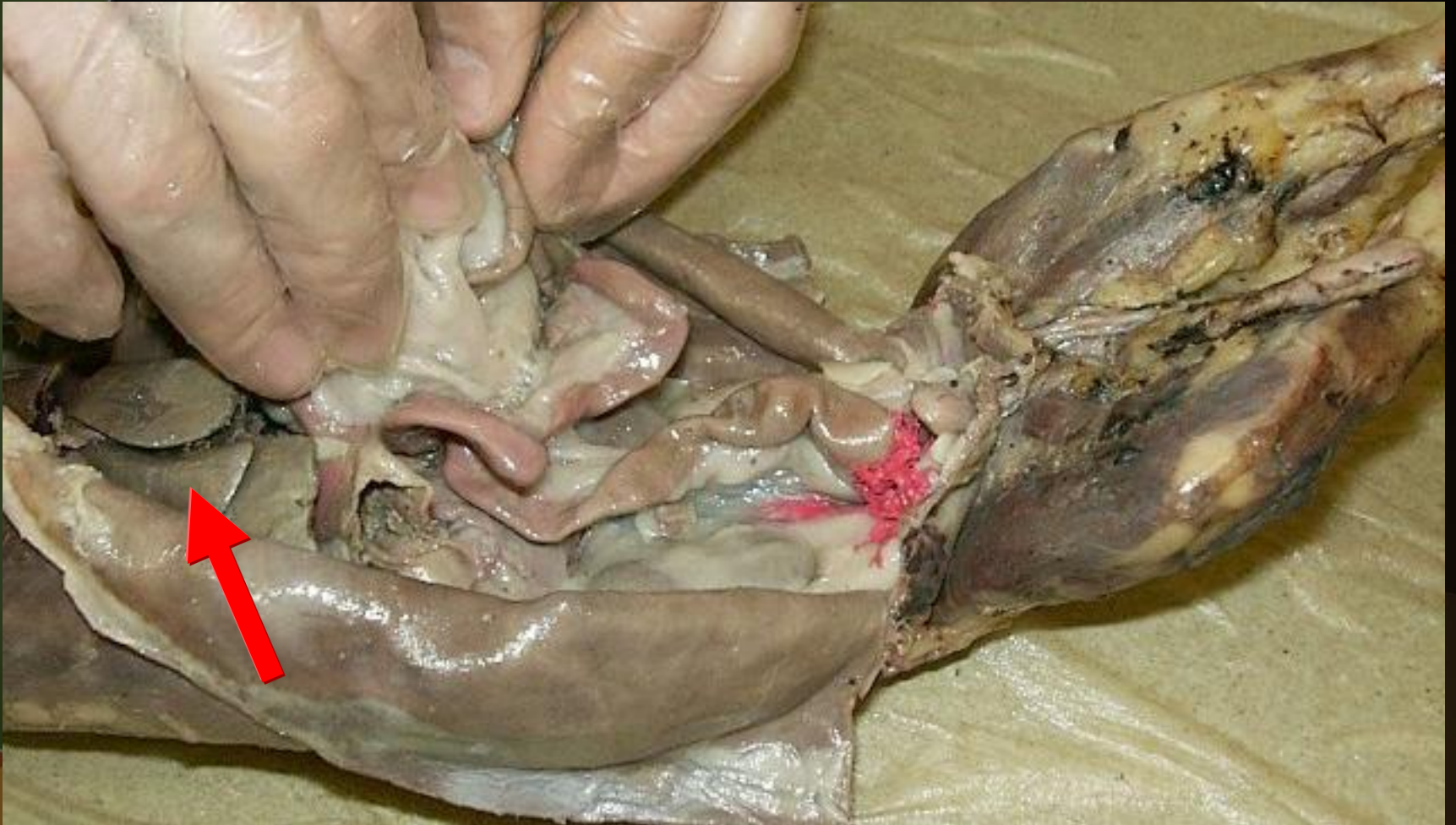

(Folds)

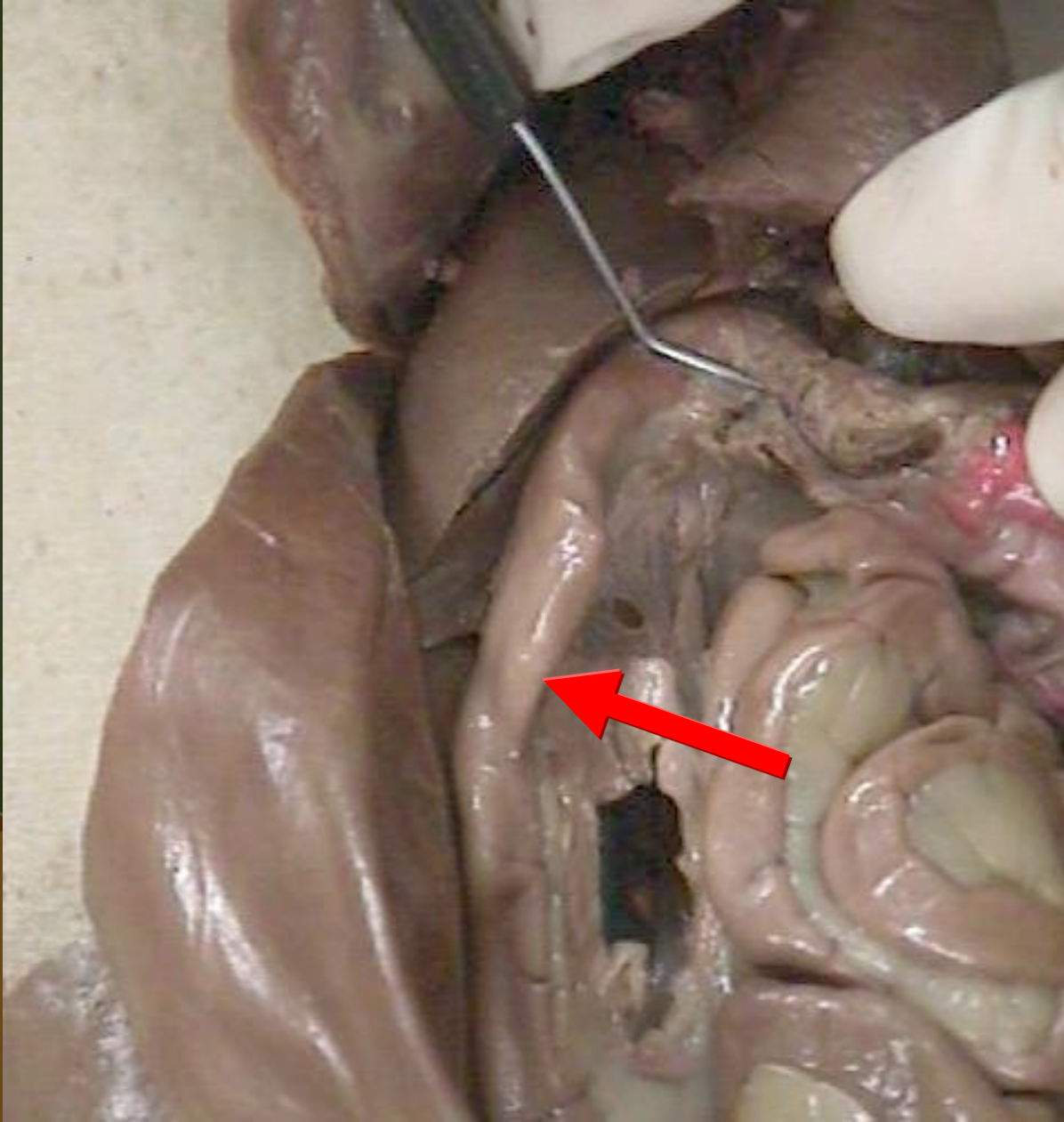
Rectum



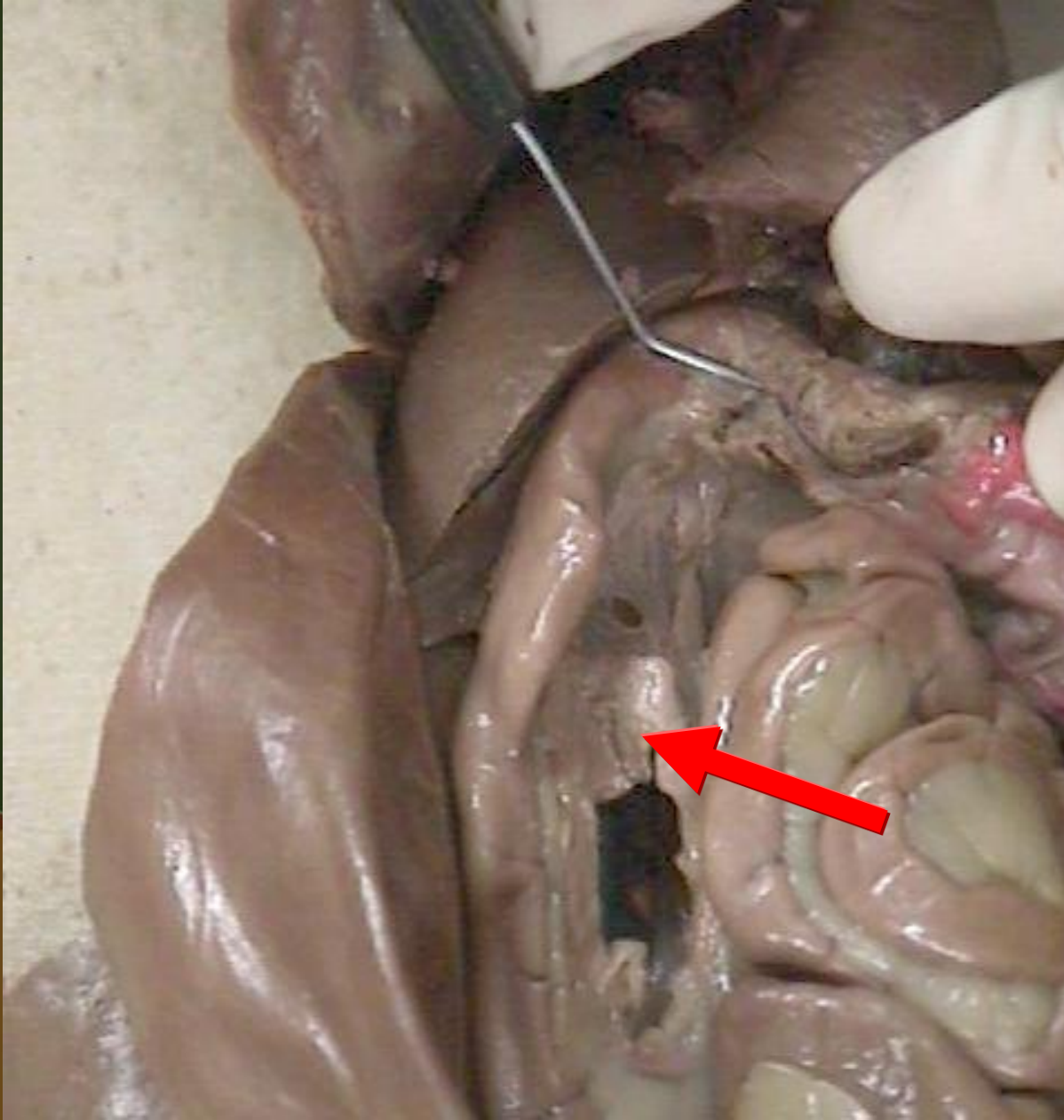
Liver



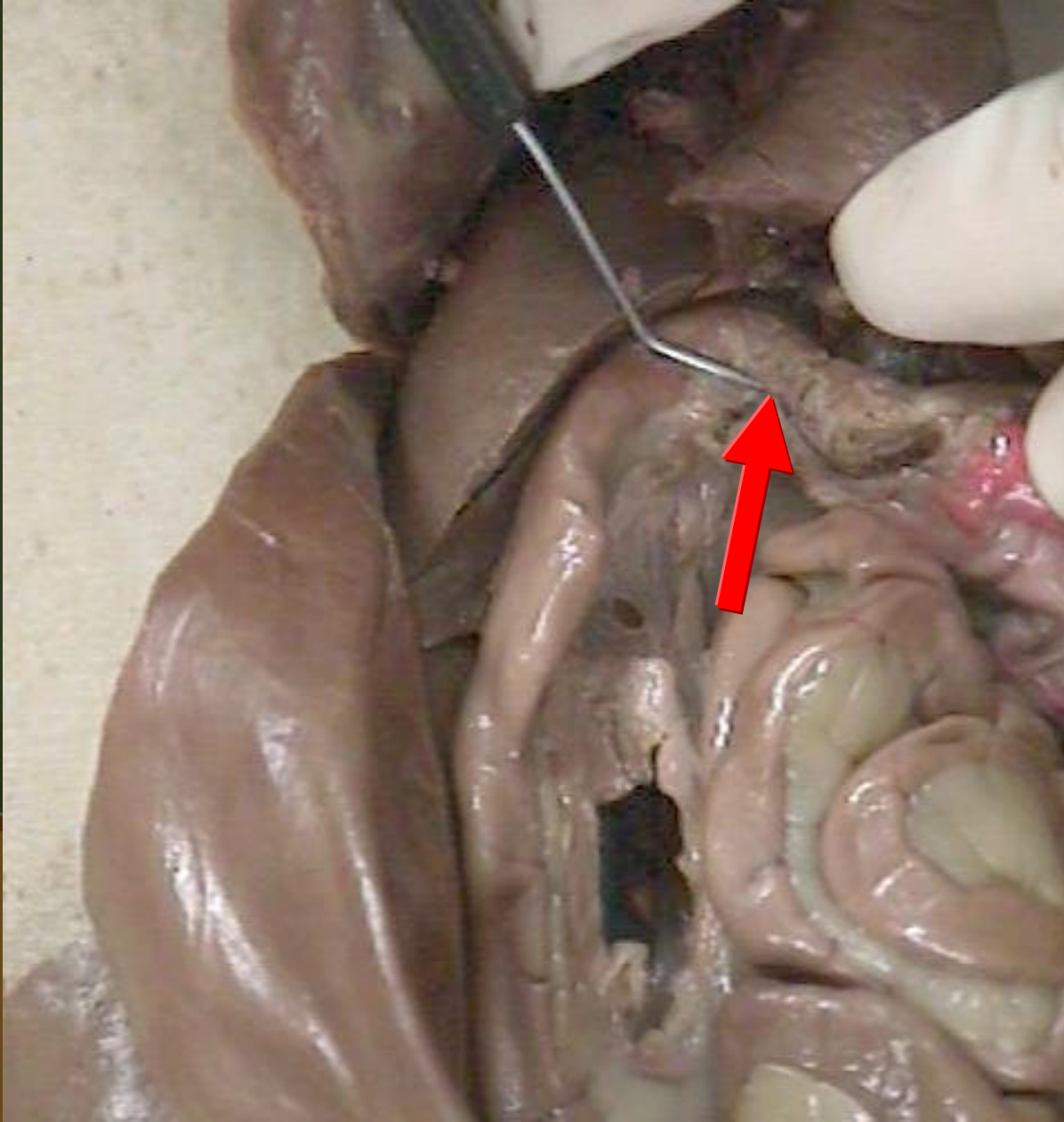
Duodenum



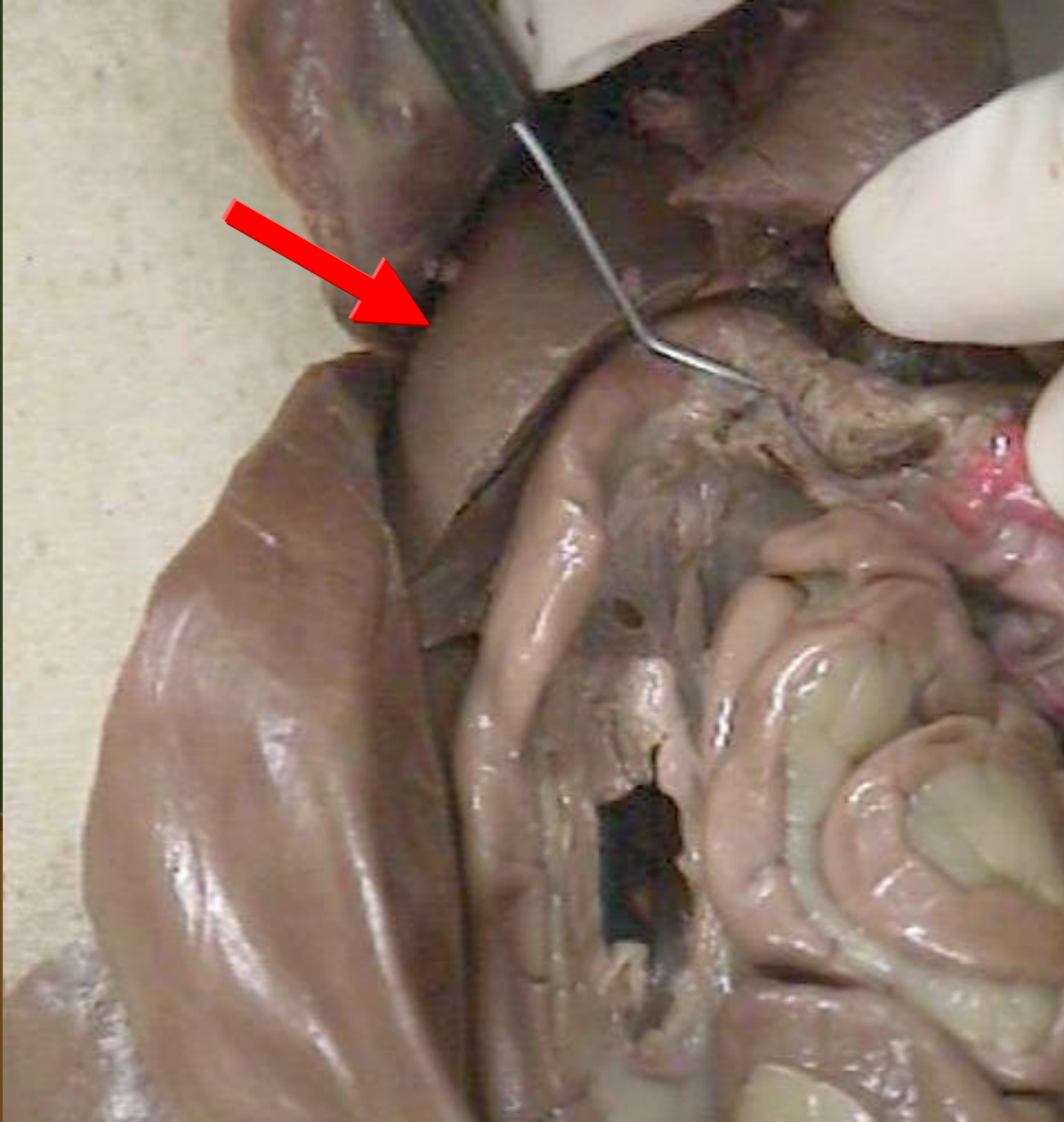
Pancreas



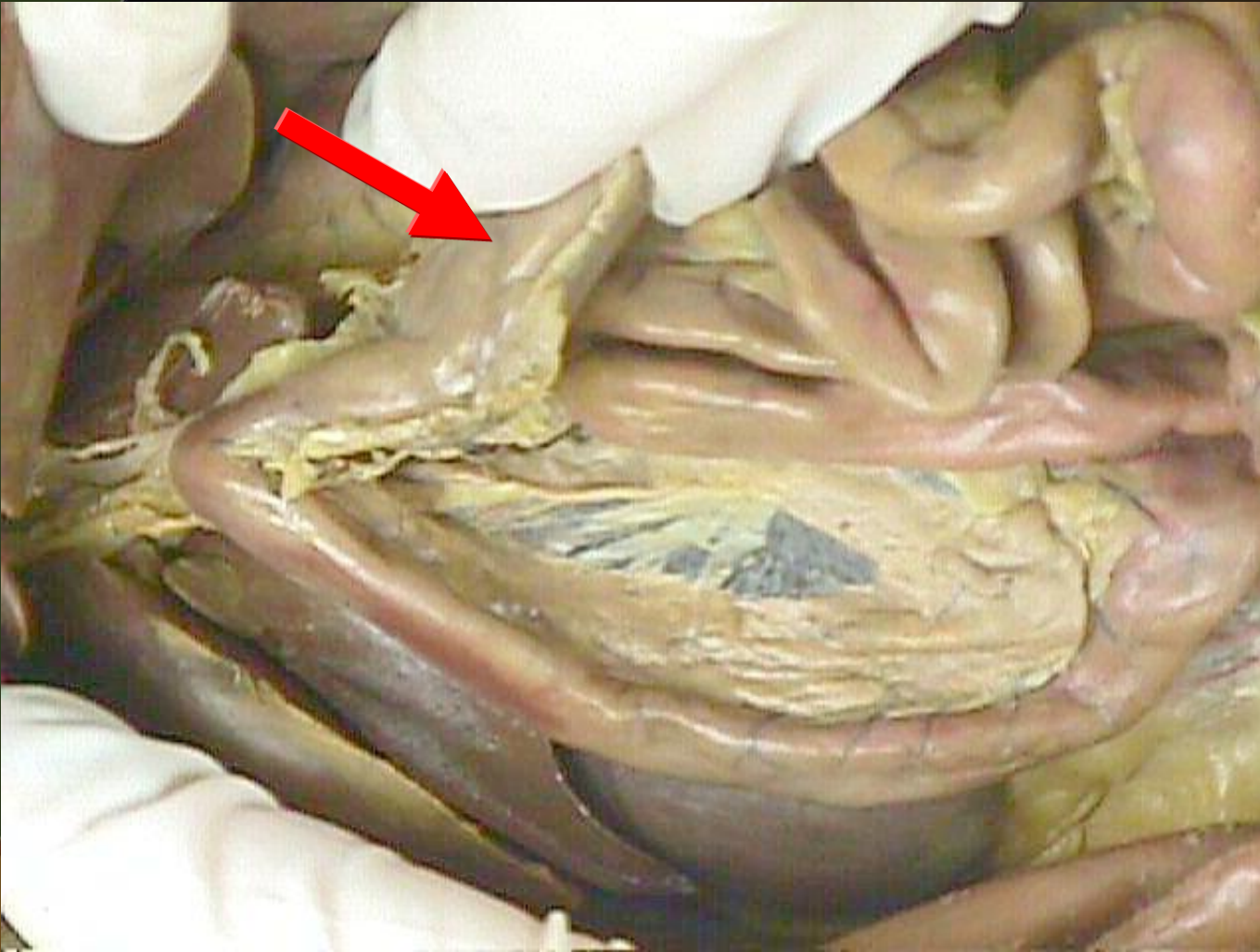
Pyloric sphincter



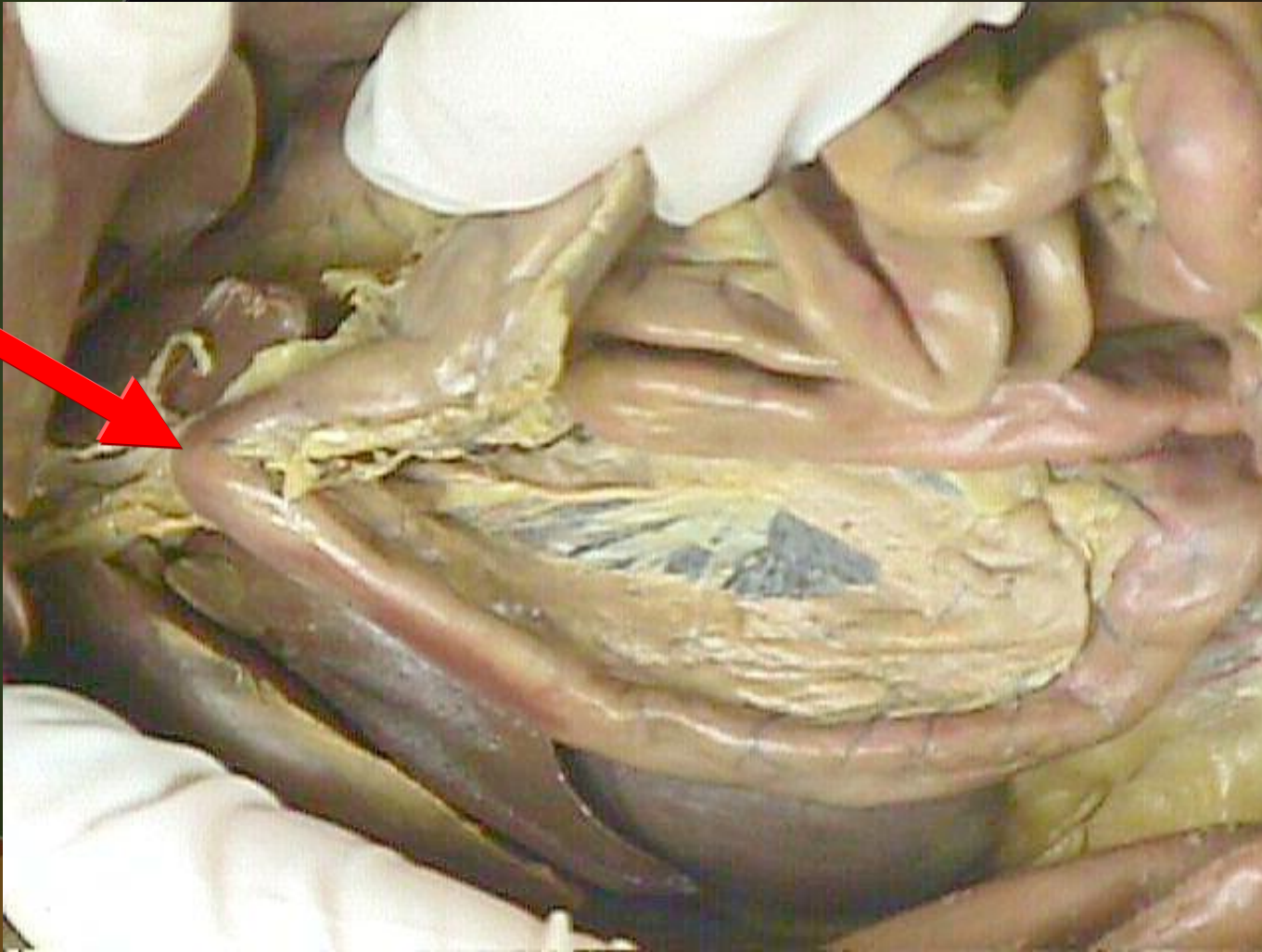Liver



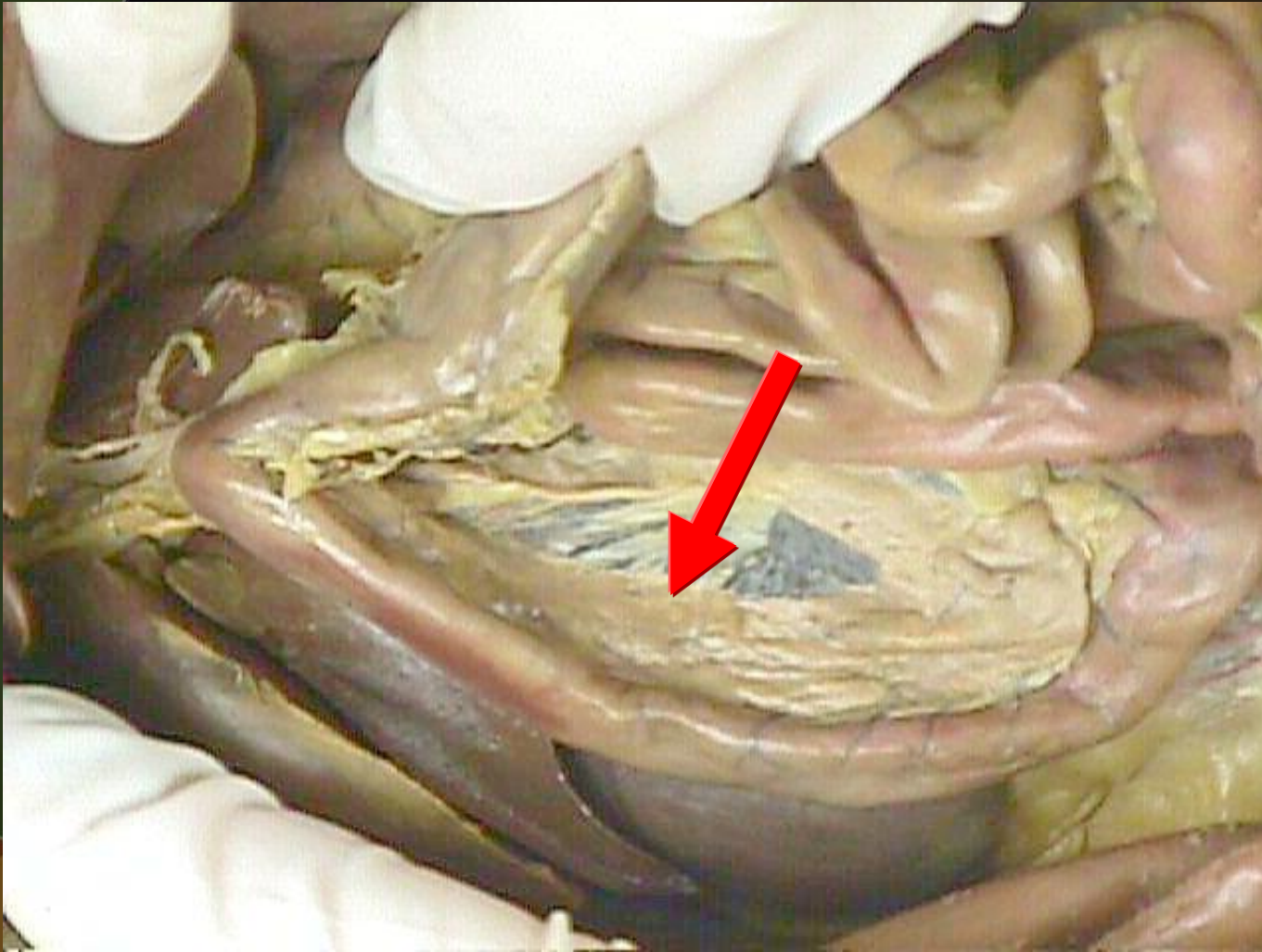
Stomach



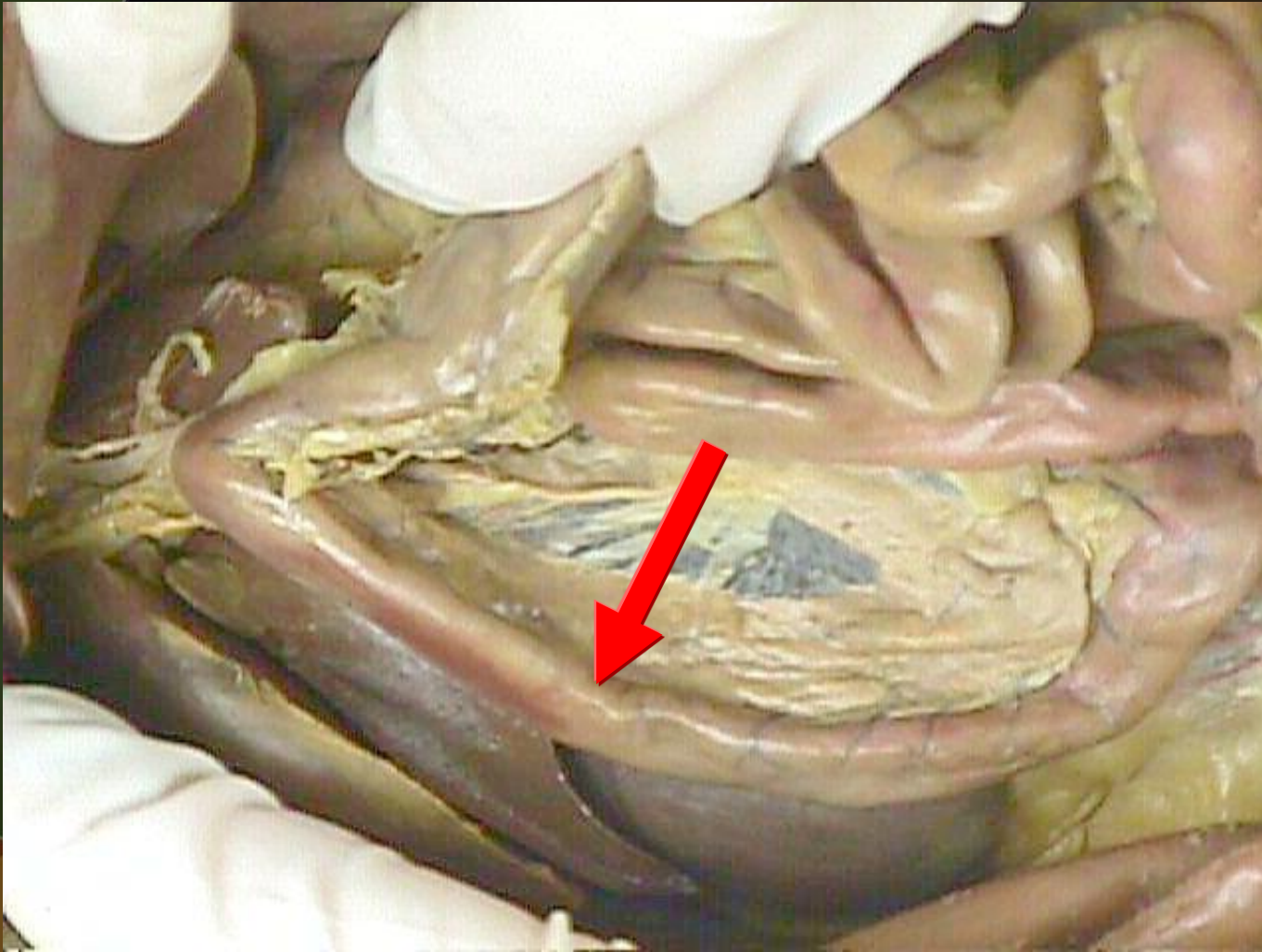
Pyloric sphincter



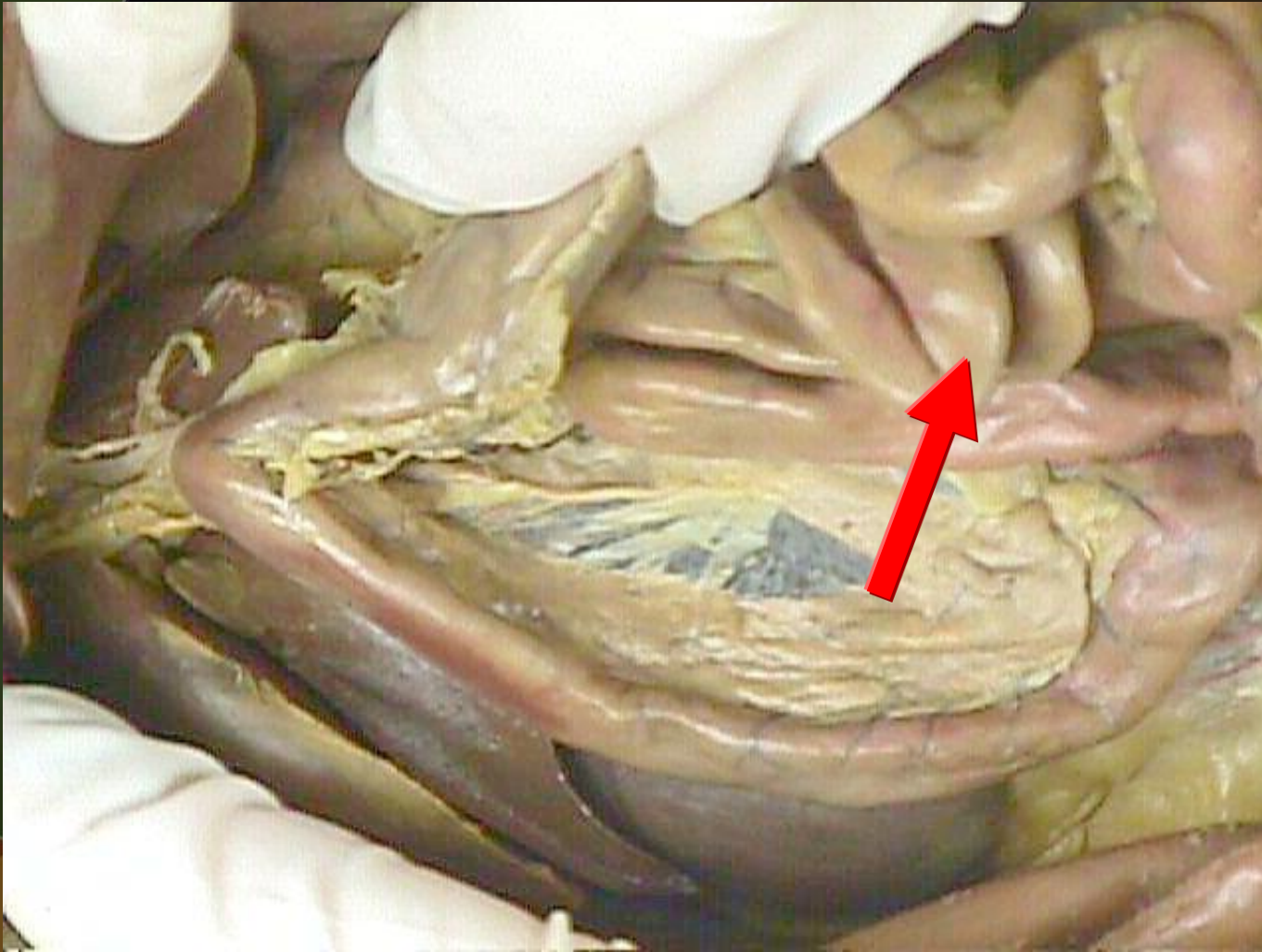
Pancreas



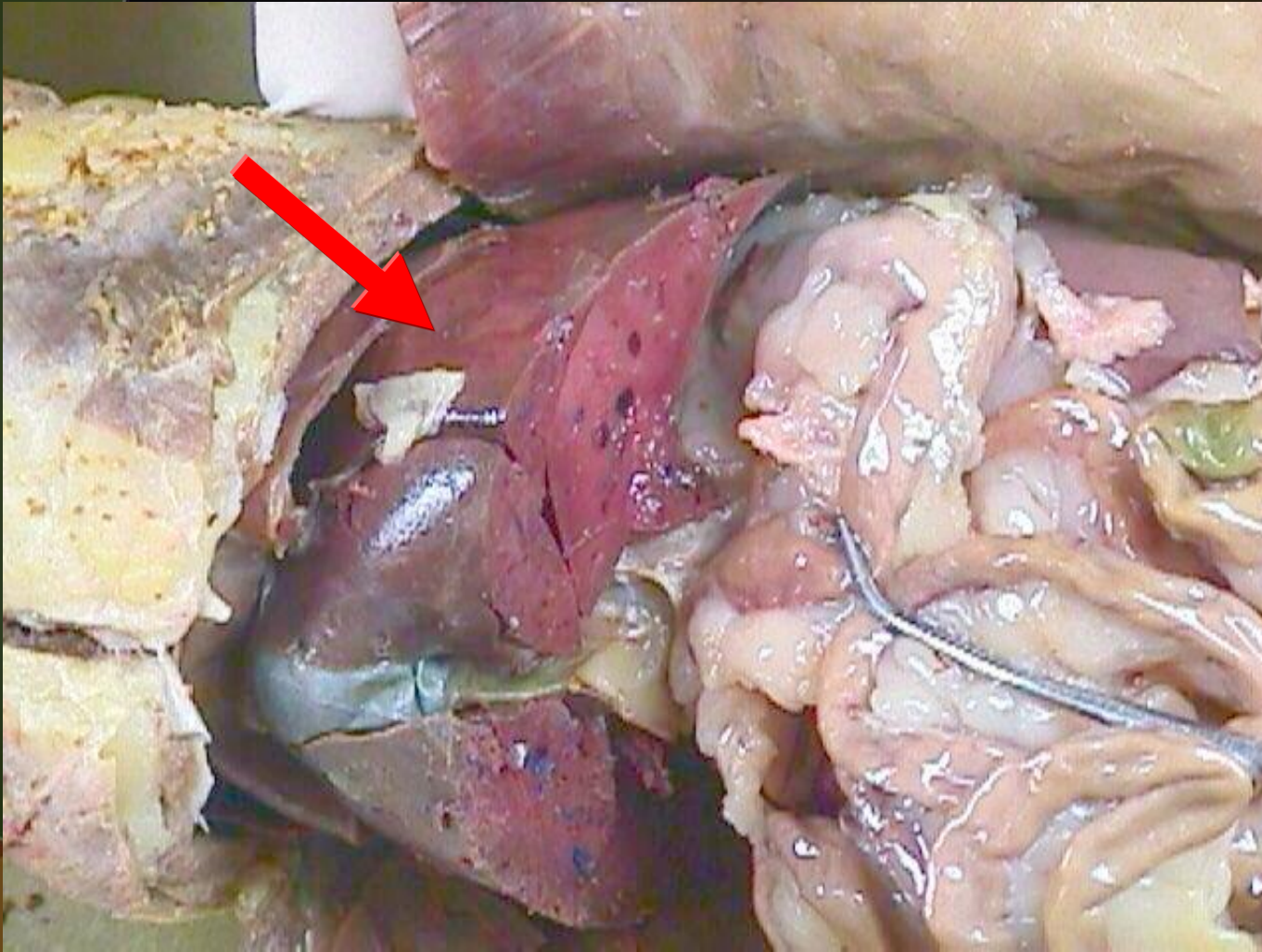
Duodenum



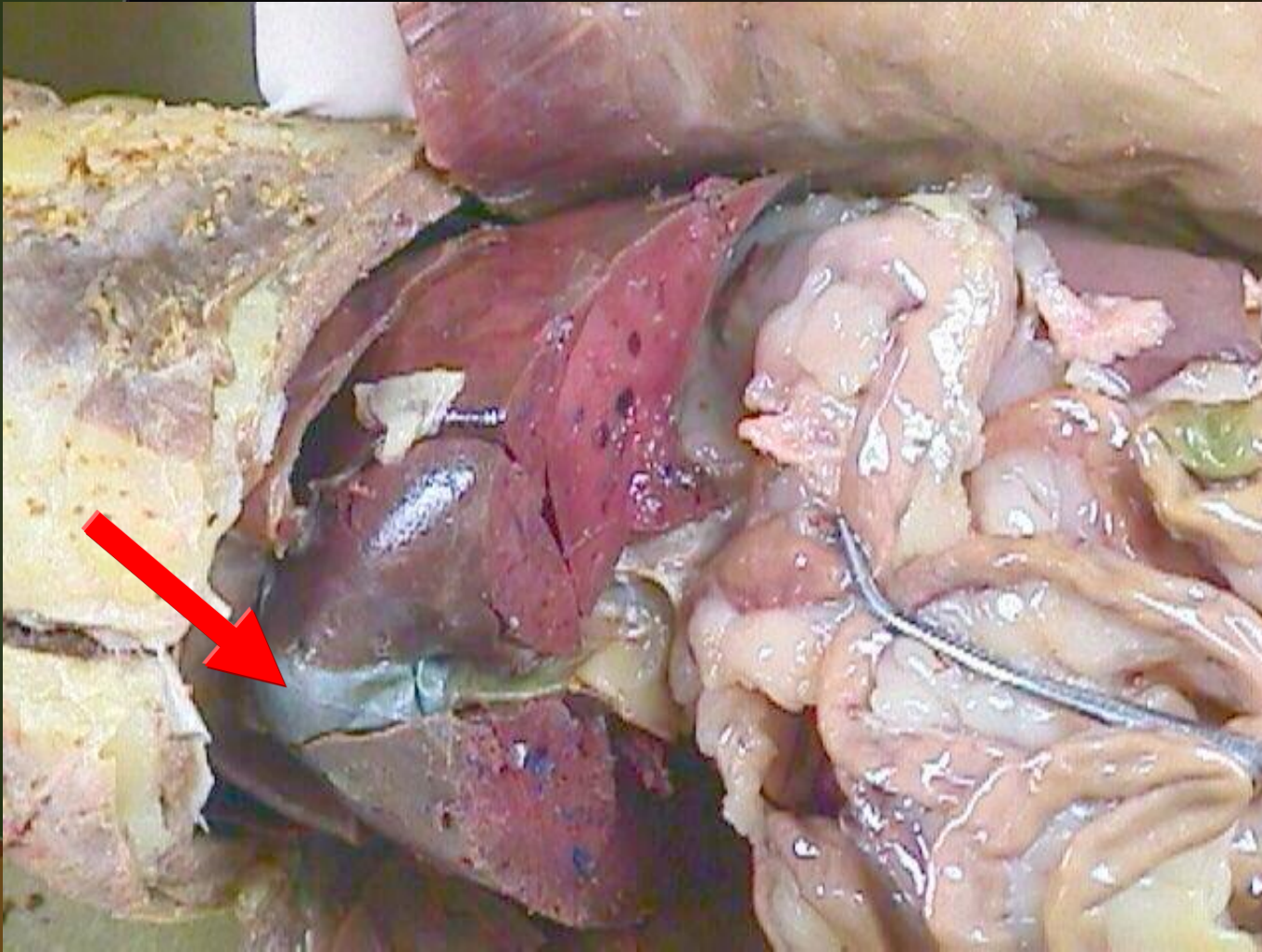
Intestines



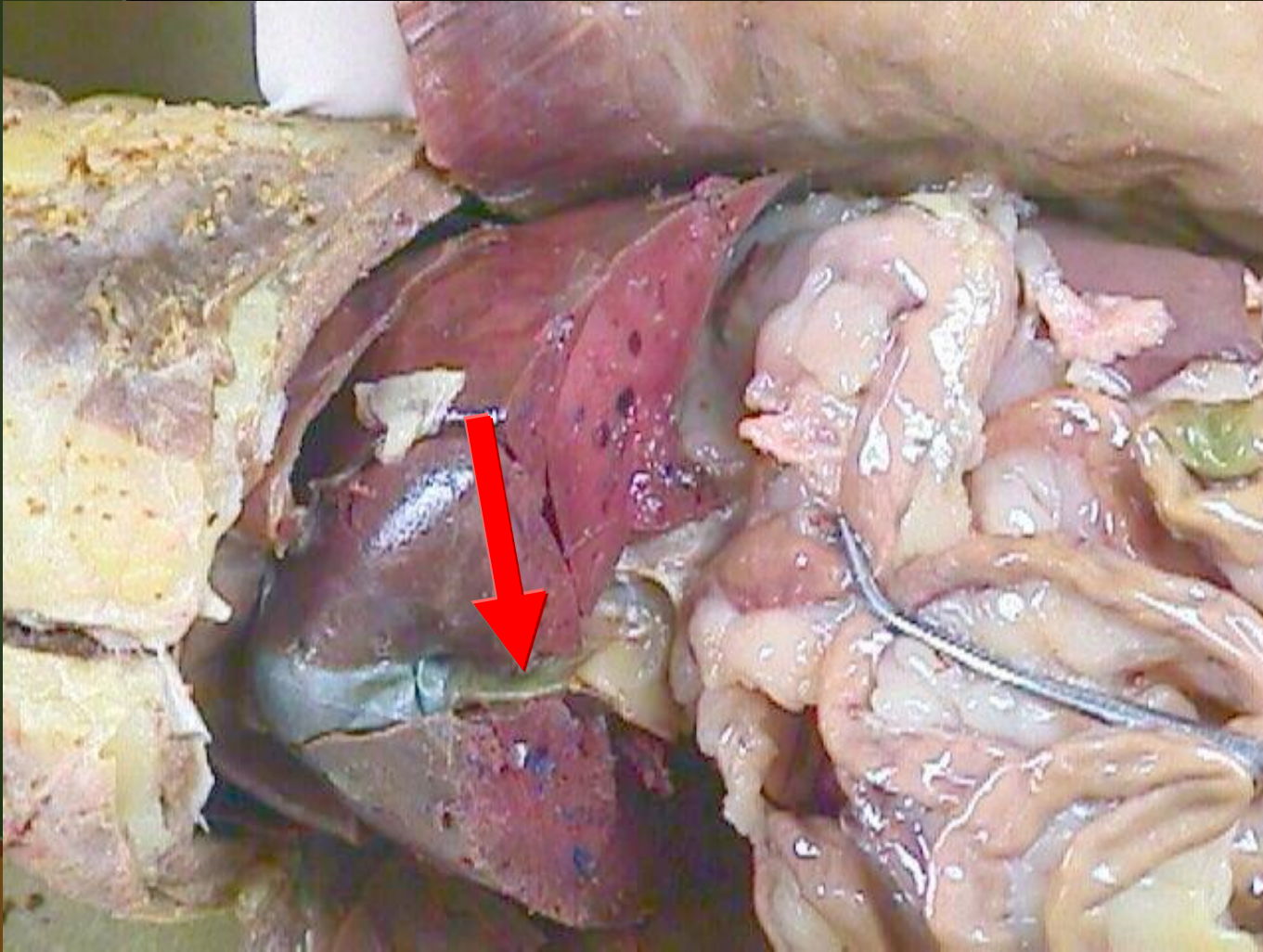
Liver



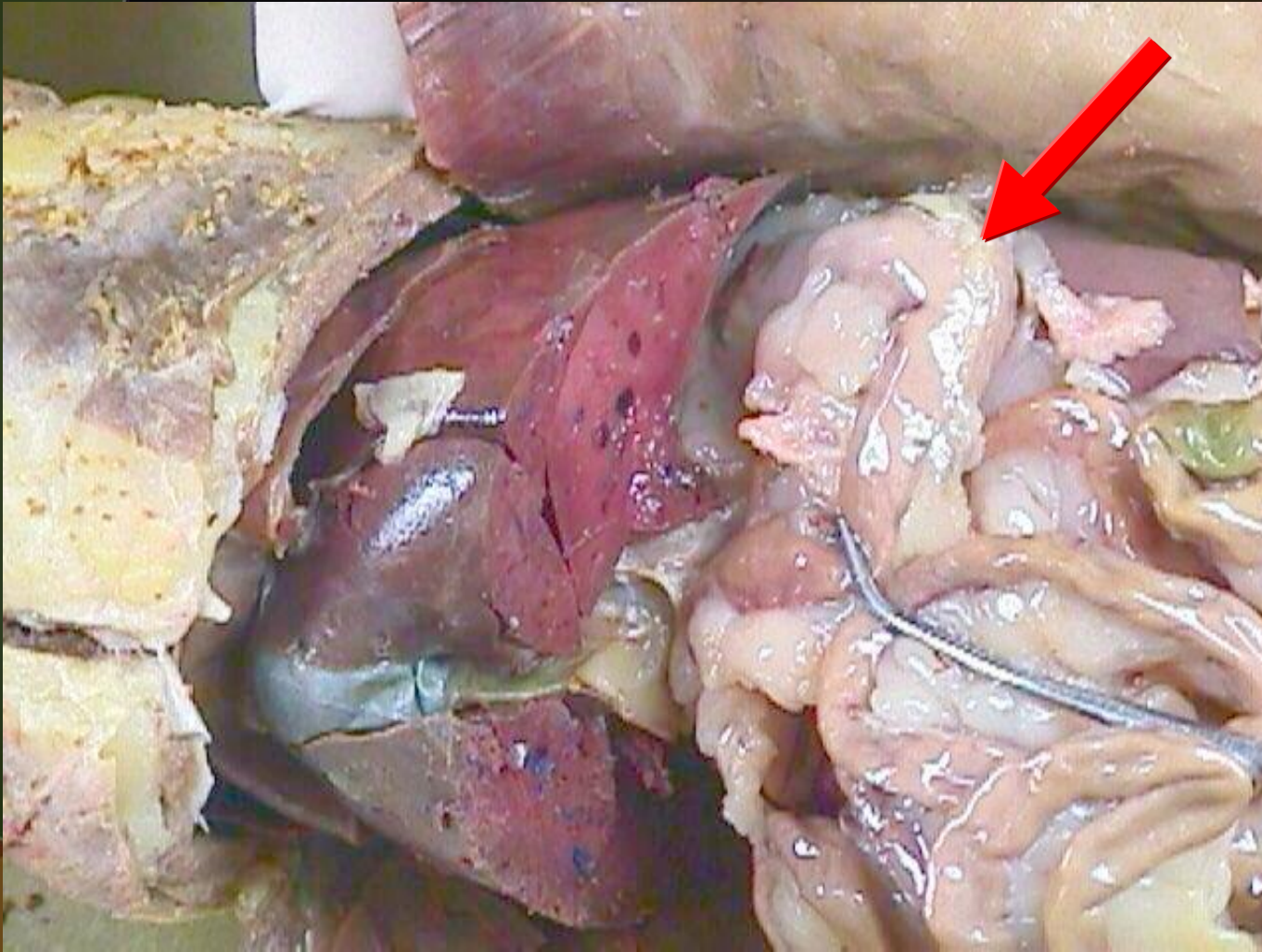
Gall bladder



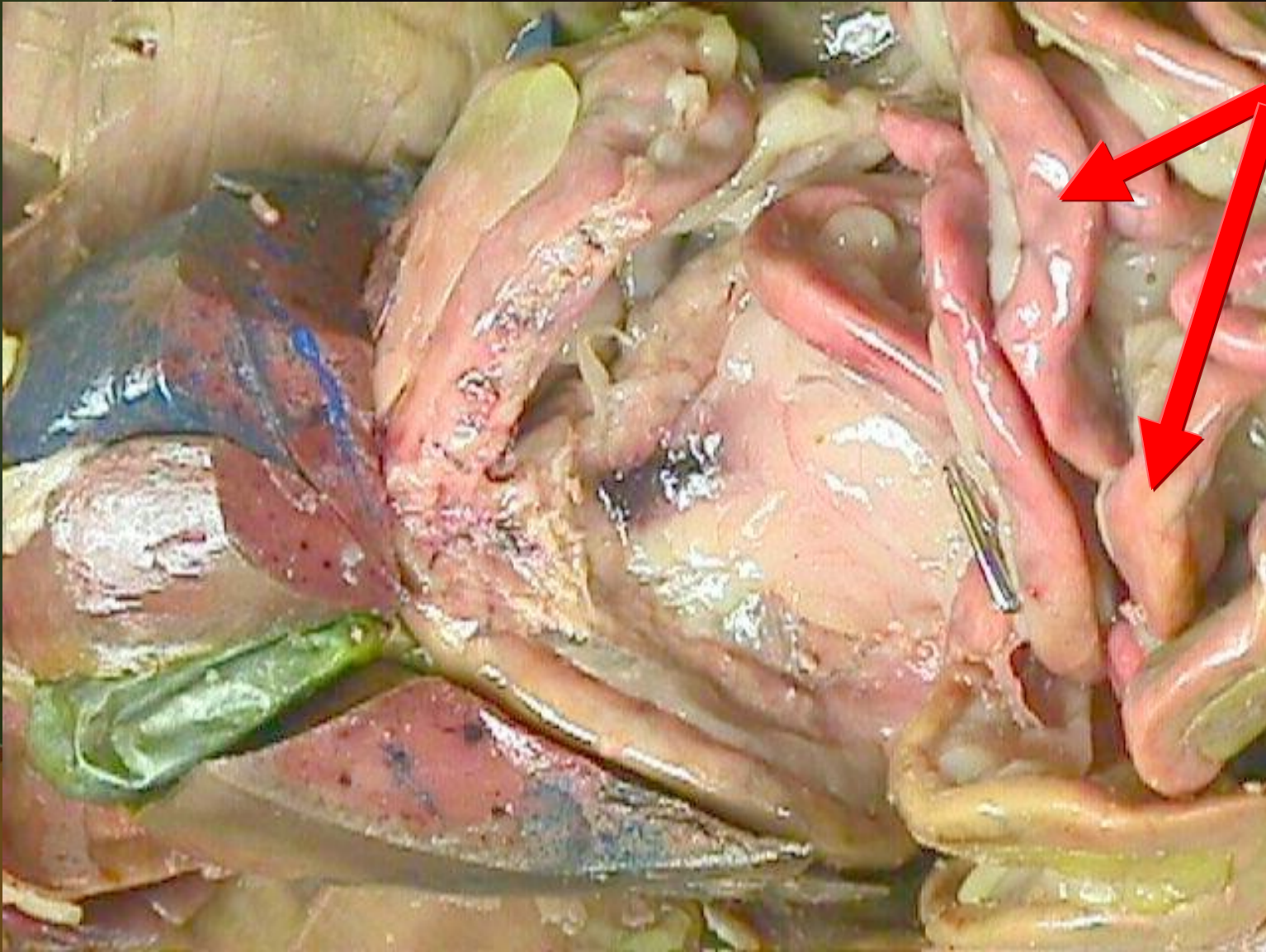
Cystic duct



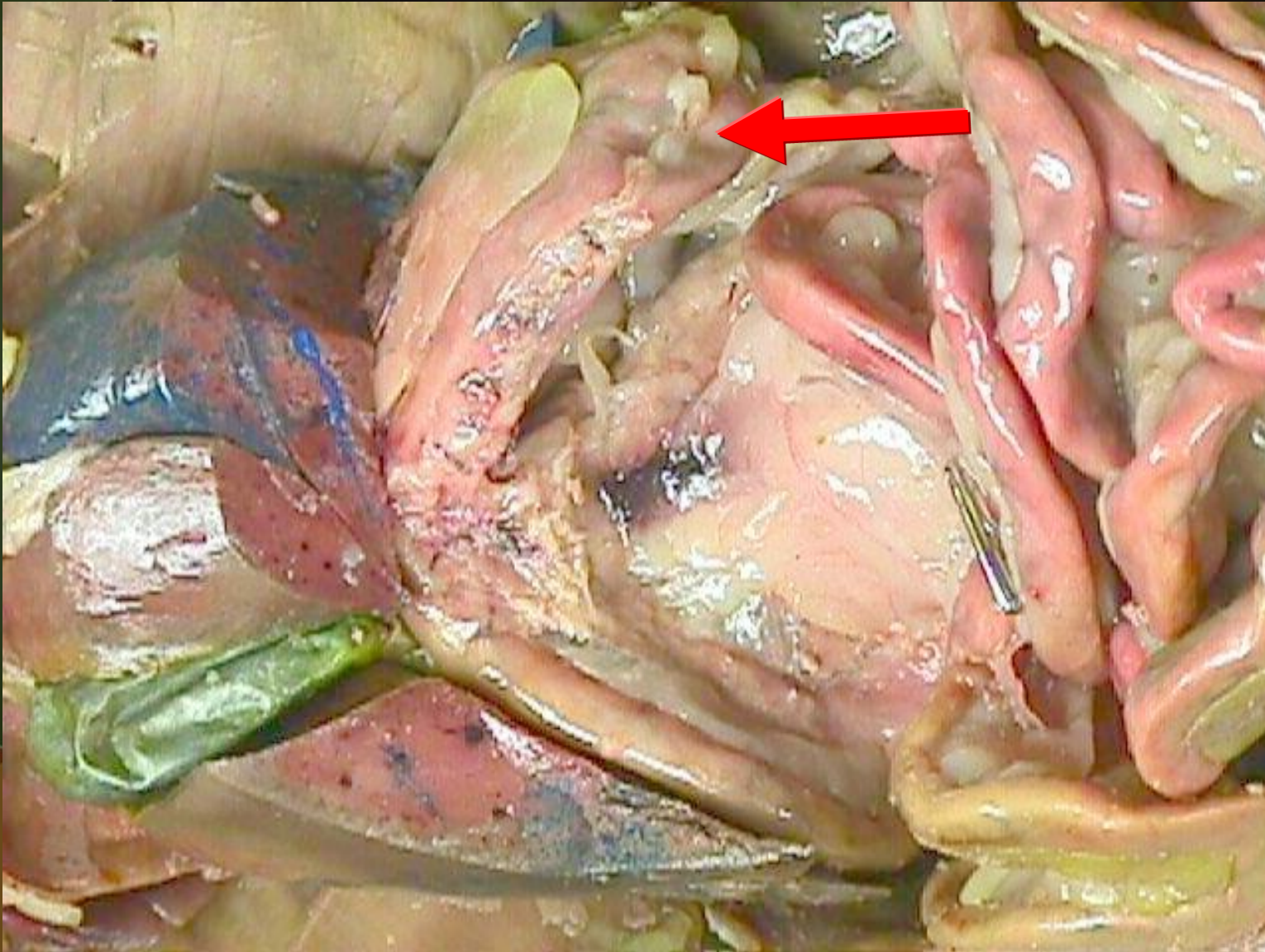
Stomach



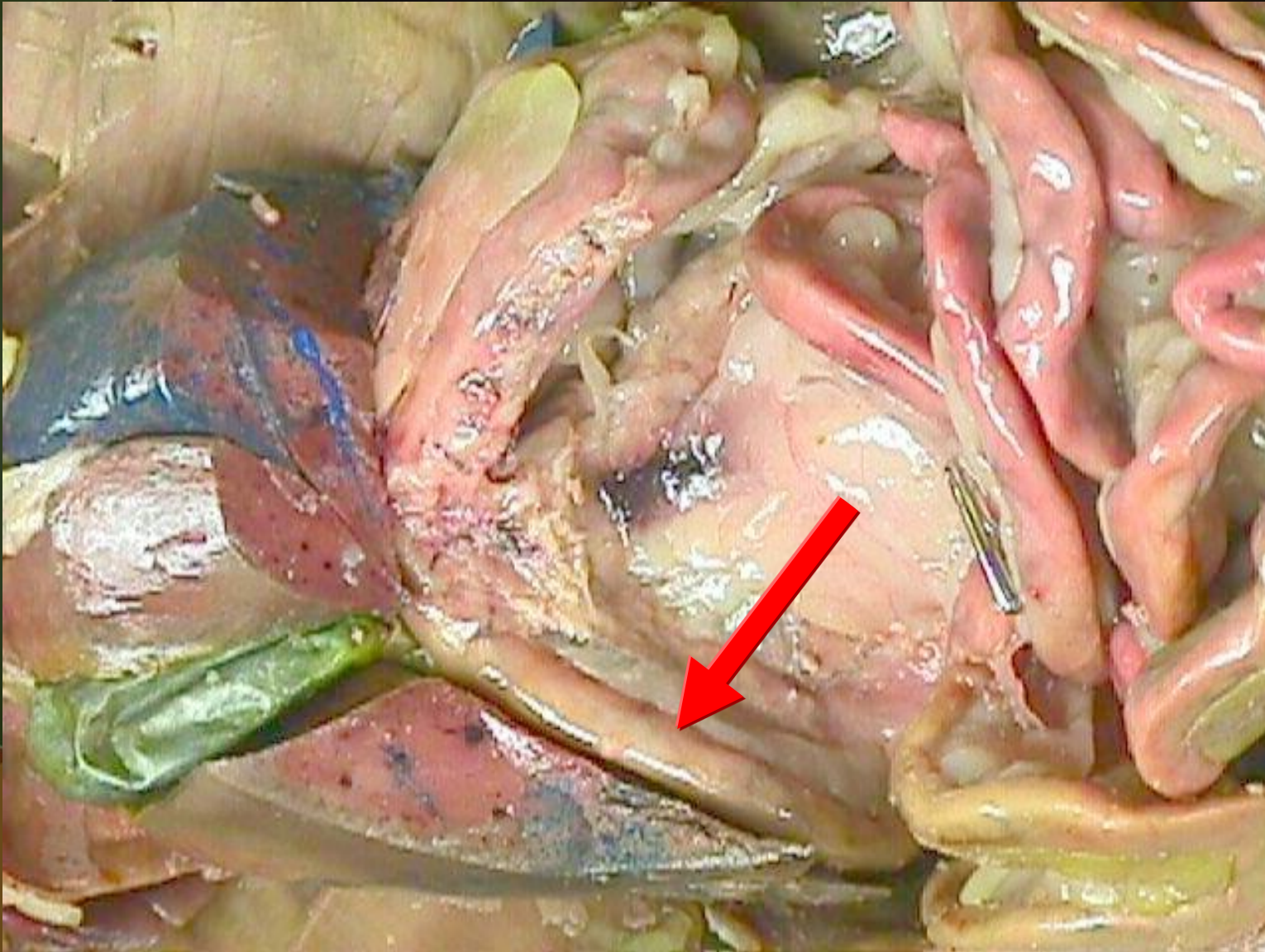
Intestines



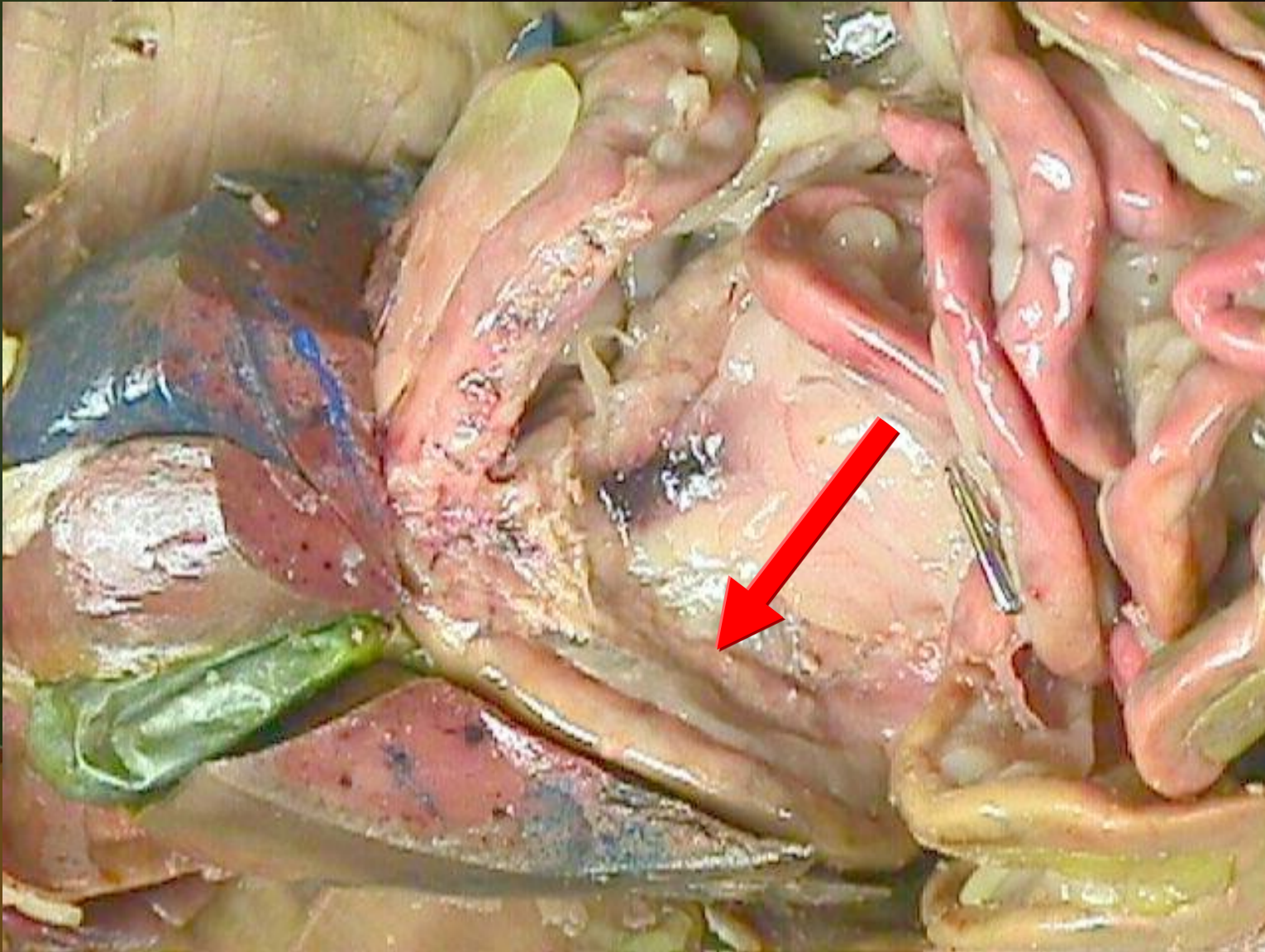
Stomach



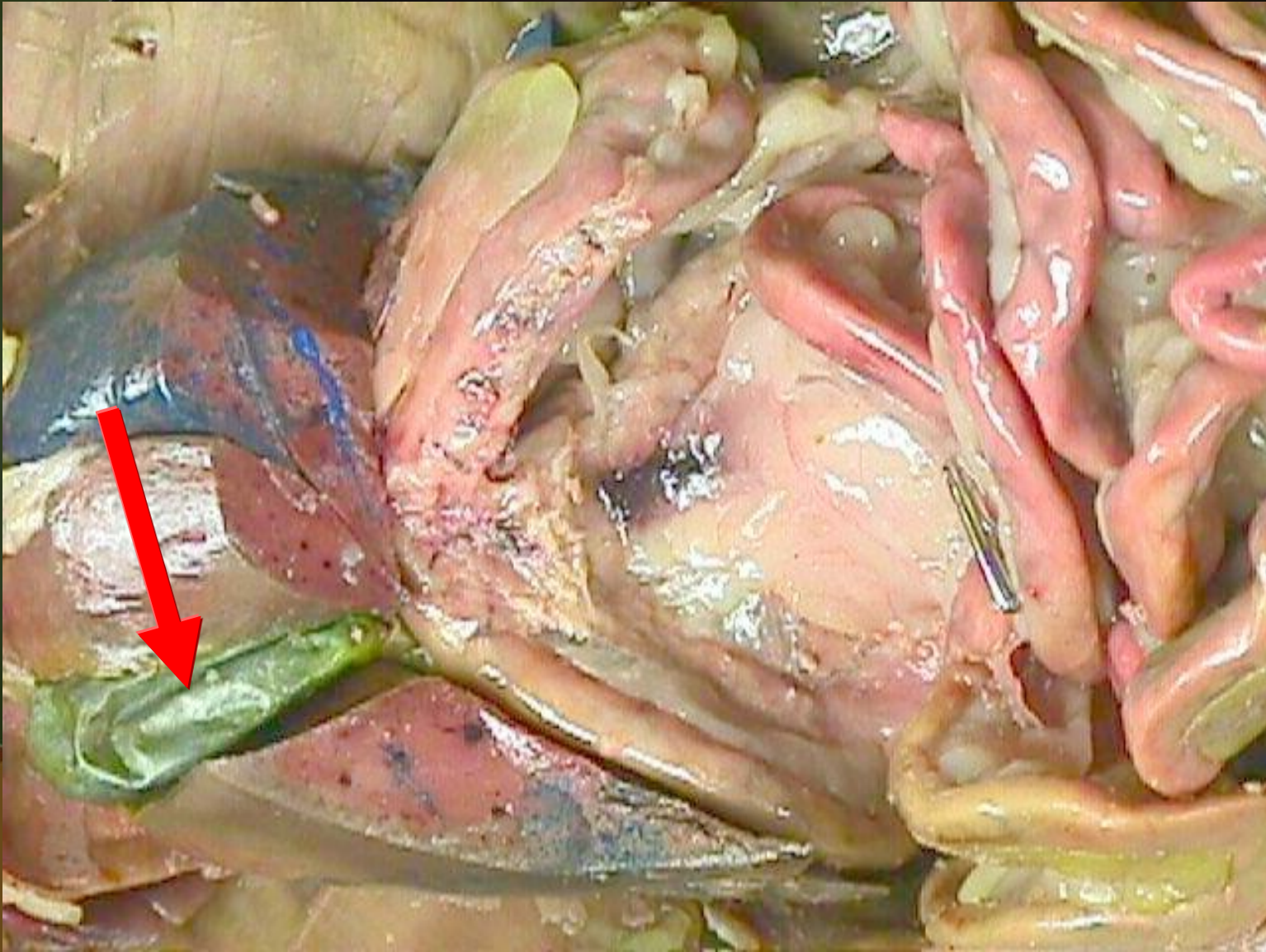
Duodenum



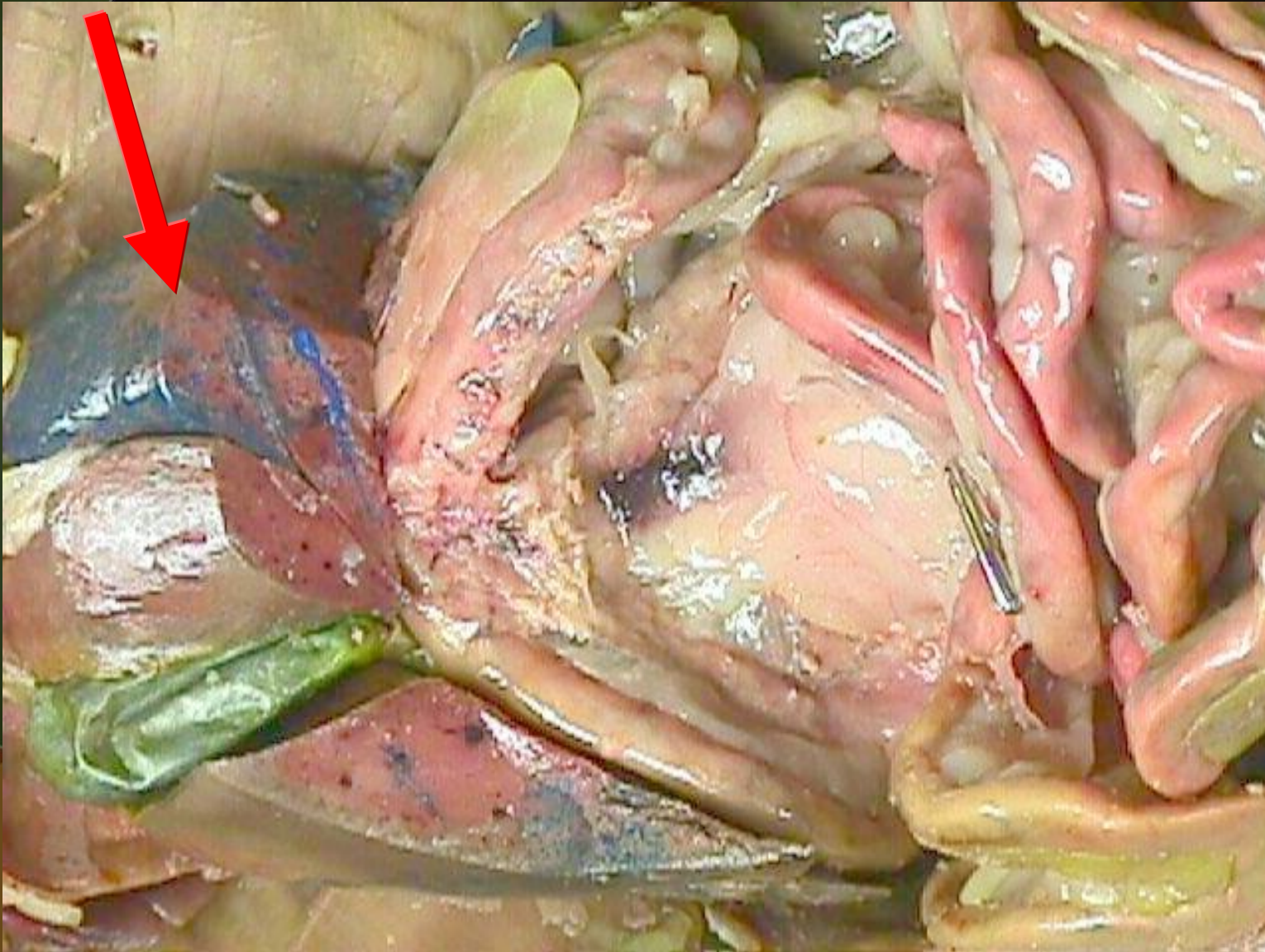
Pancreas



Gall bladder



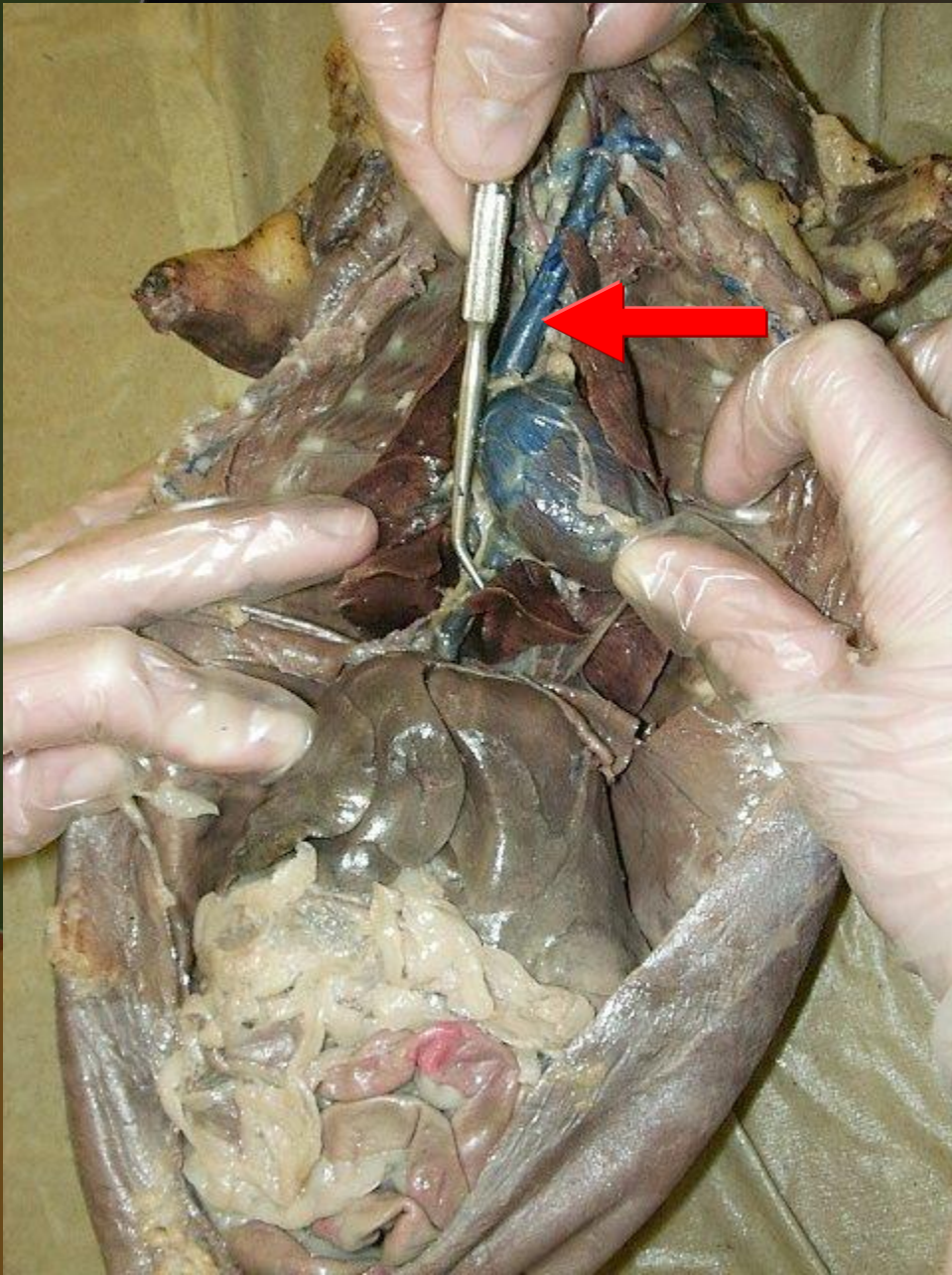Liver



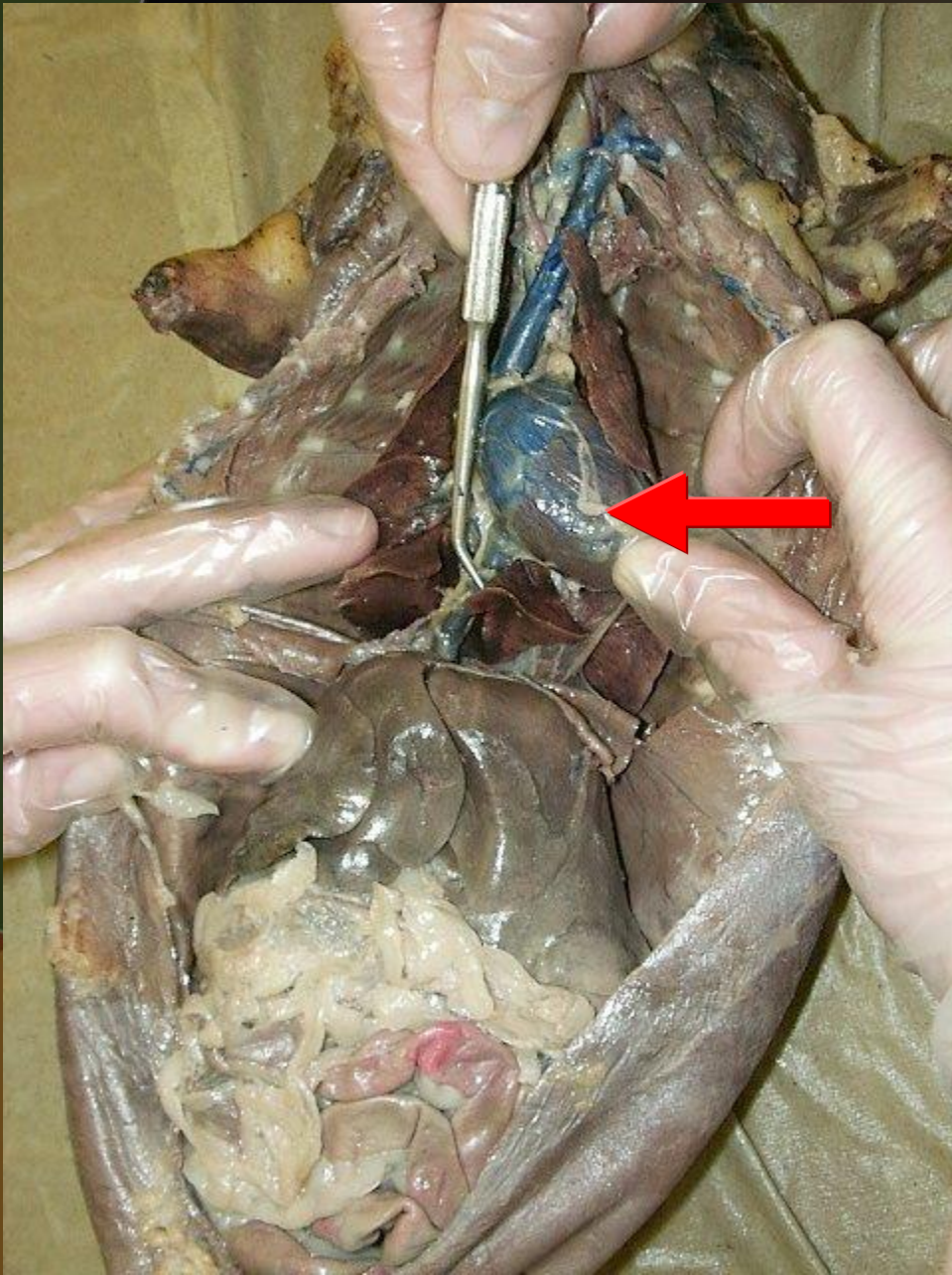
Heart



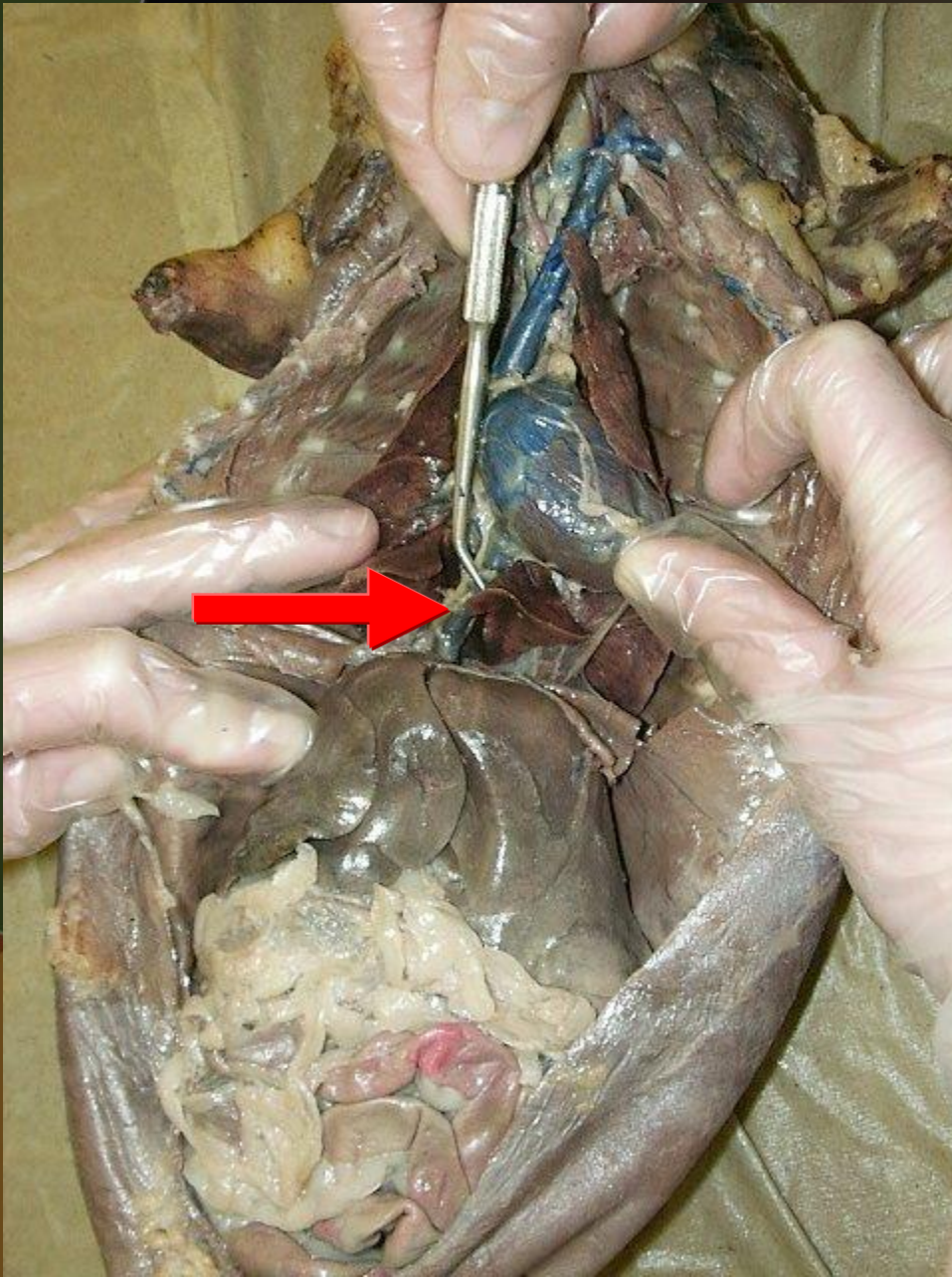Precava



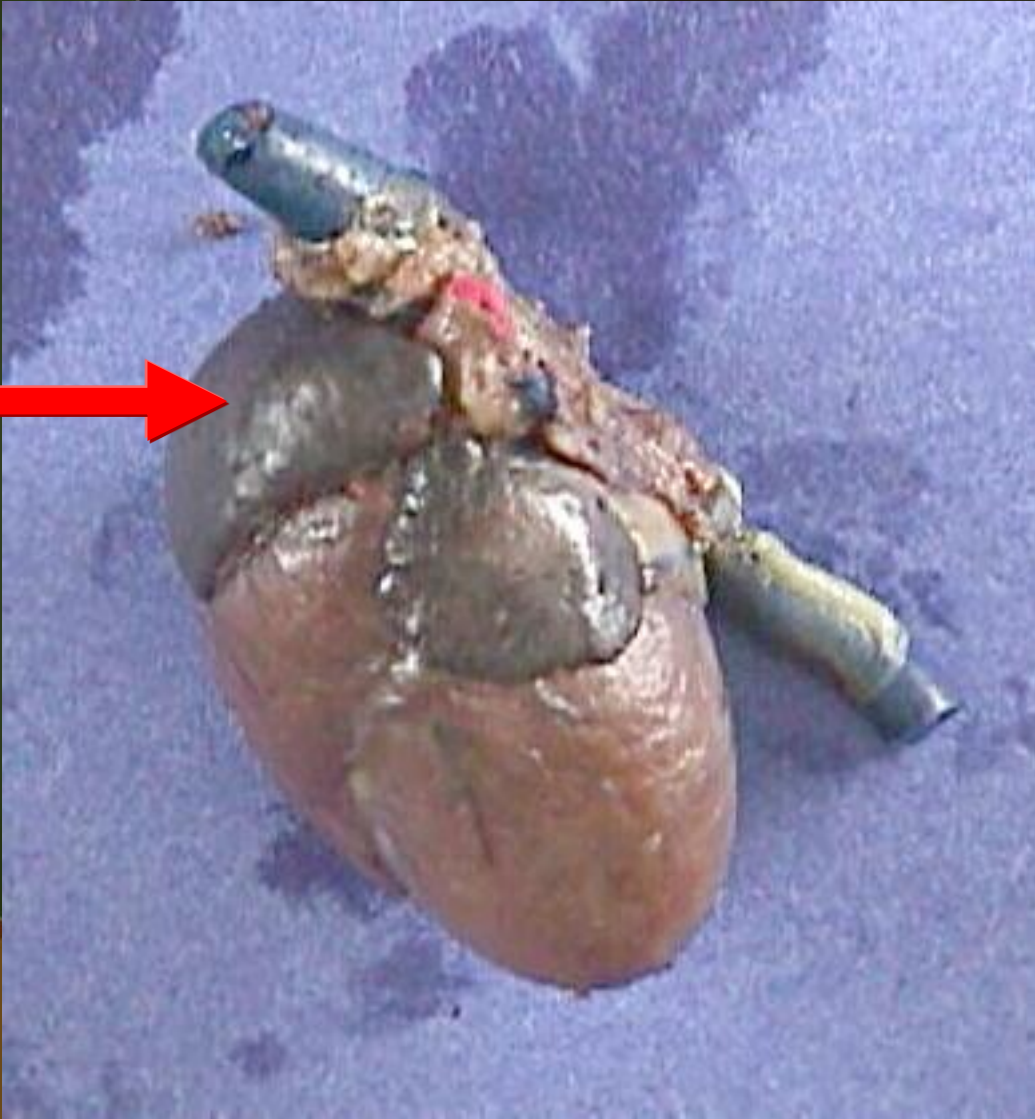
Heart



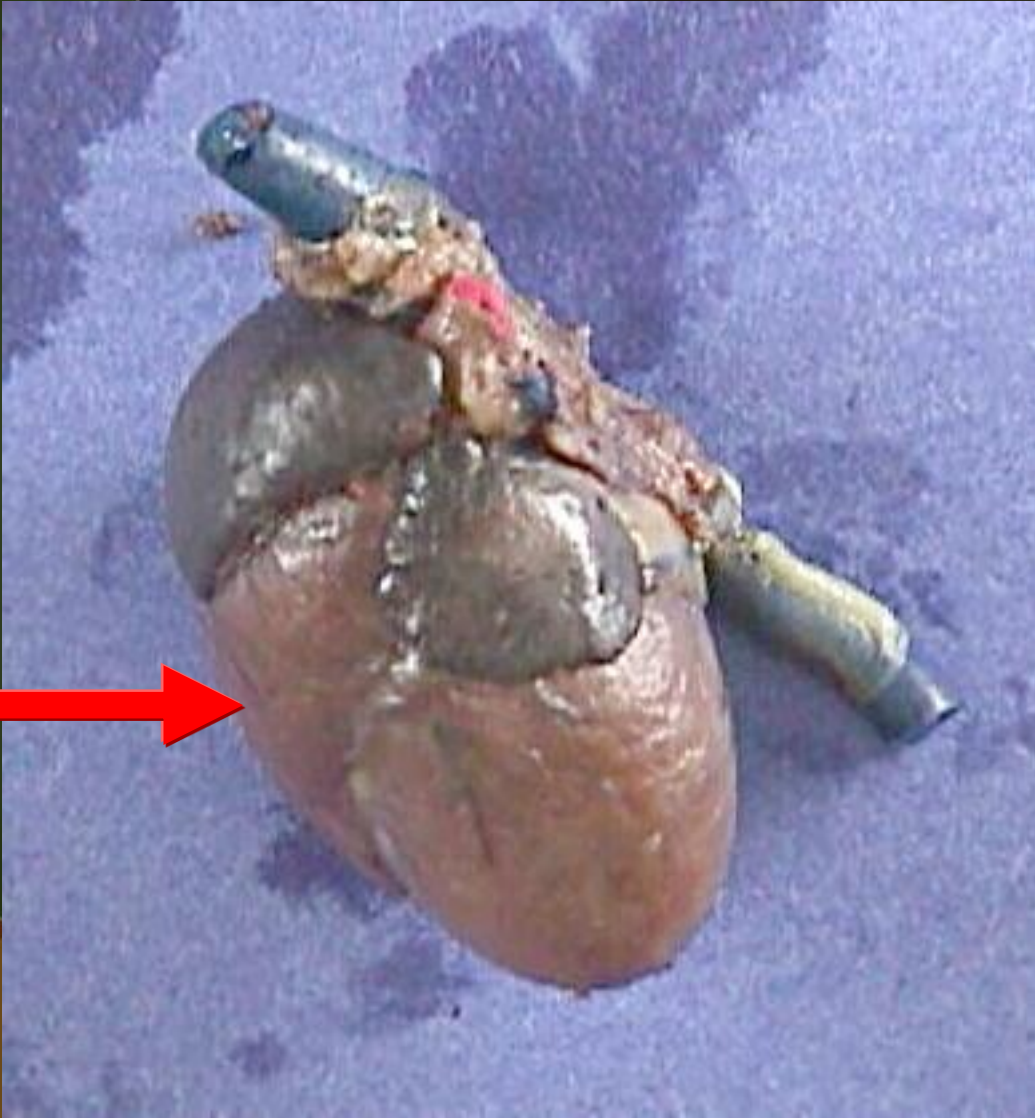
Postcava



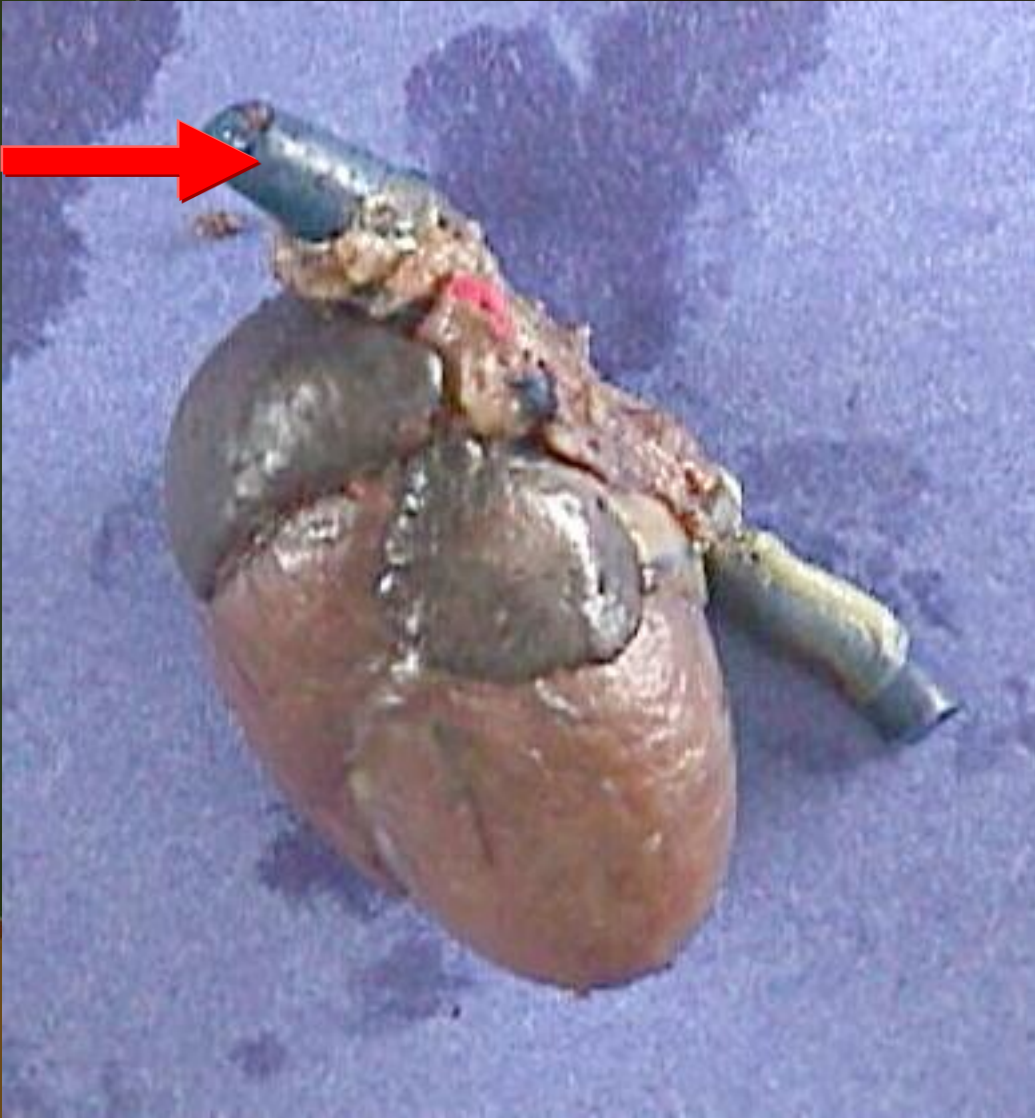
Right atrium



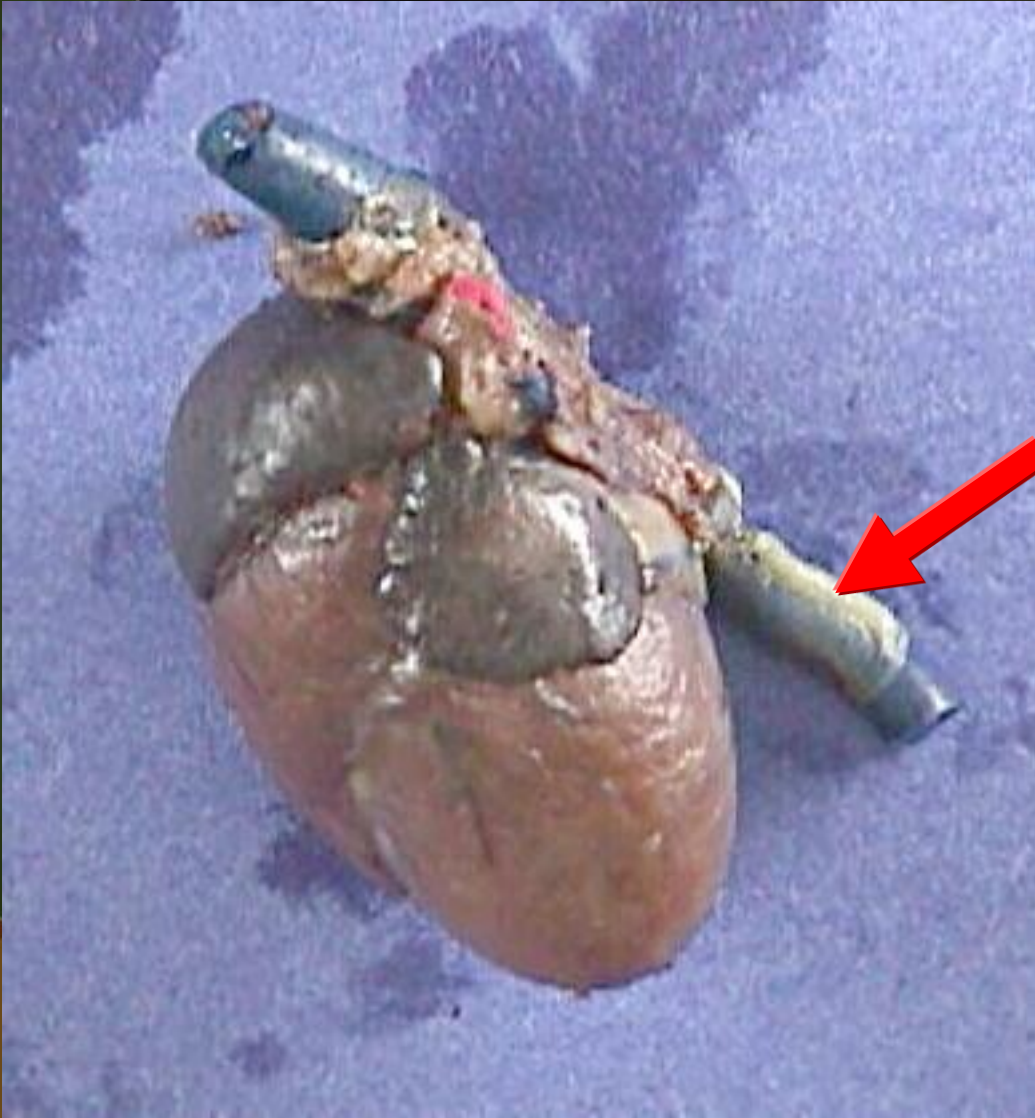
Right ventricle



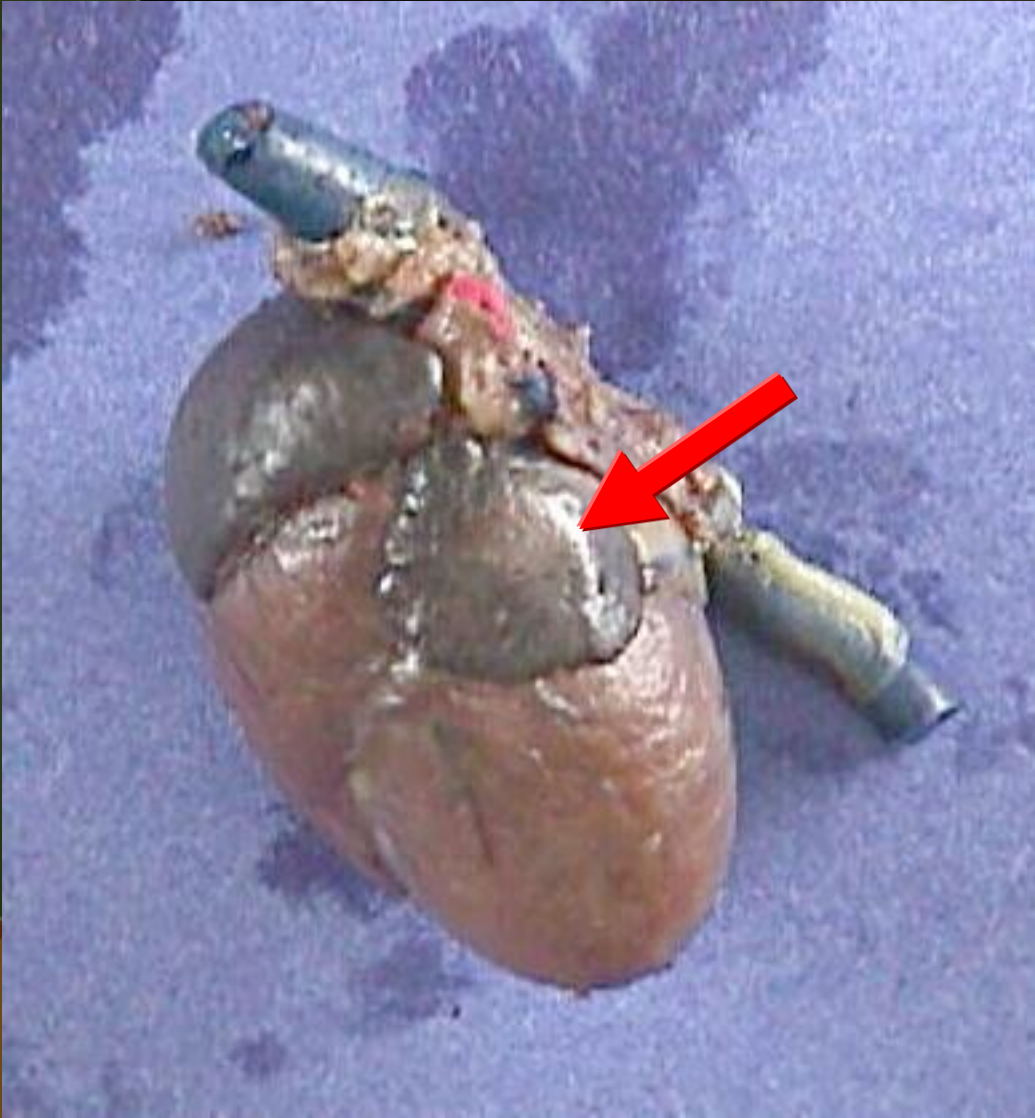
Precava



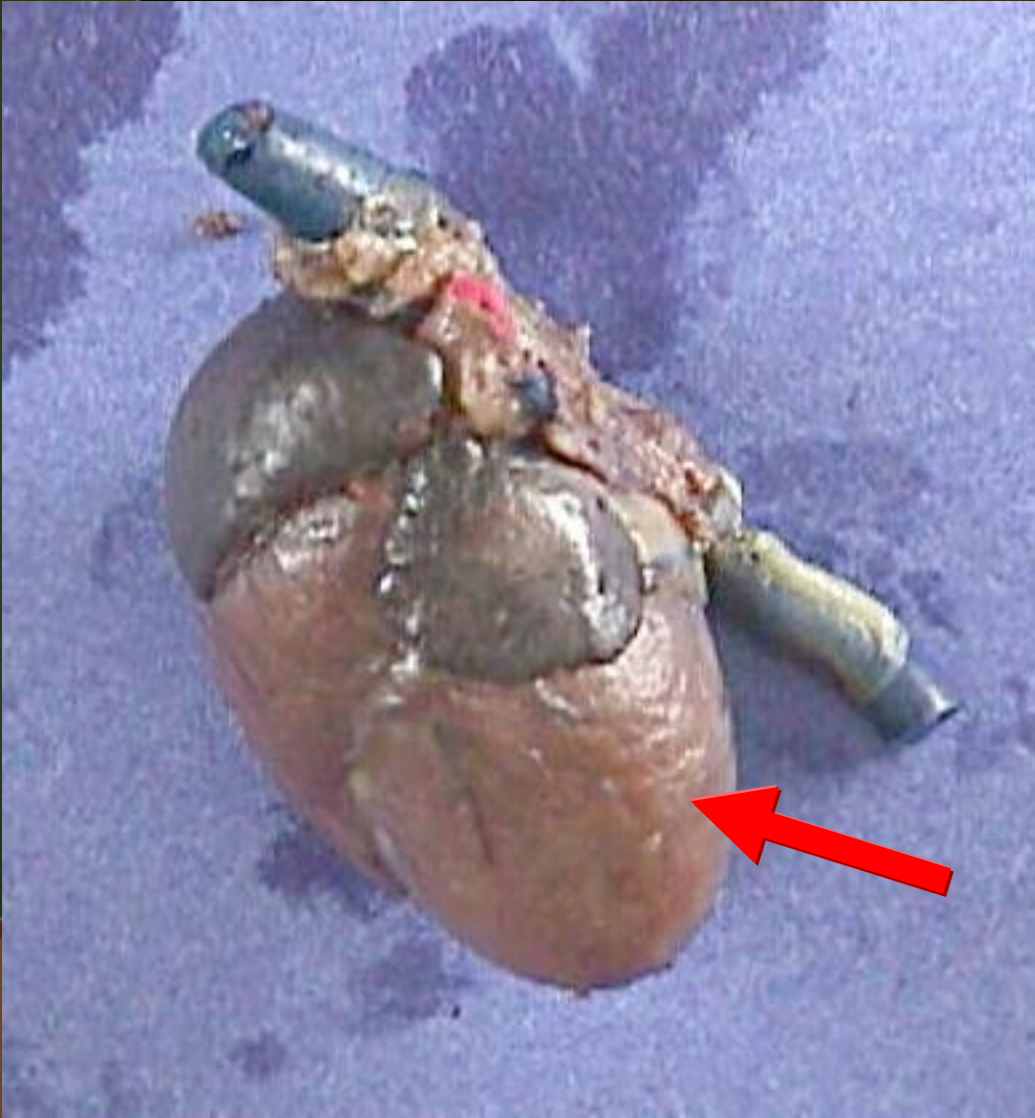
Postcava



Left atrium



Left ventricle



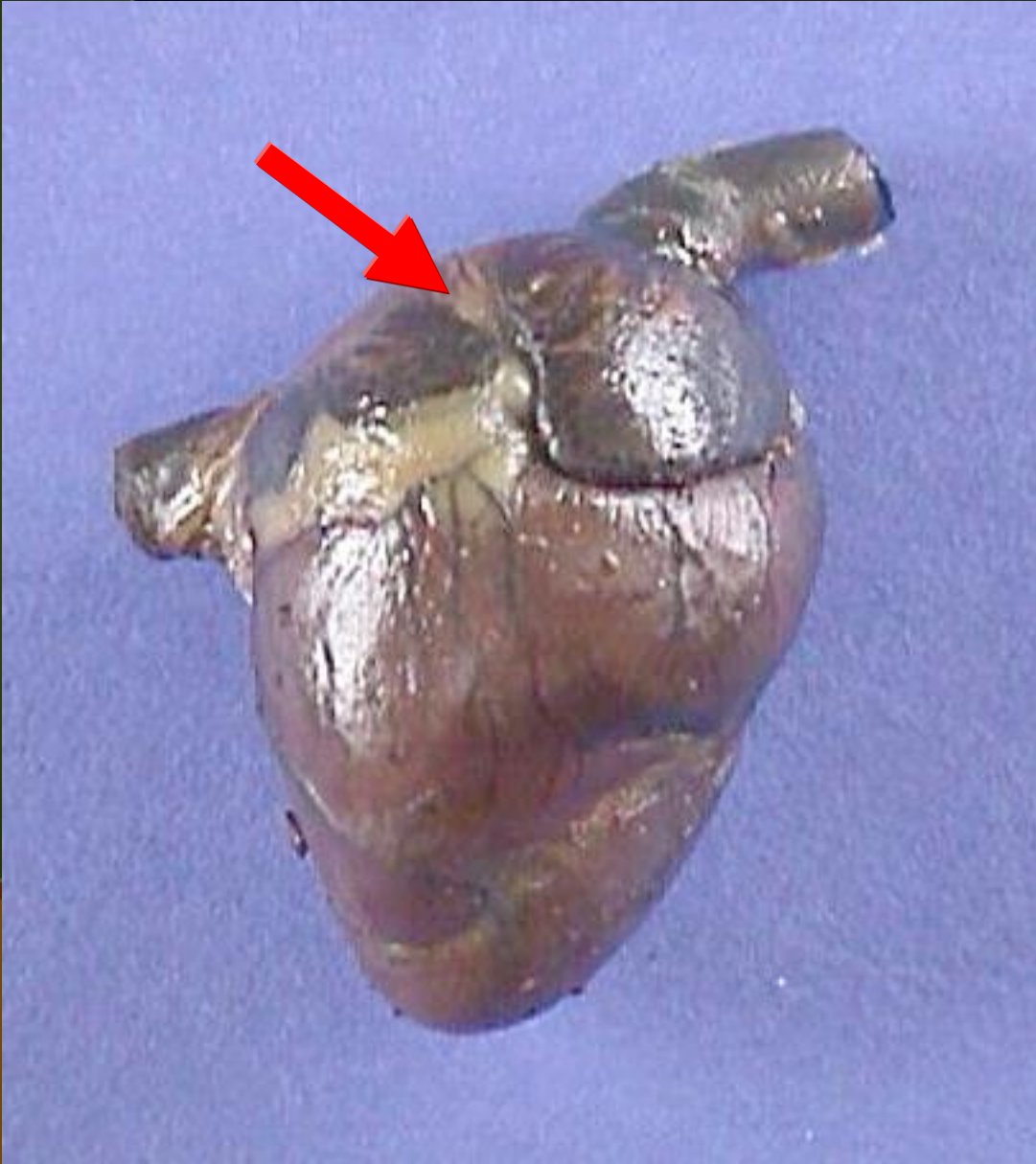Left ventricle



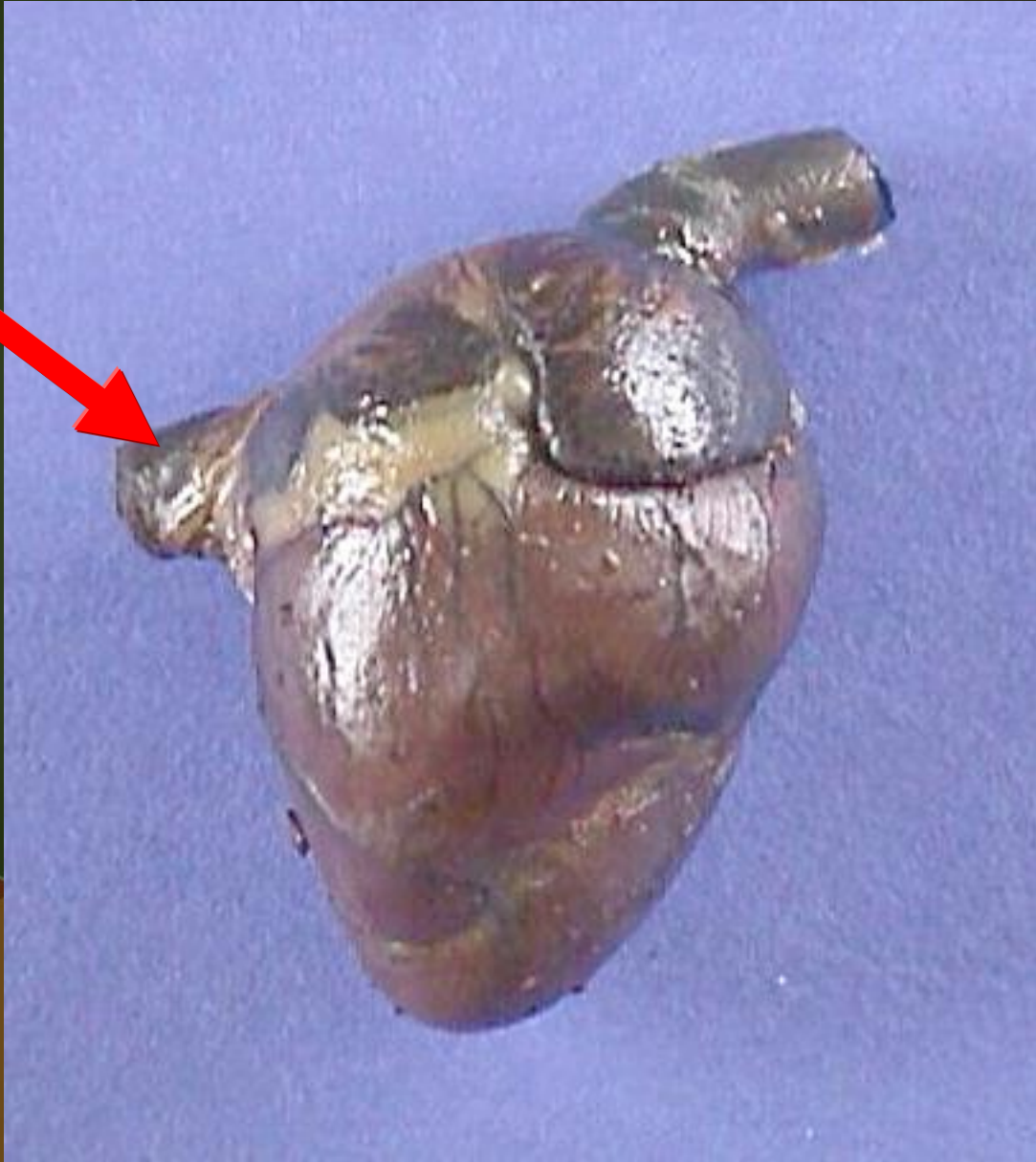Precava



Right atrium



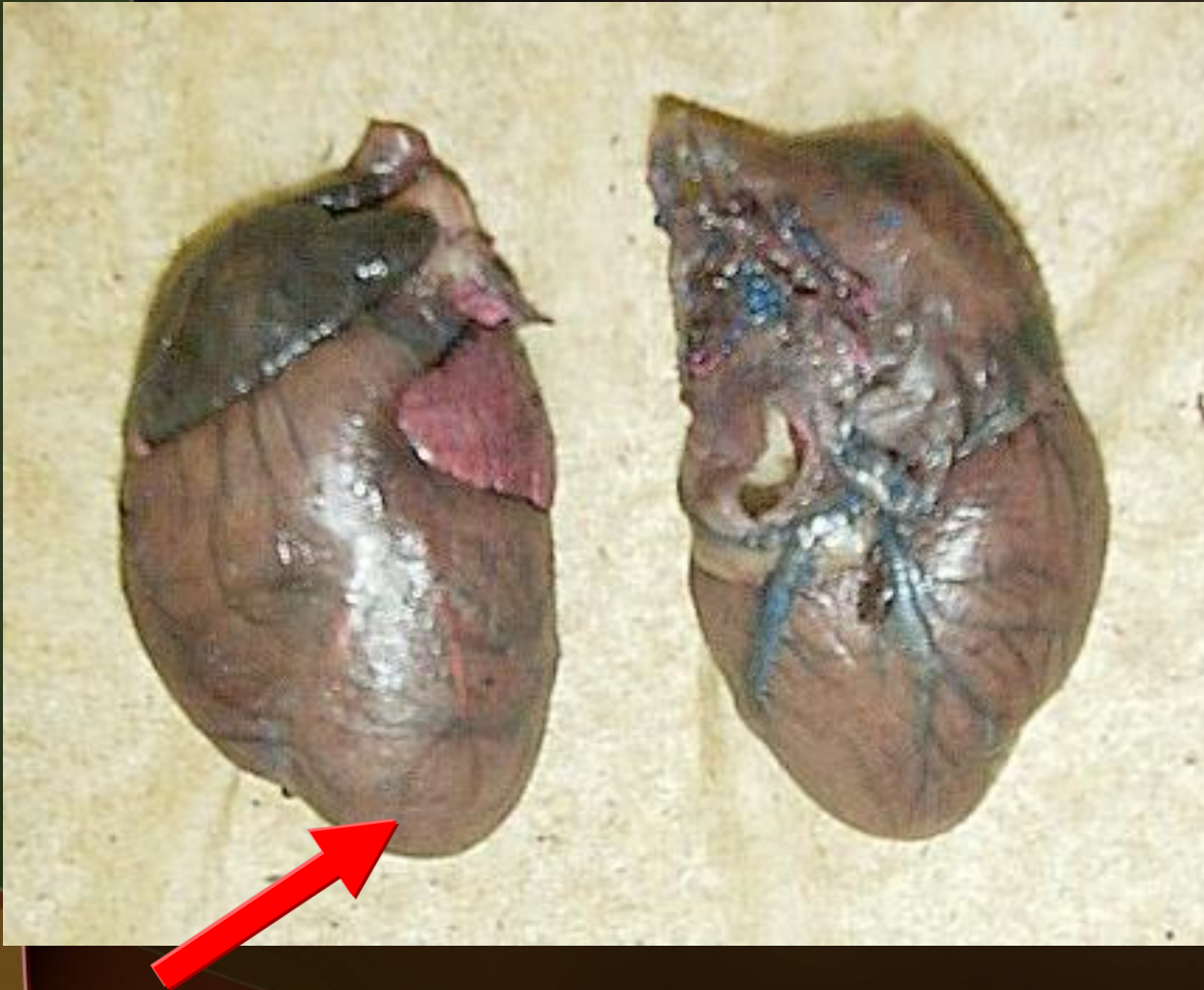
Postcava



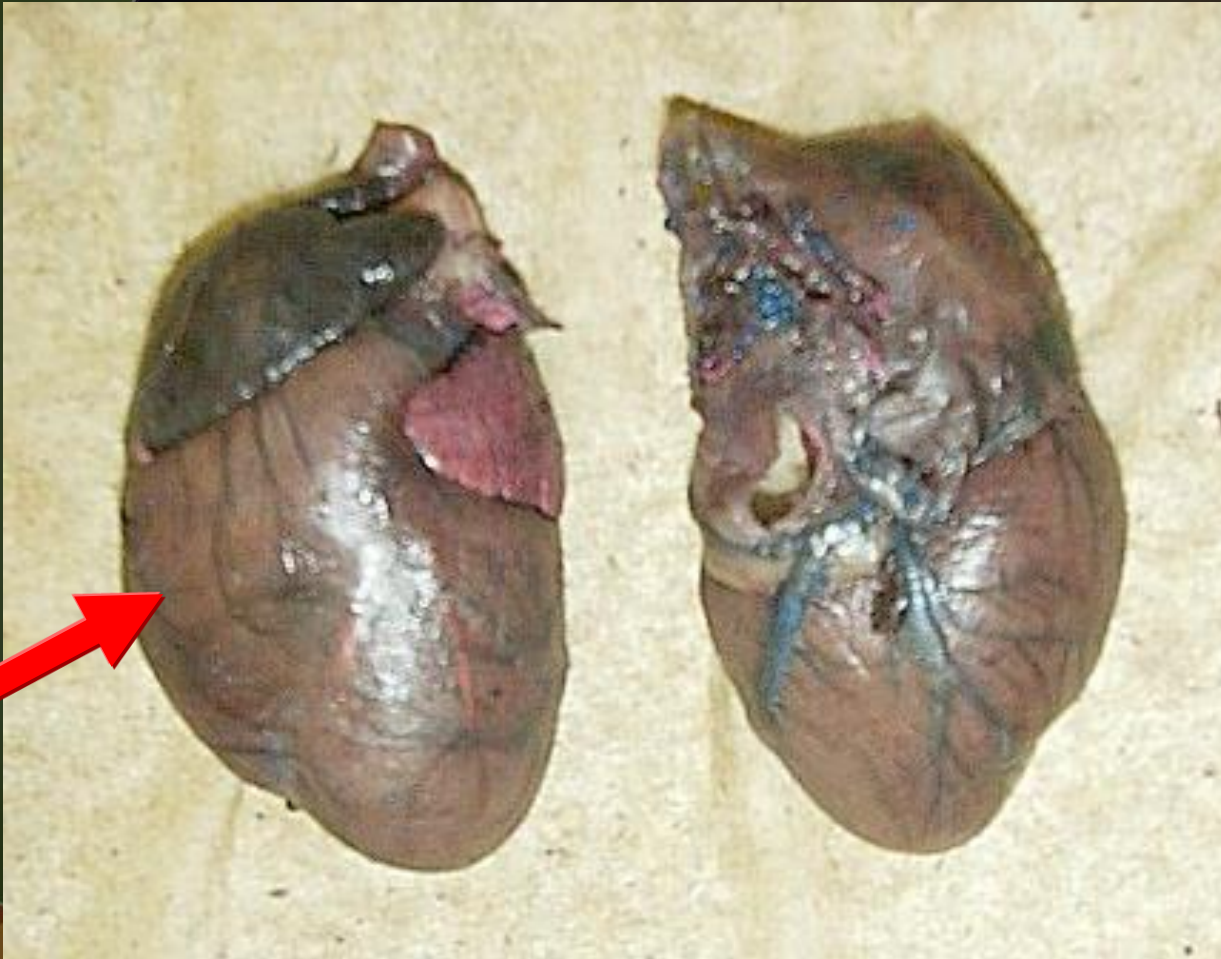
Right ventricle



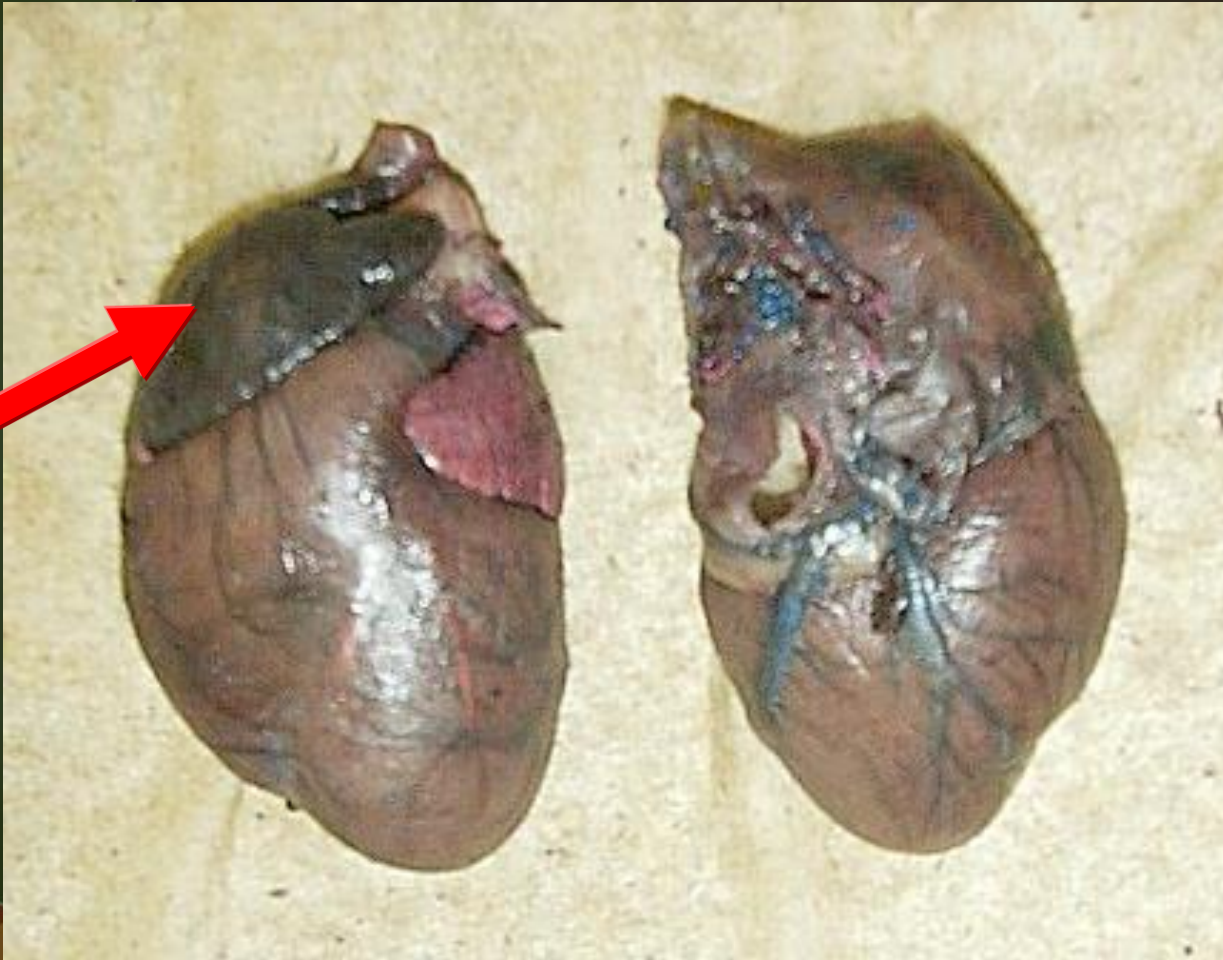
Left ventricle



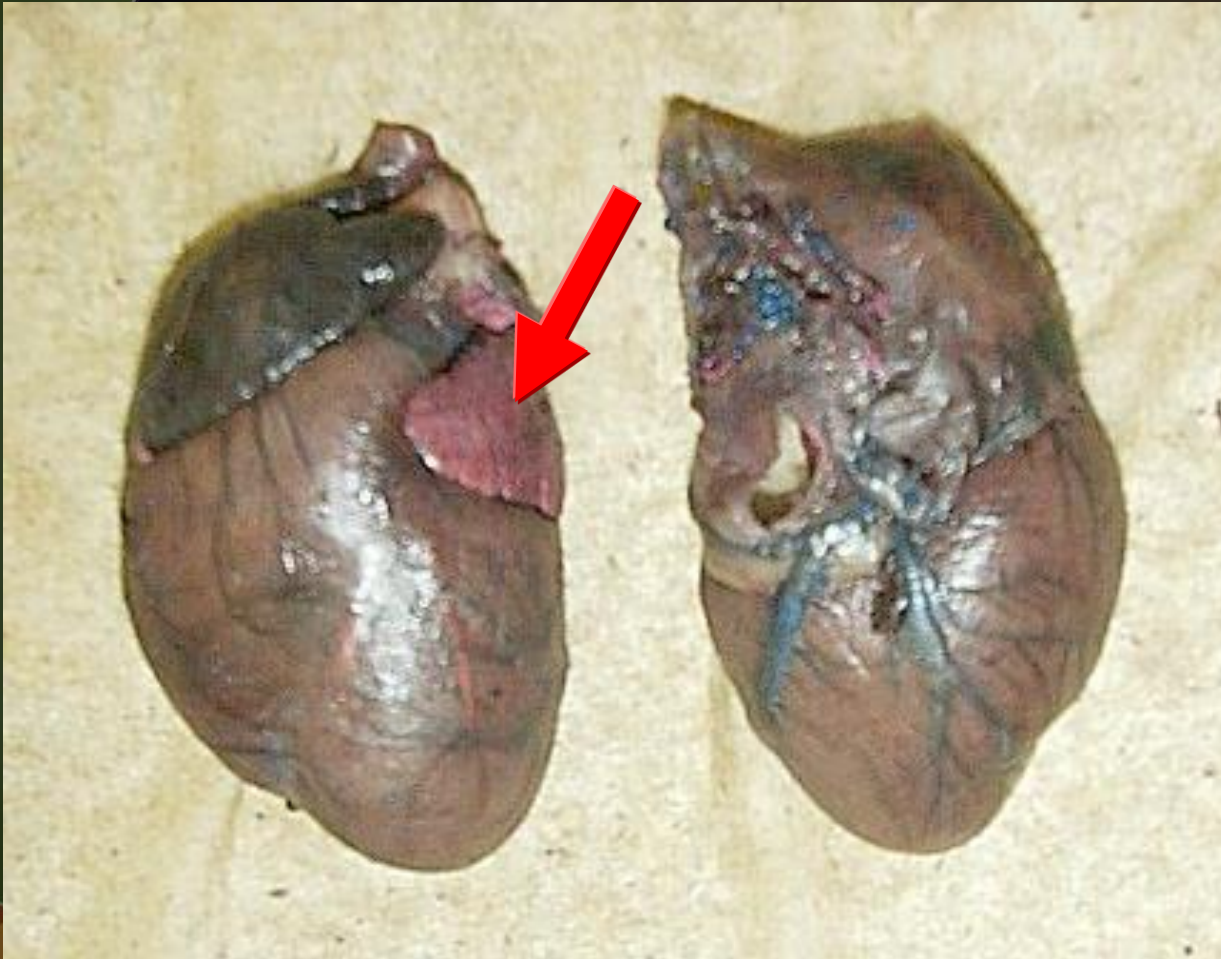
Right ventricle



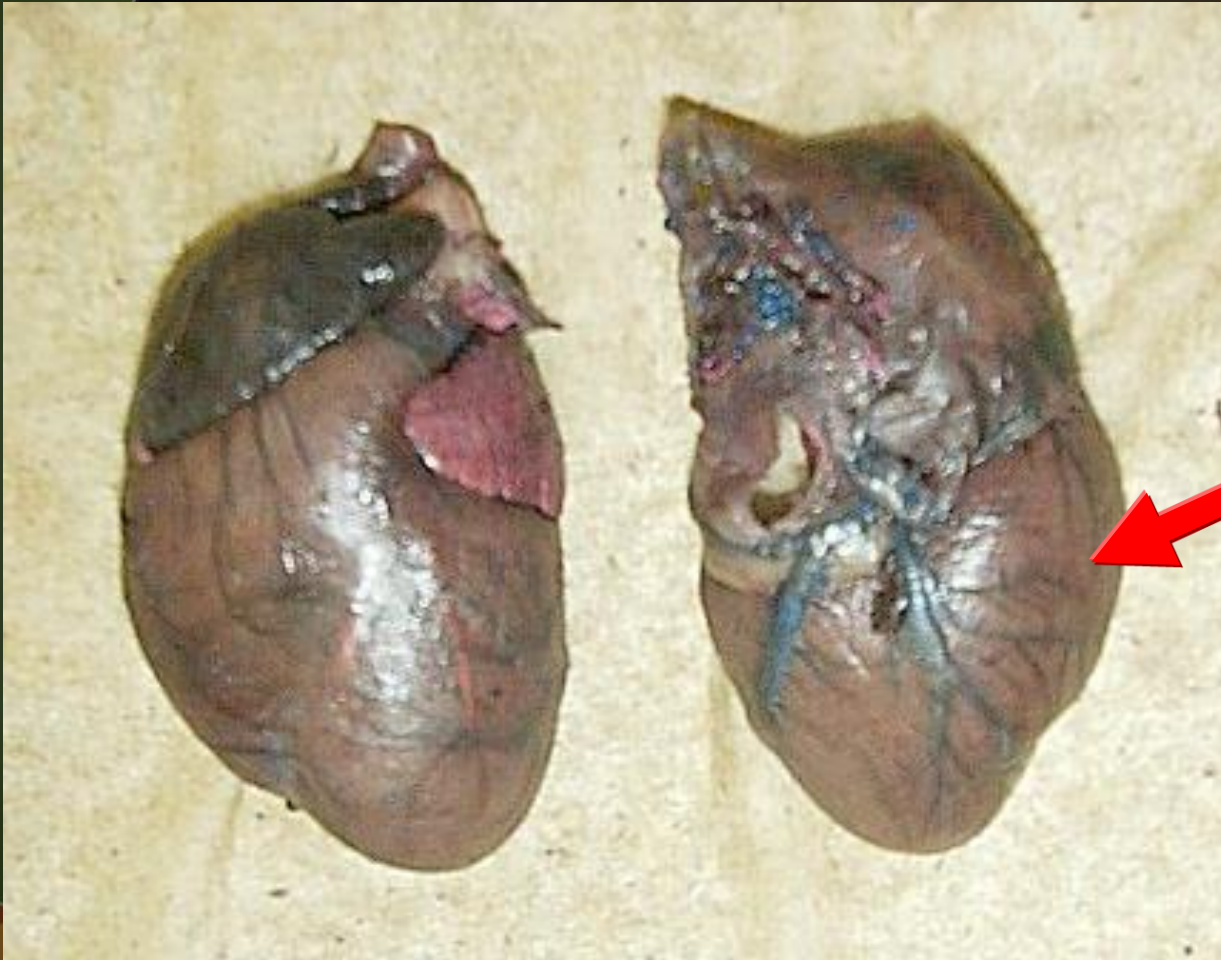Right atrium



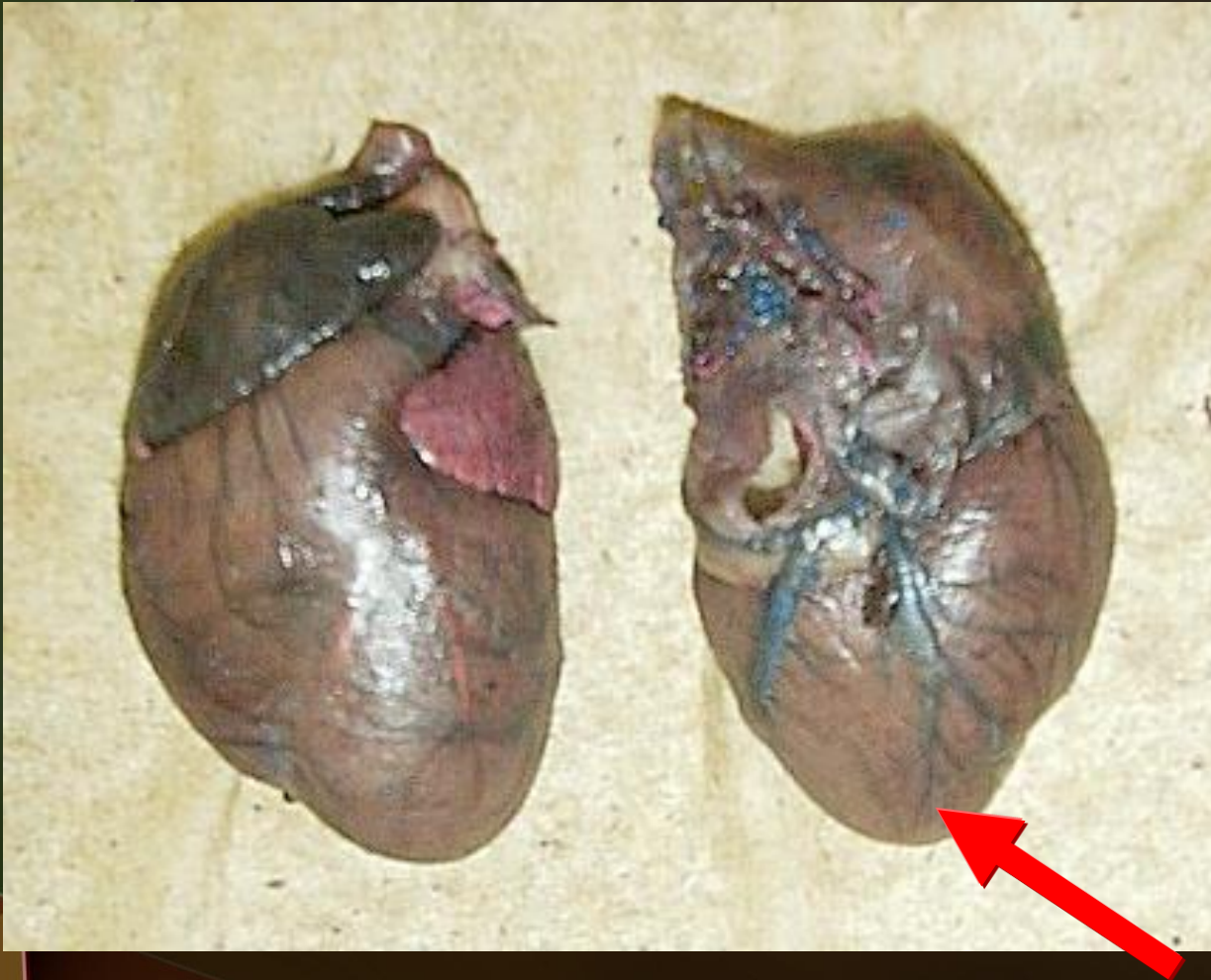
Left atrium



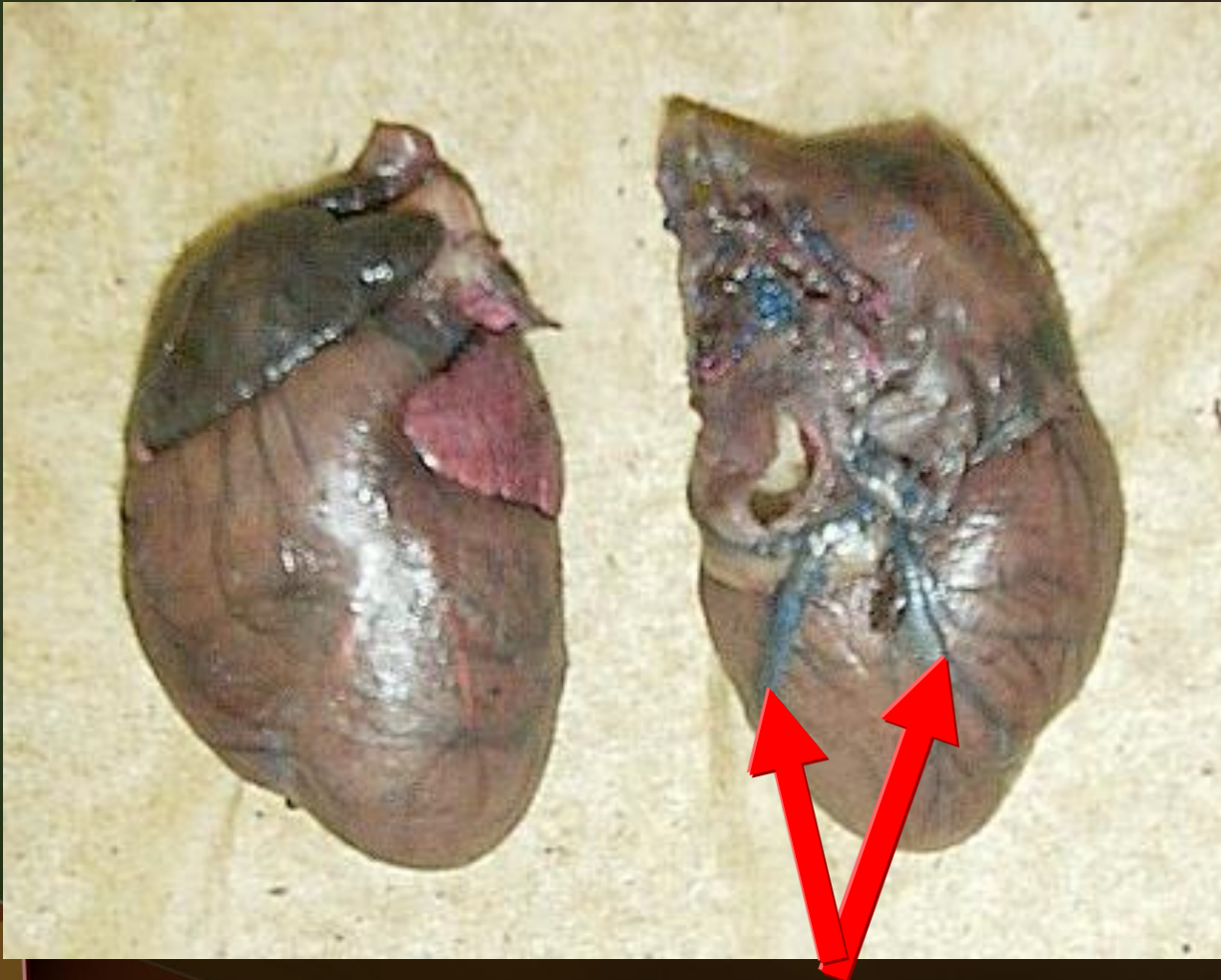
Right ventricle



Left ventricle

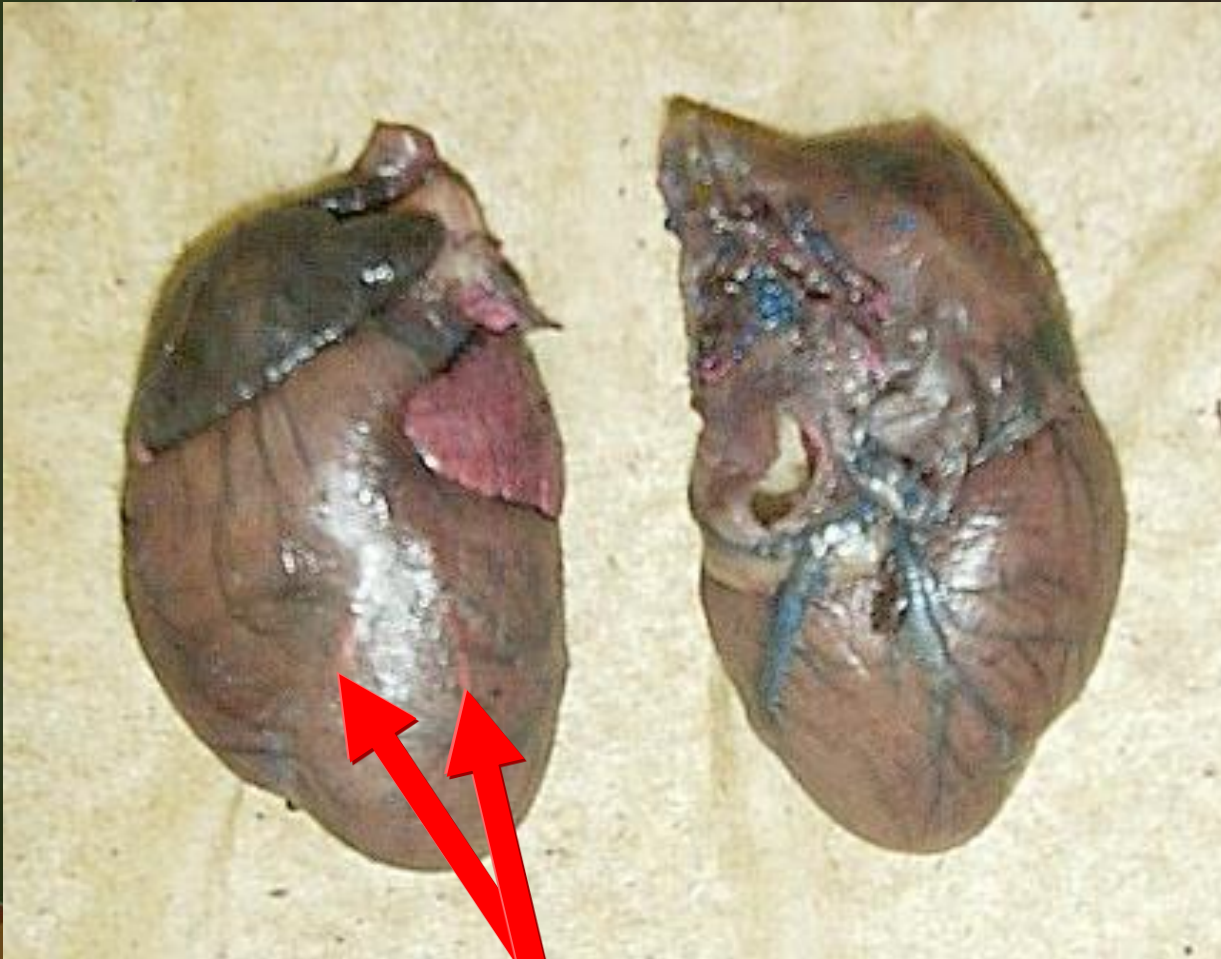


Cardiac veins



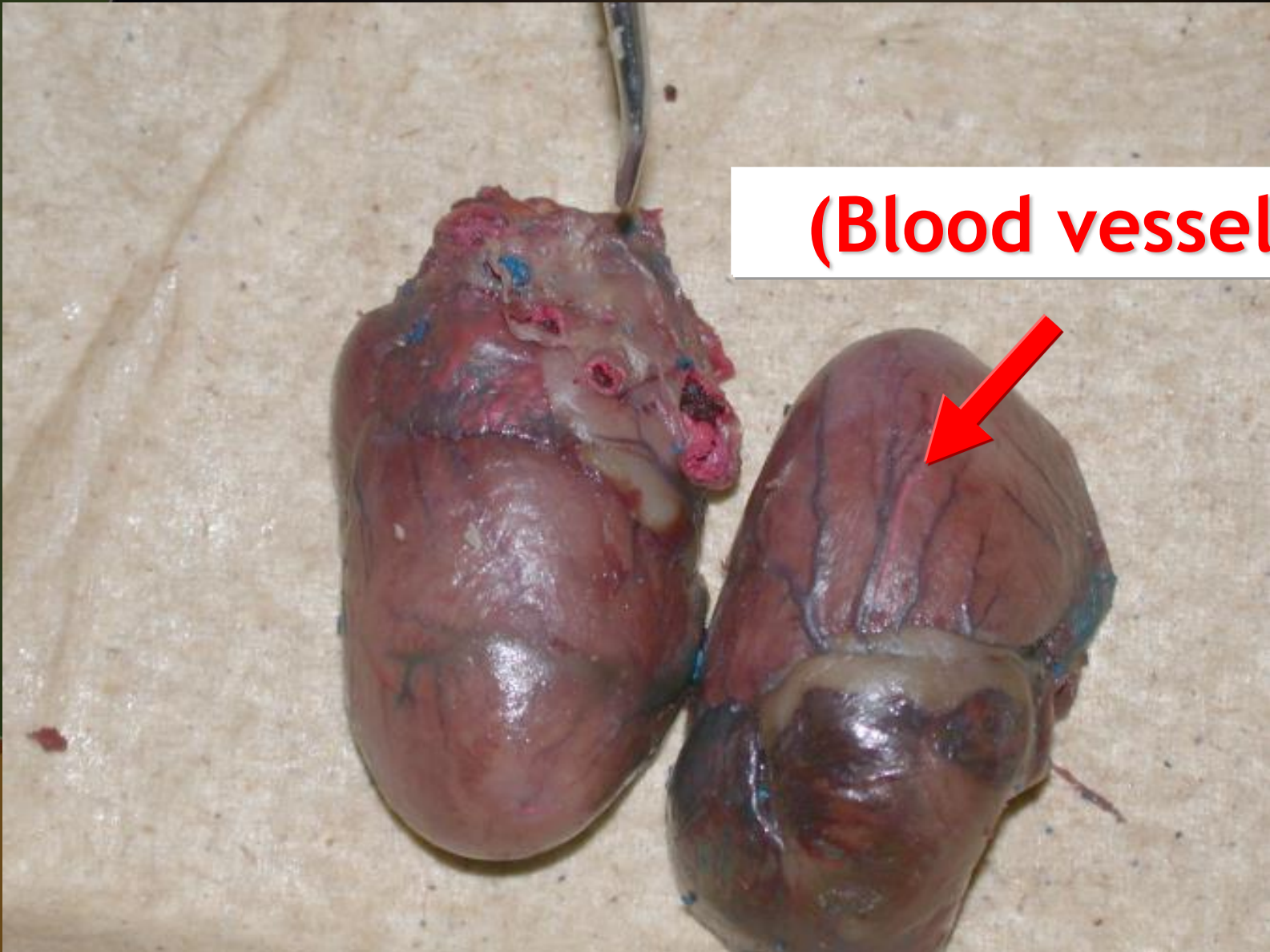
(Blood vessels)

Coronary arteries



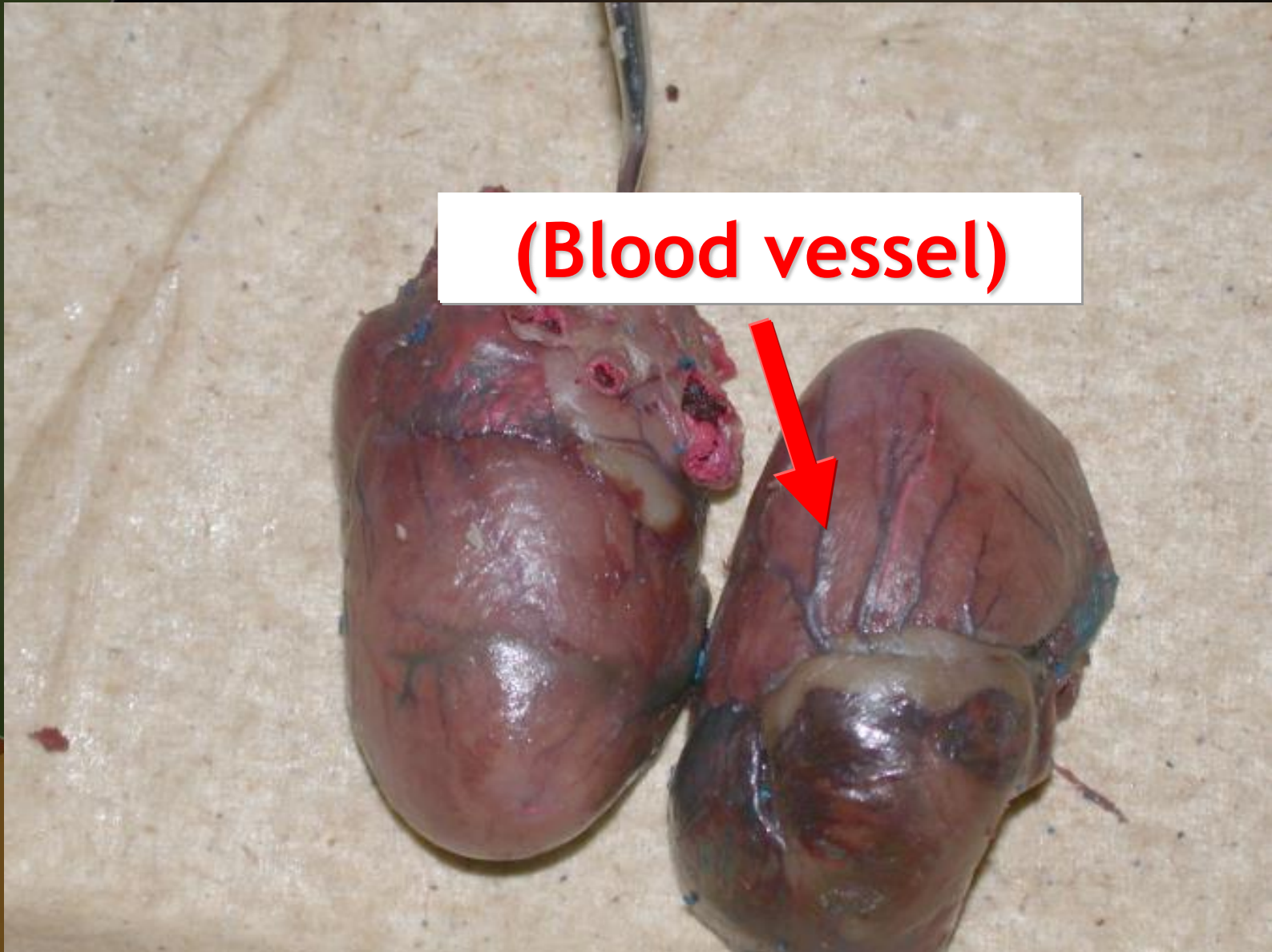
(Blood vessels)

Coronary artery

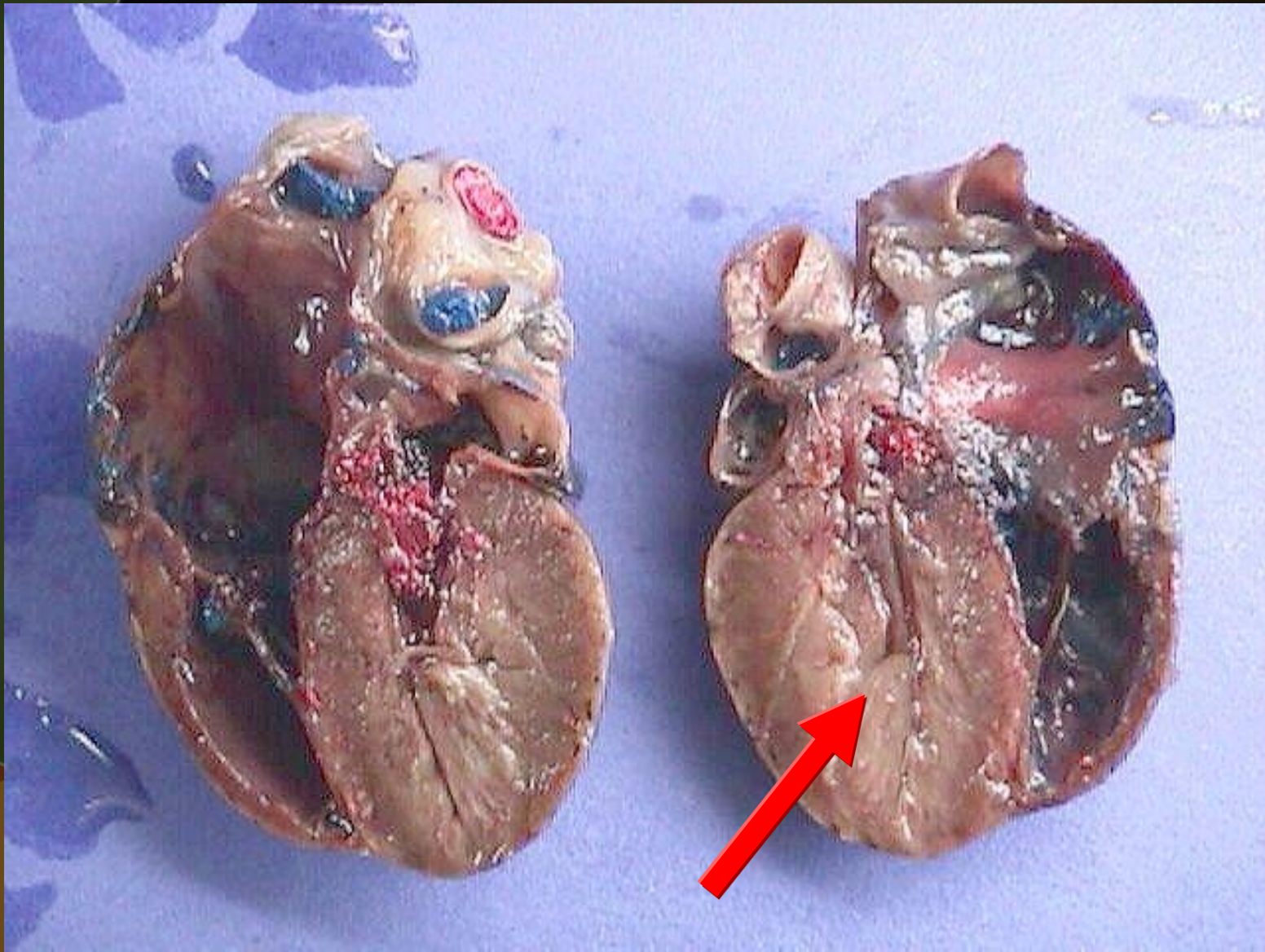


(Blood vessel)

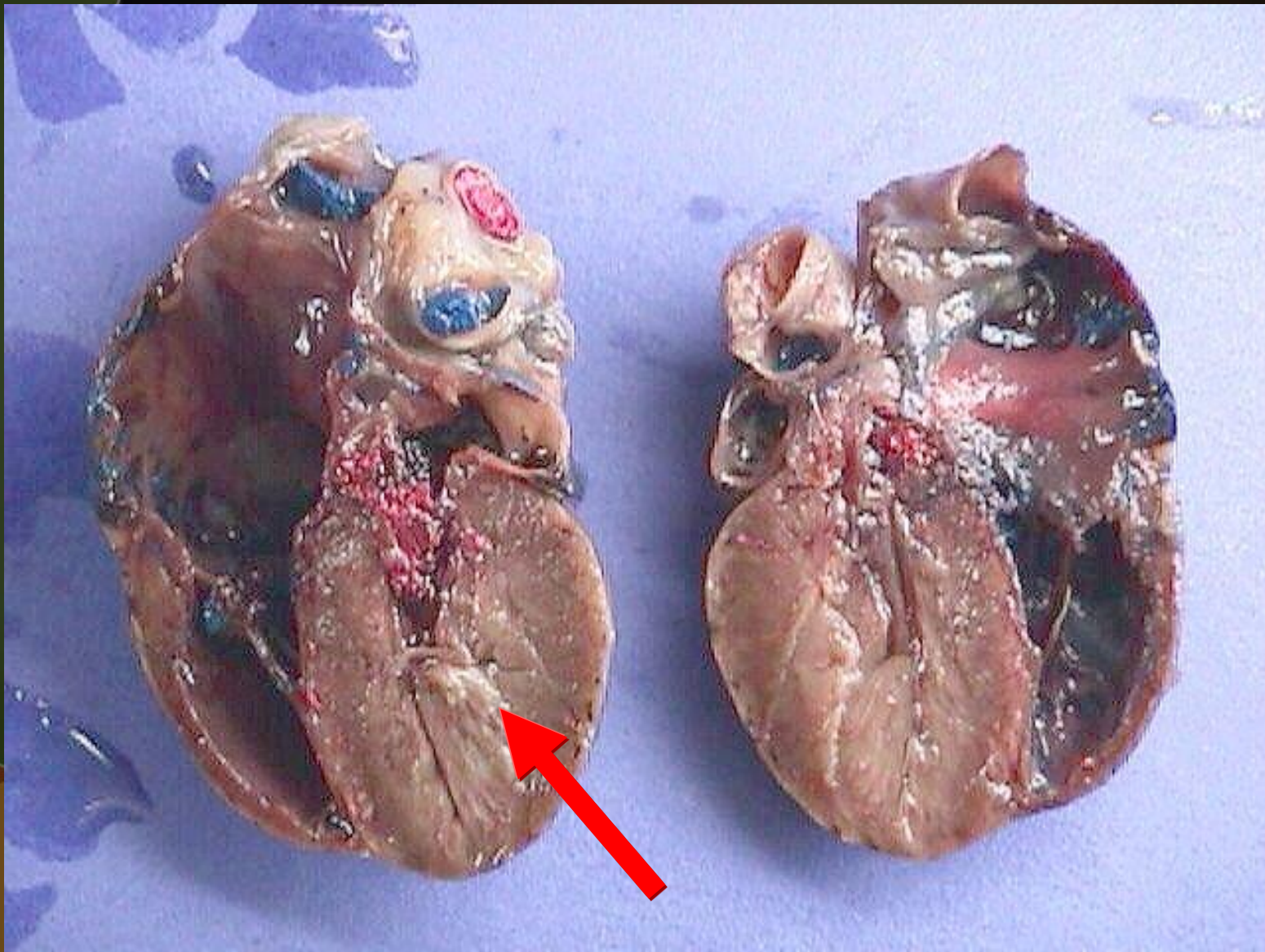
Cardiac vein



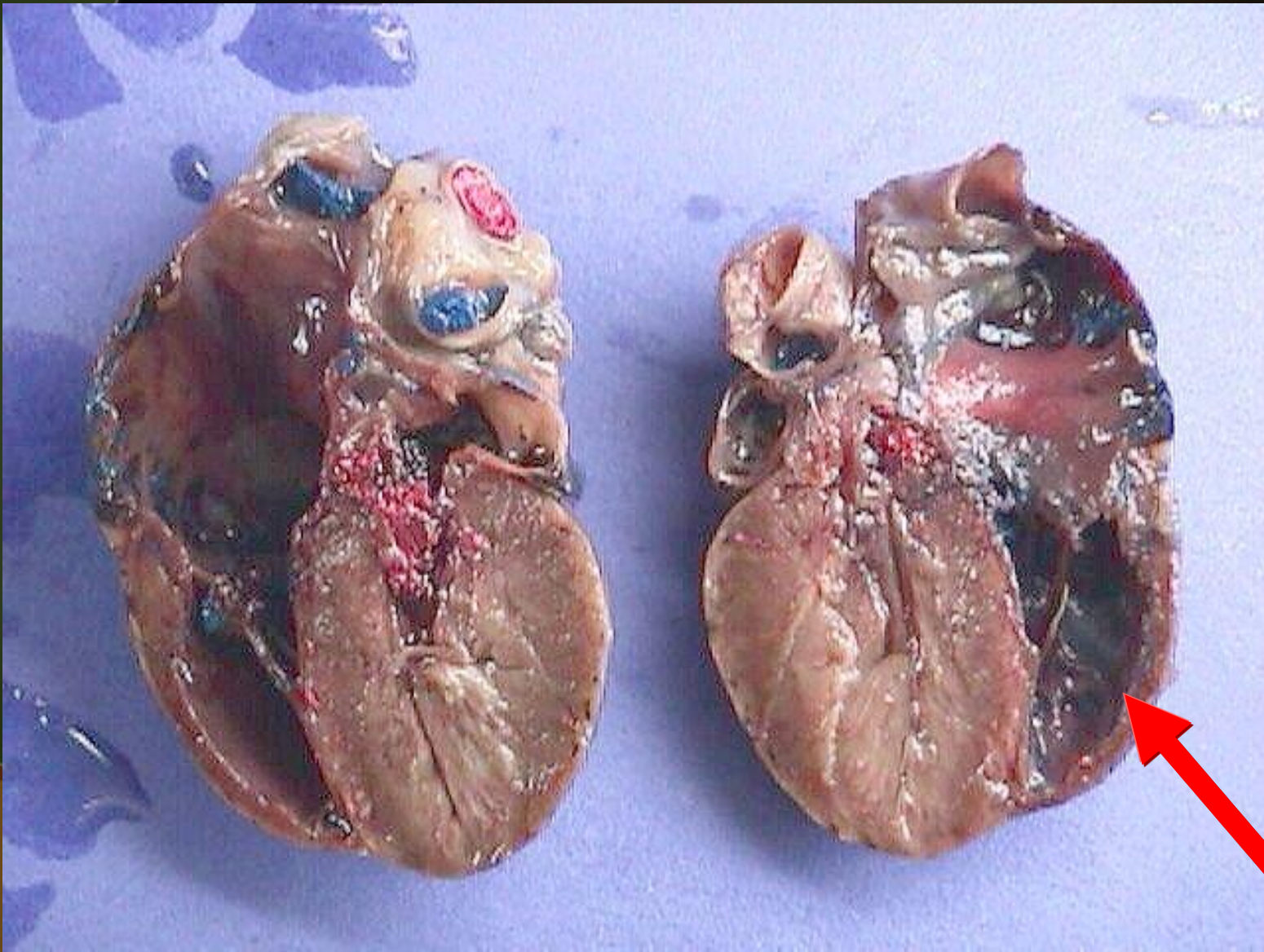
Left ventricle



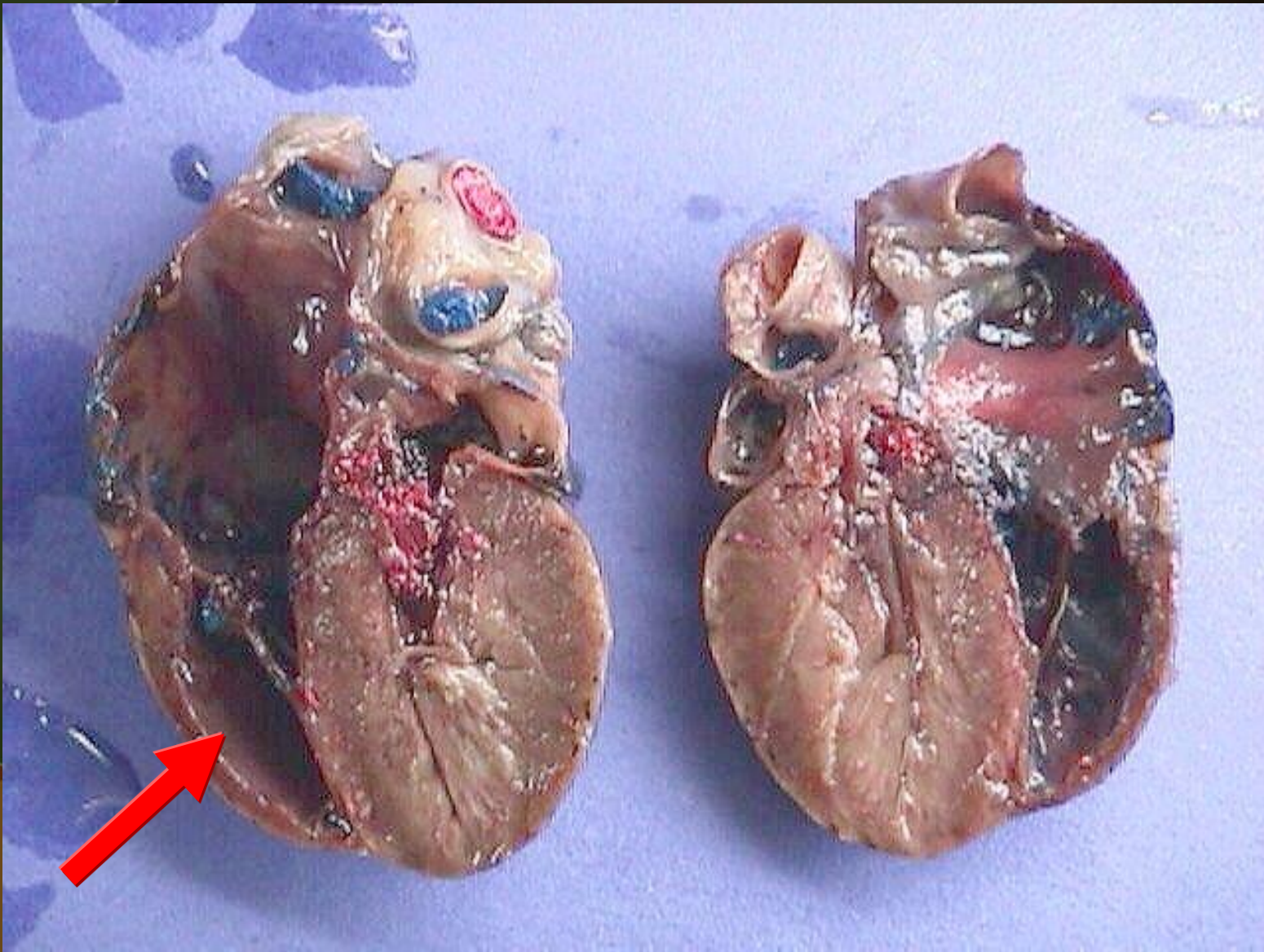
Left ventricle



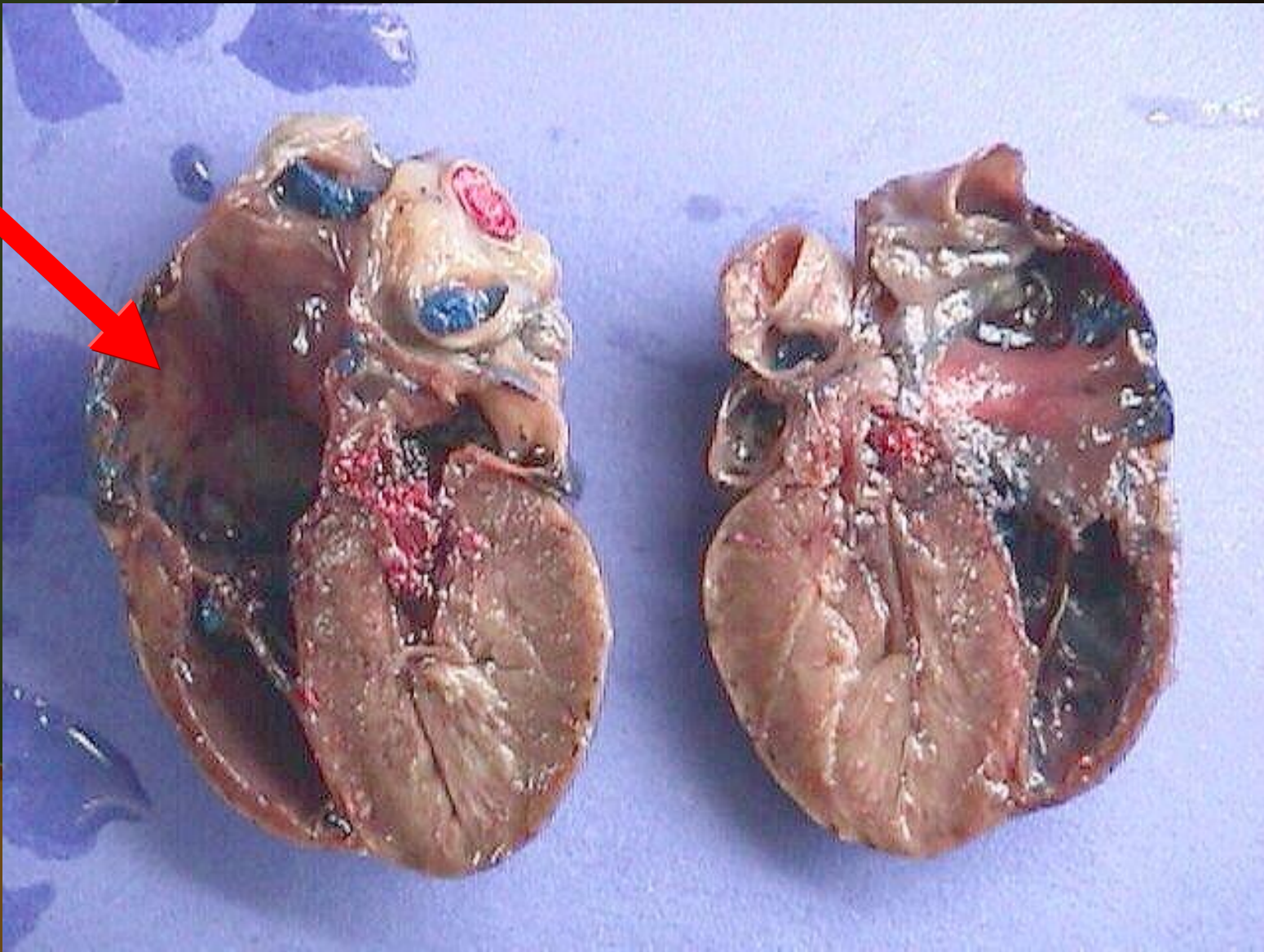
Right ventricle



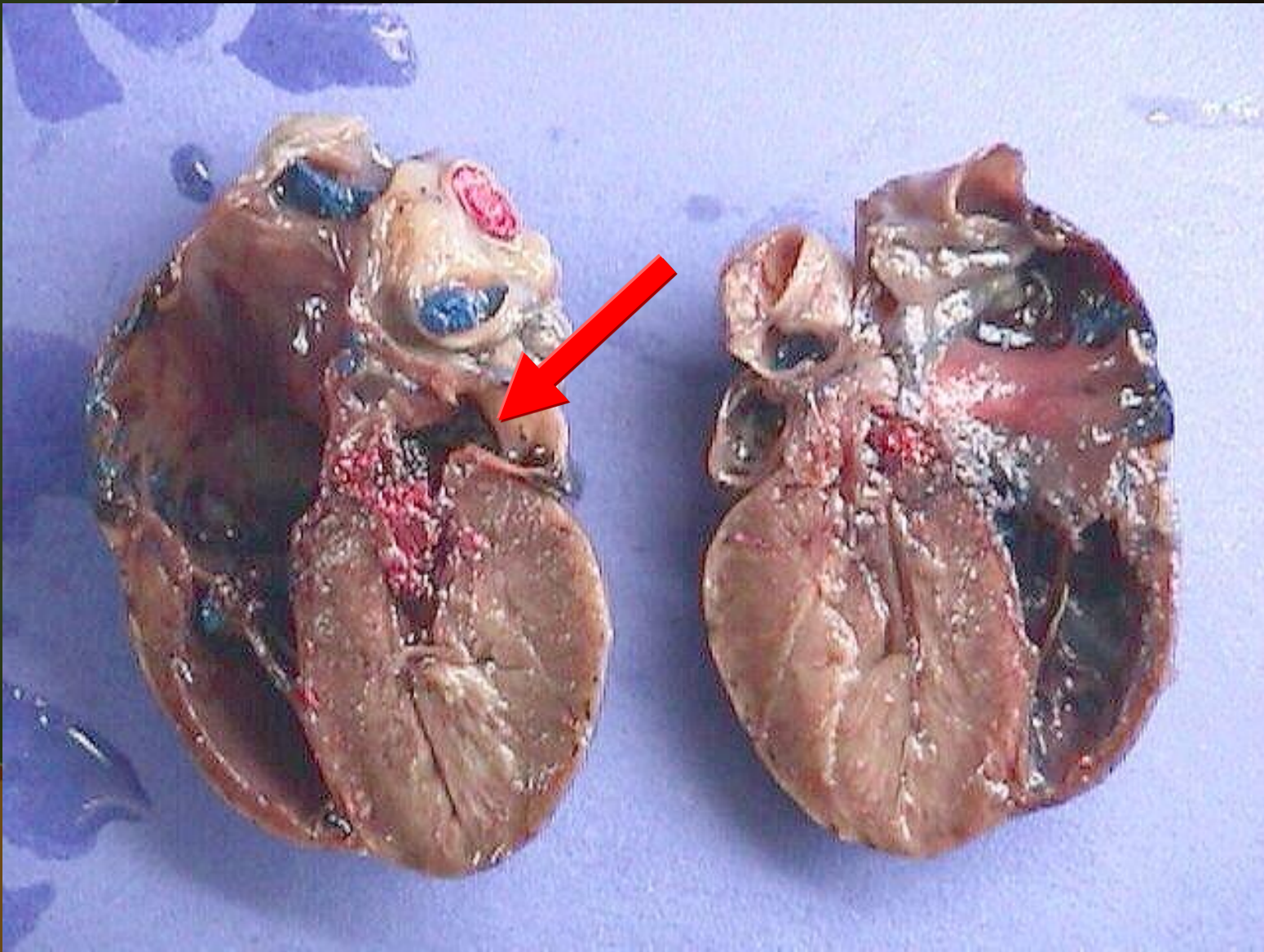
Right ventricle



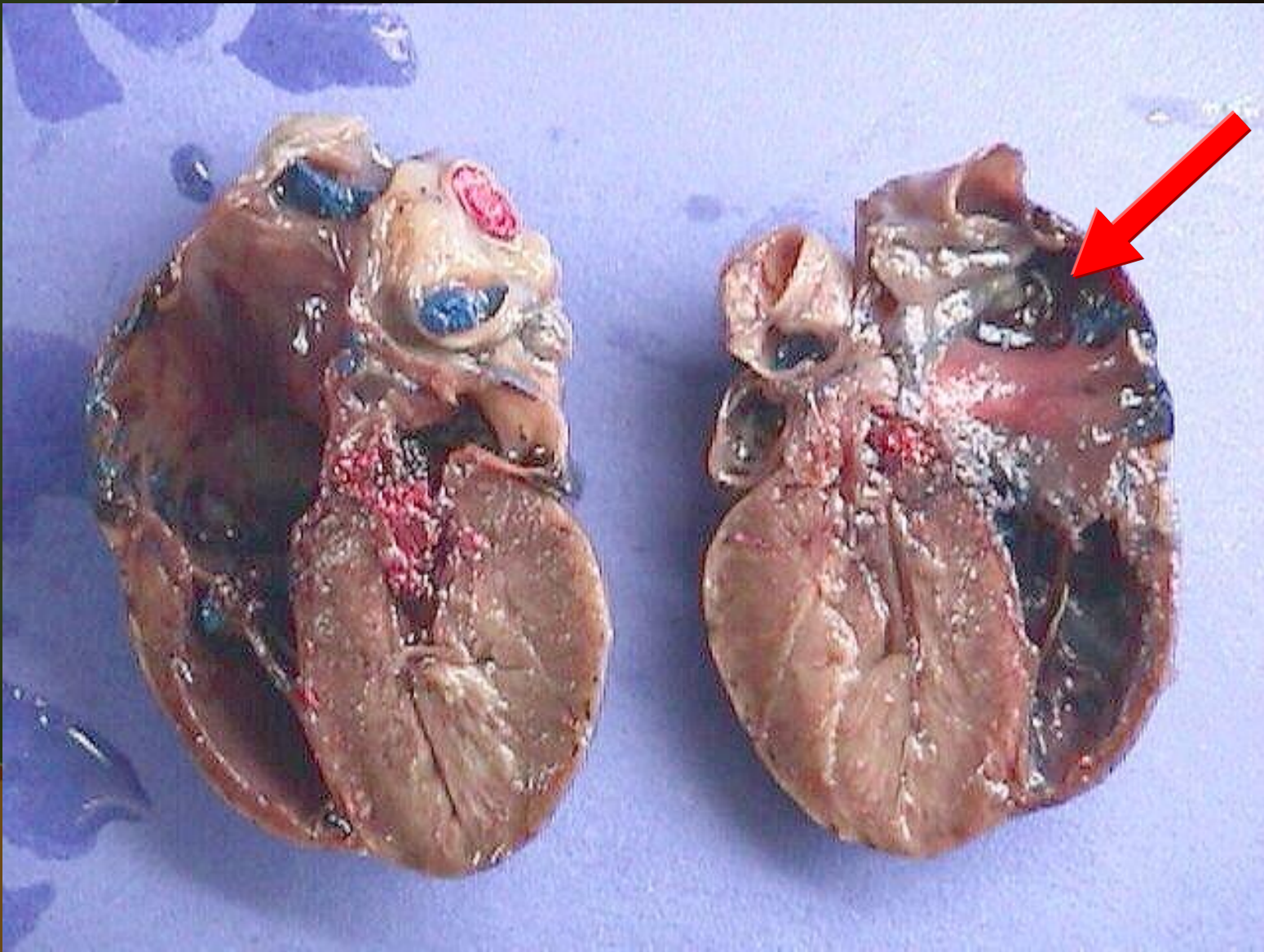
Right atrium



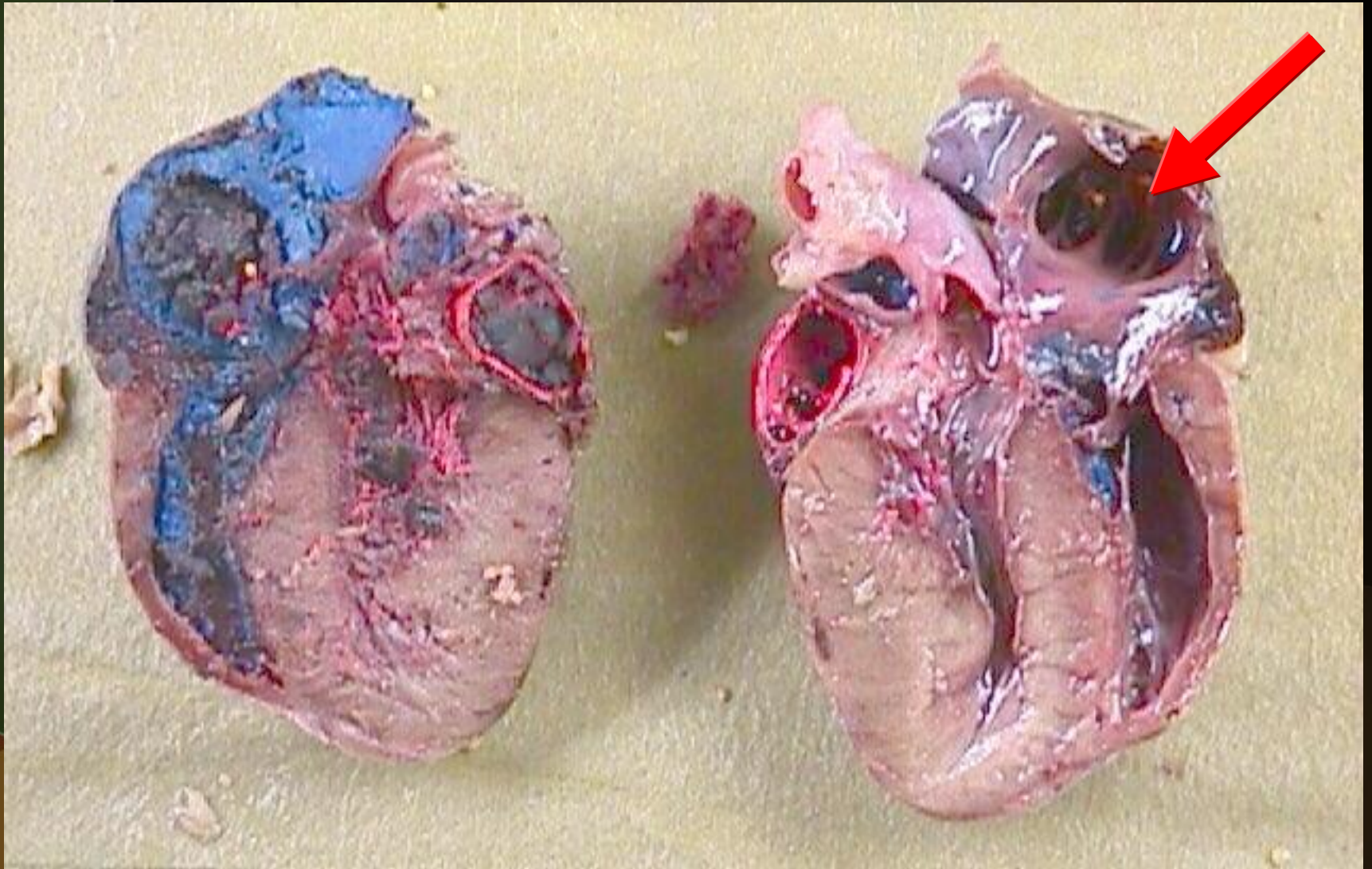
Left atrium



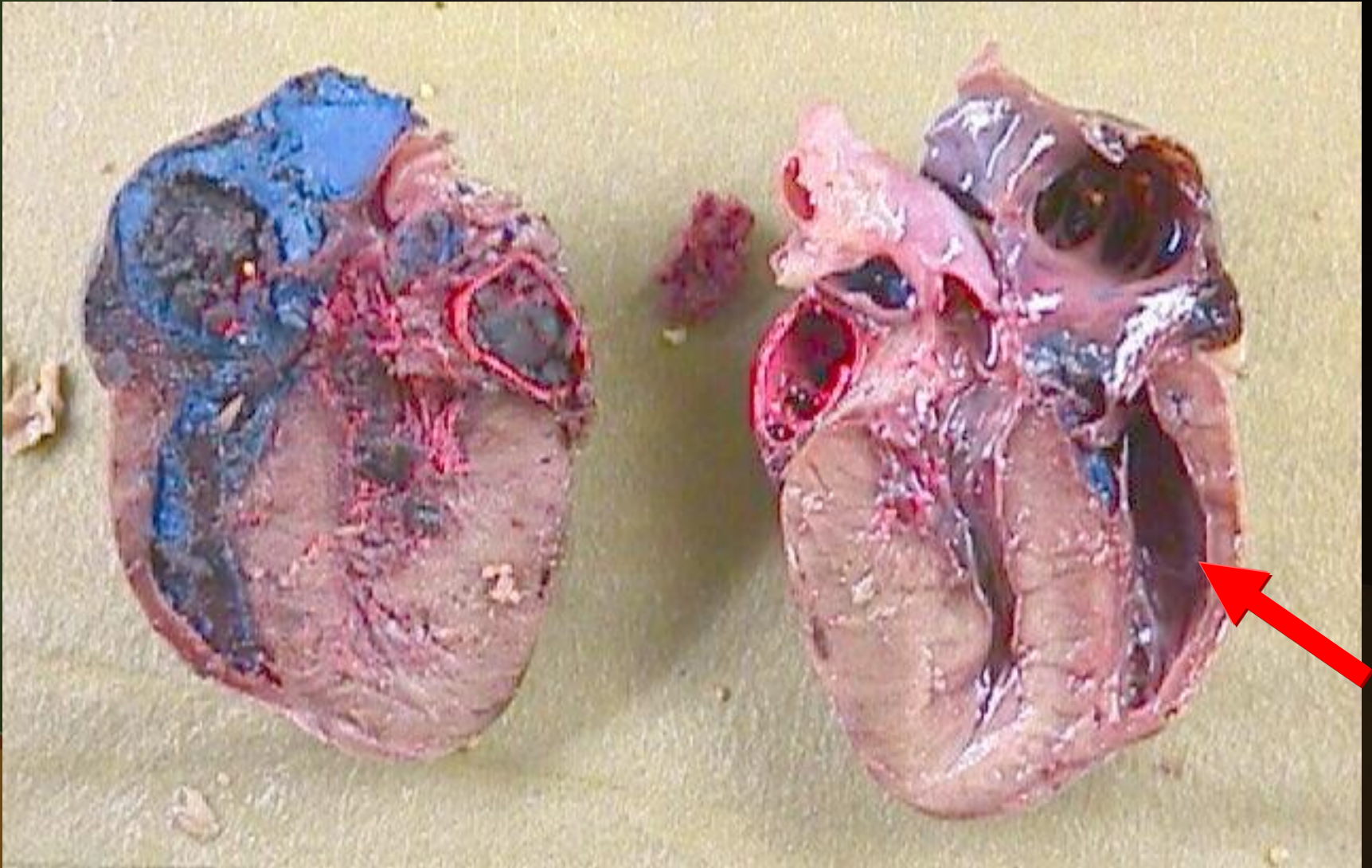
Right atrium



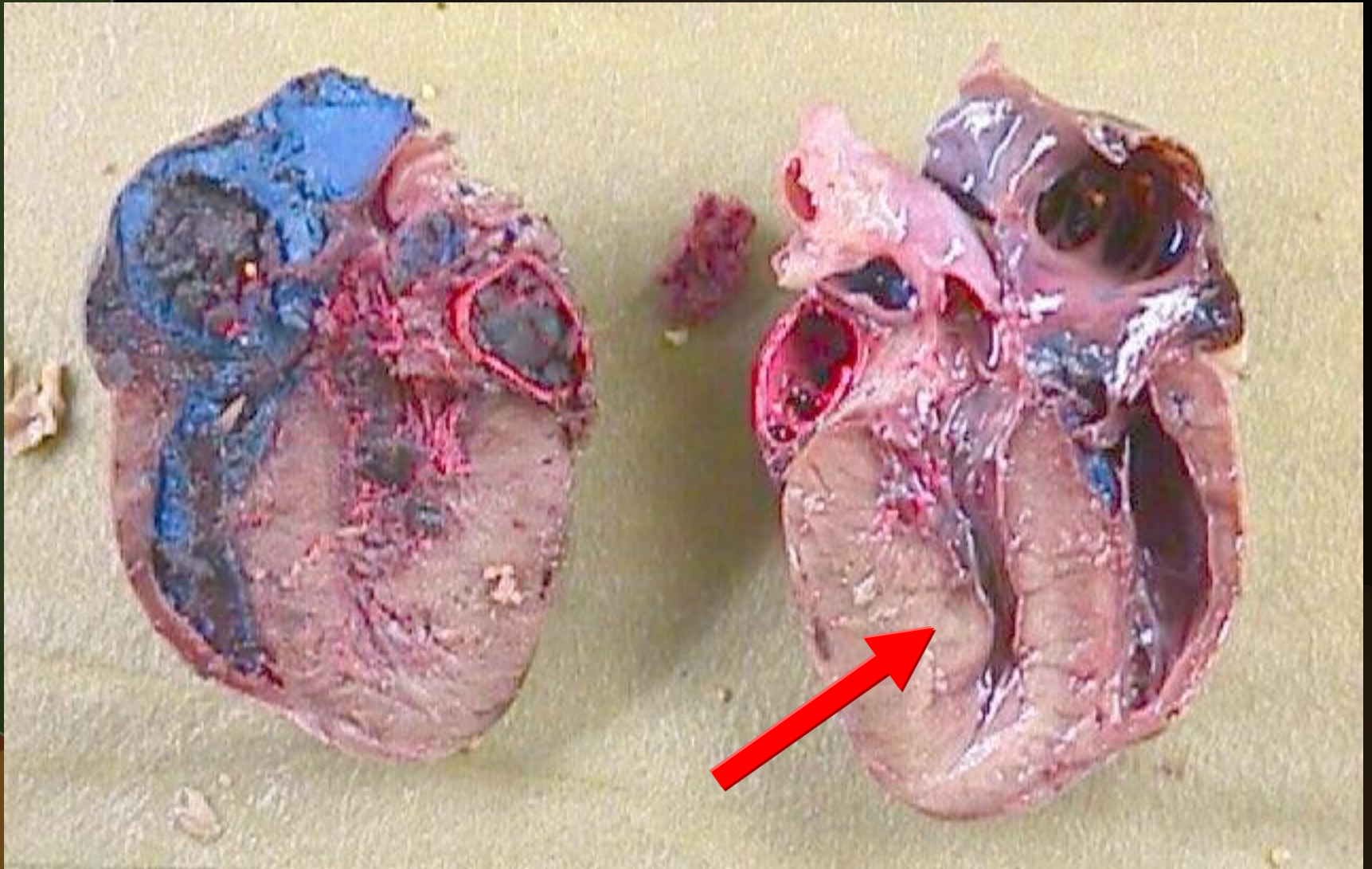
Right atrium



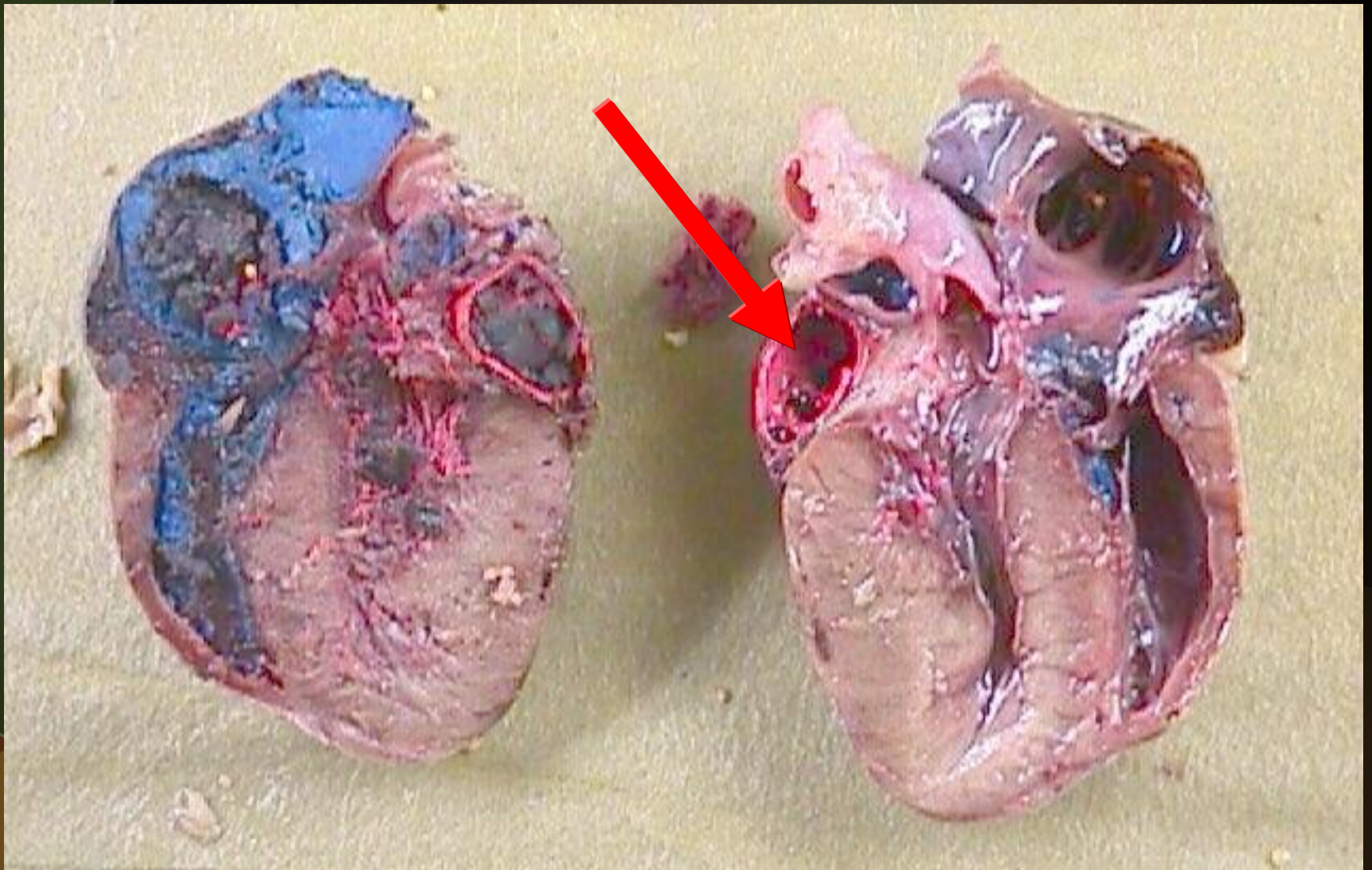
Right ventricle



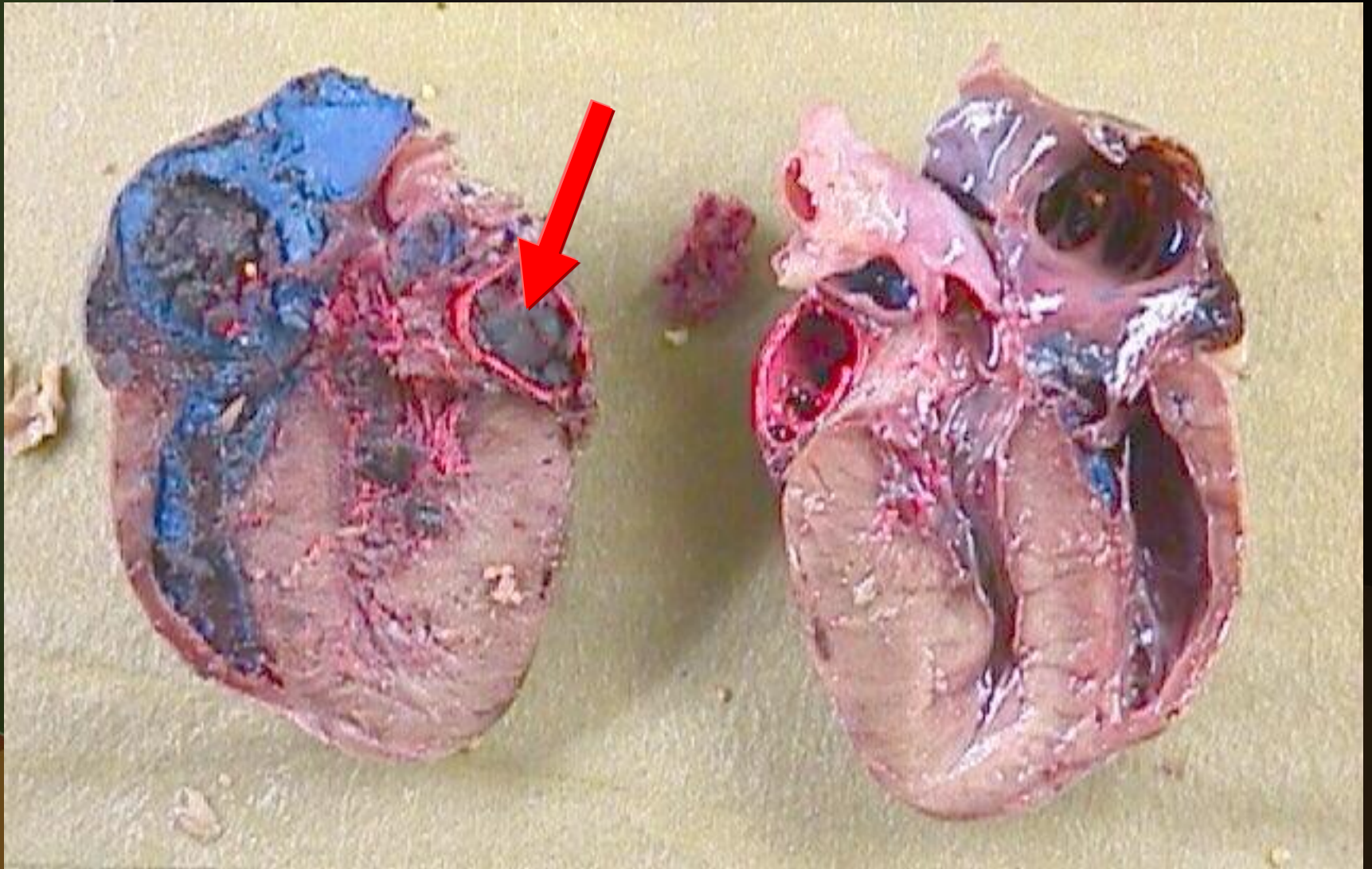
Left ventricle



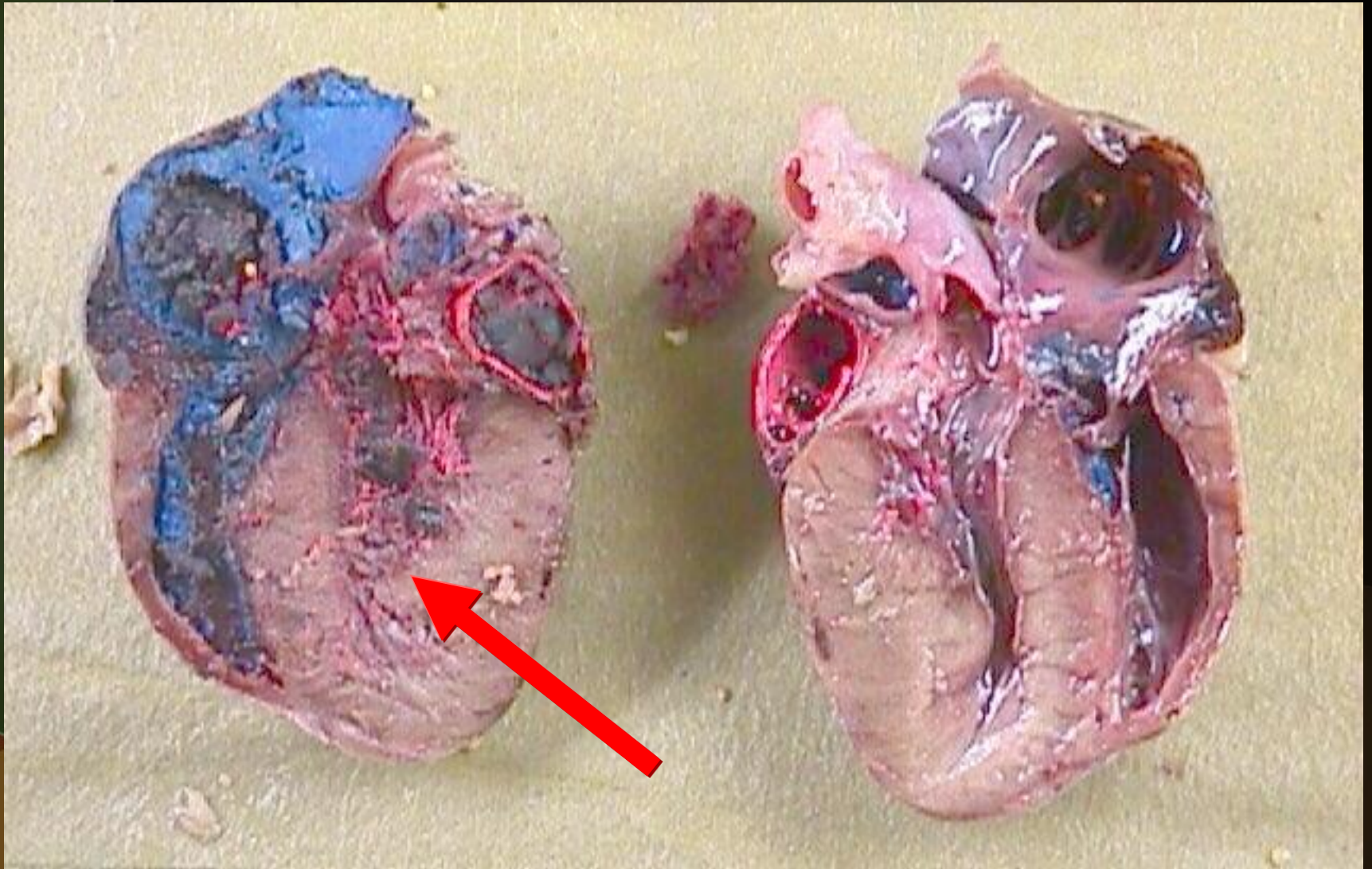
Left atrium



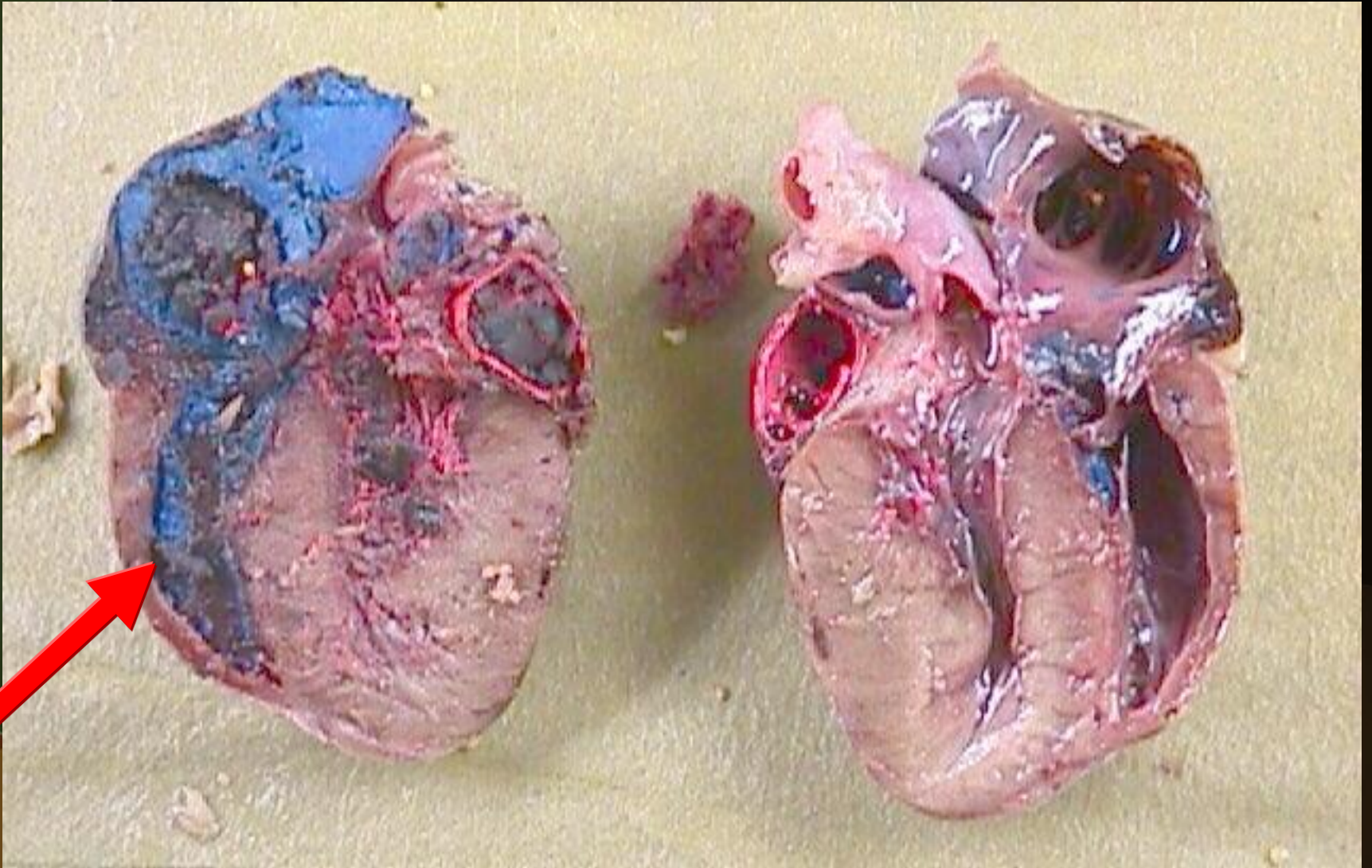
Left atrium



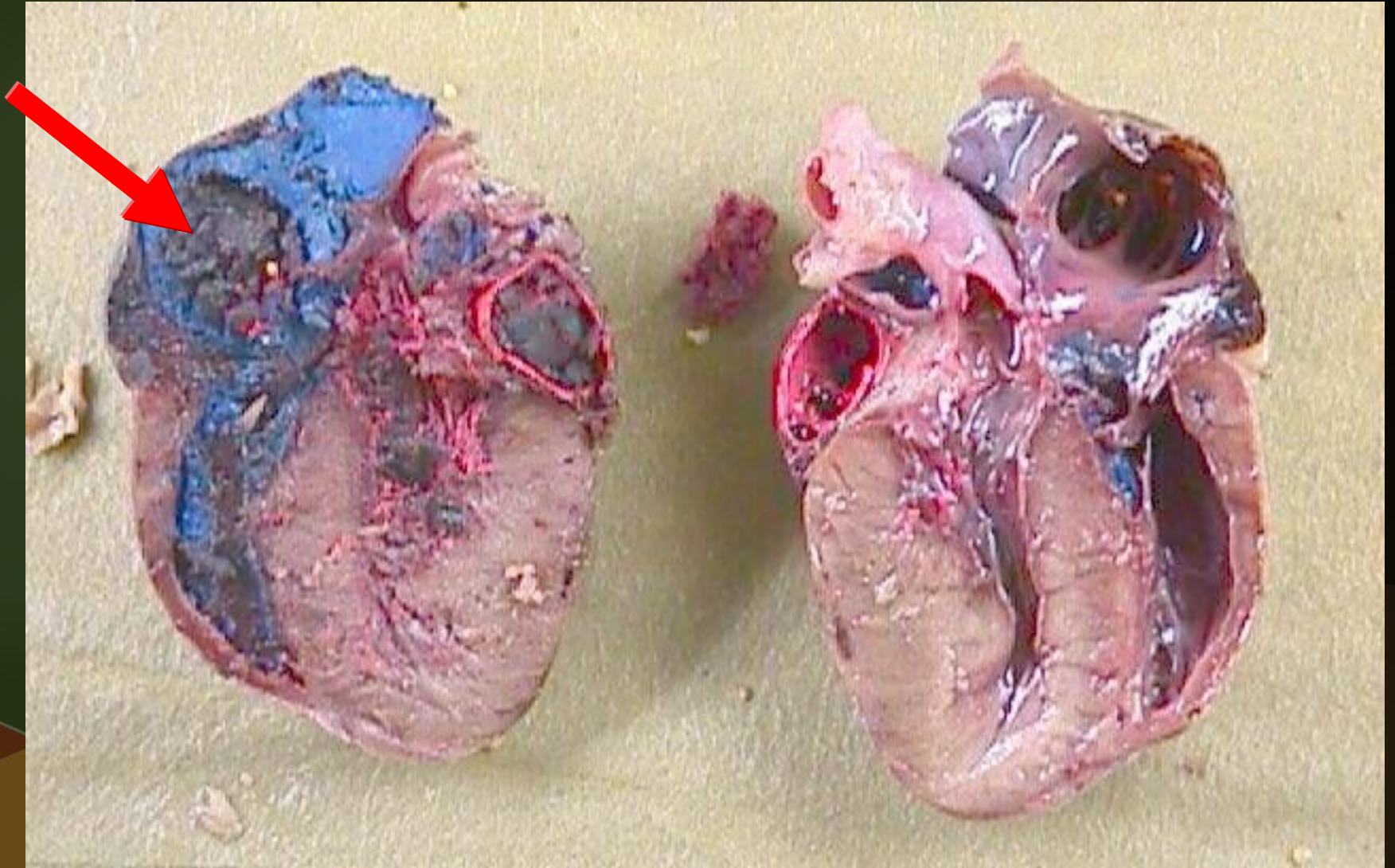
Left ventricle



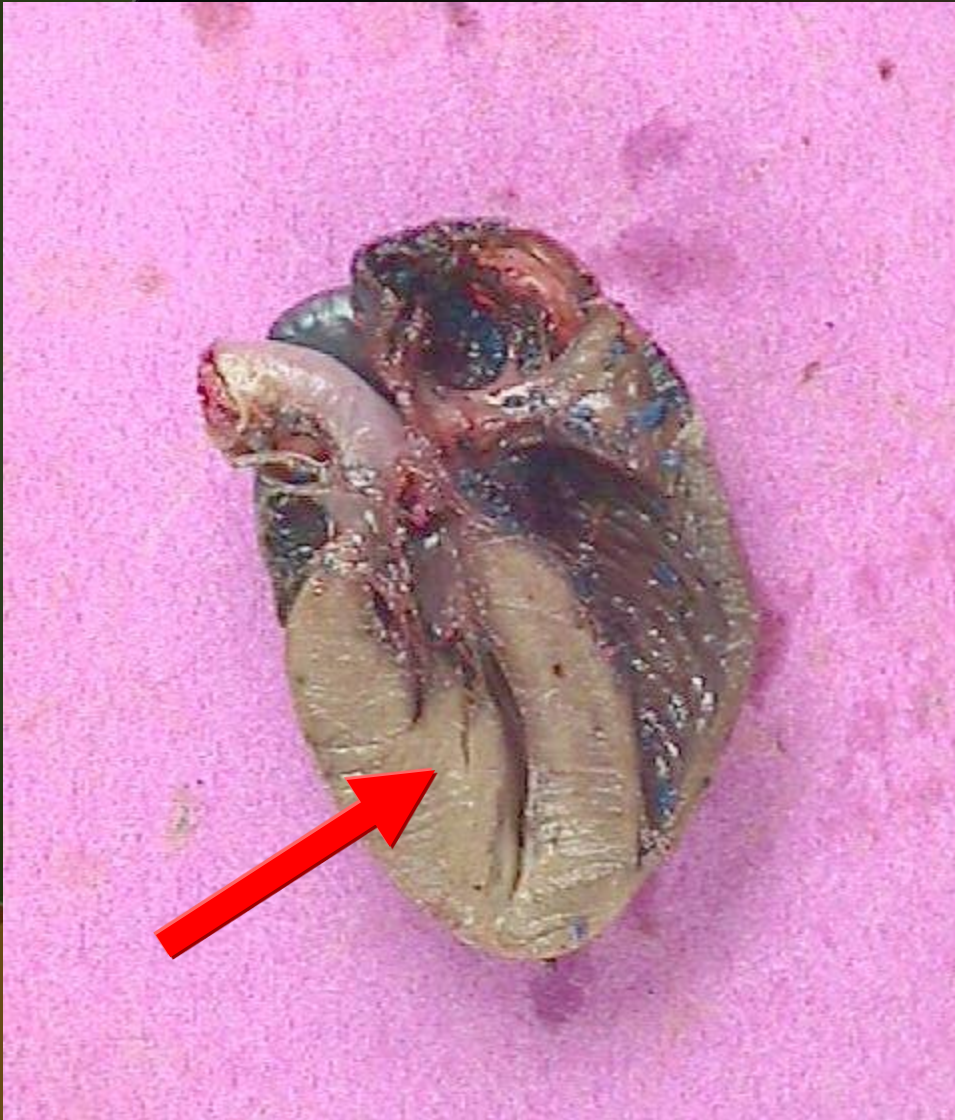Right ventricle



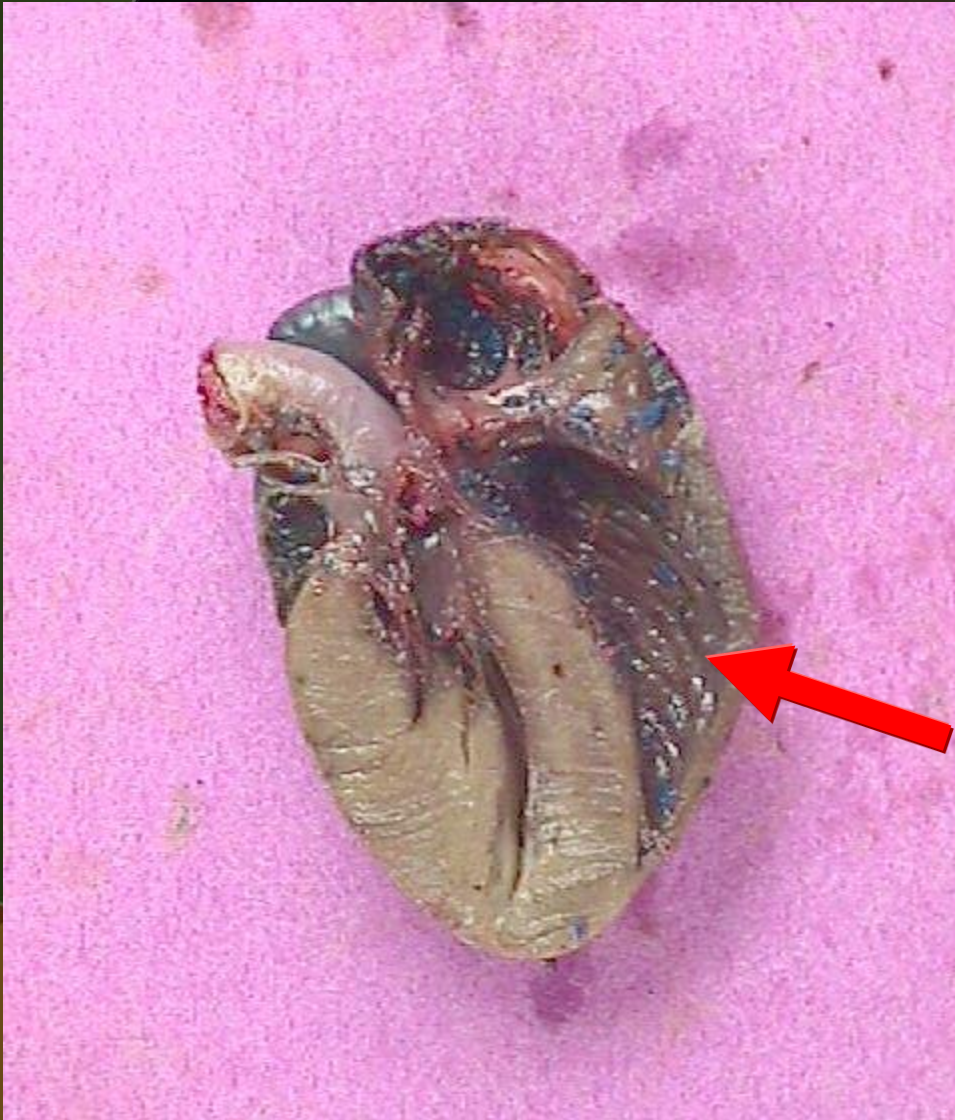Right atrium



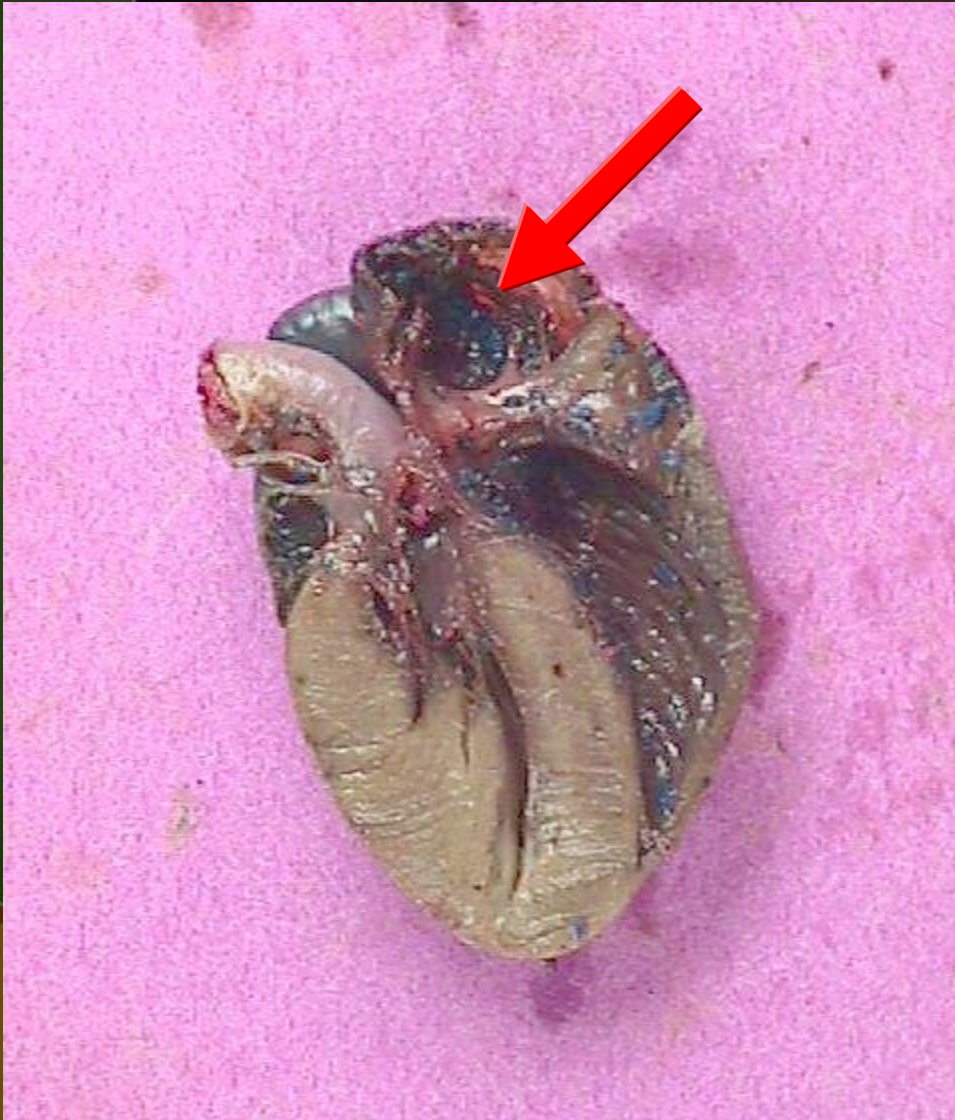
Left ventricle



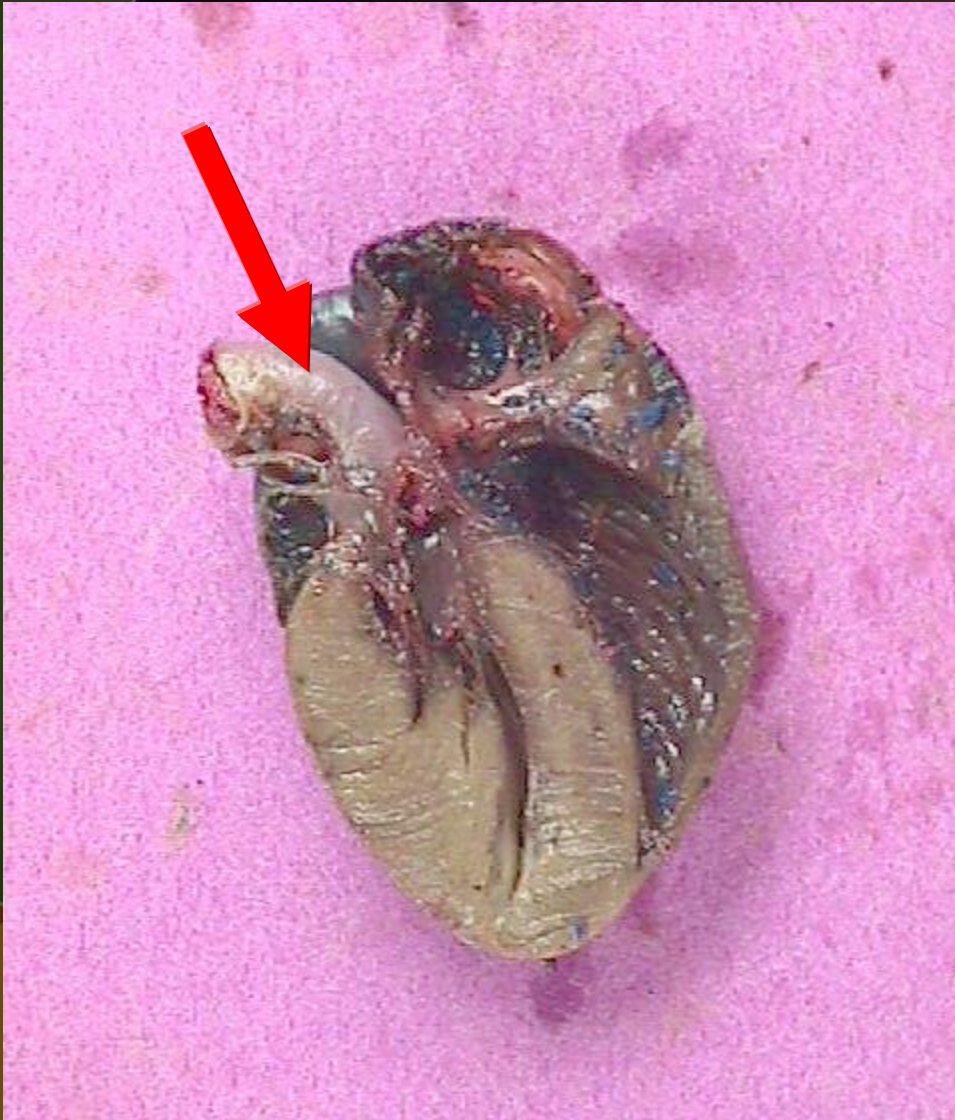Right ventricle



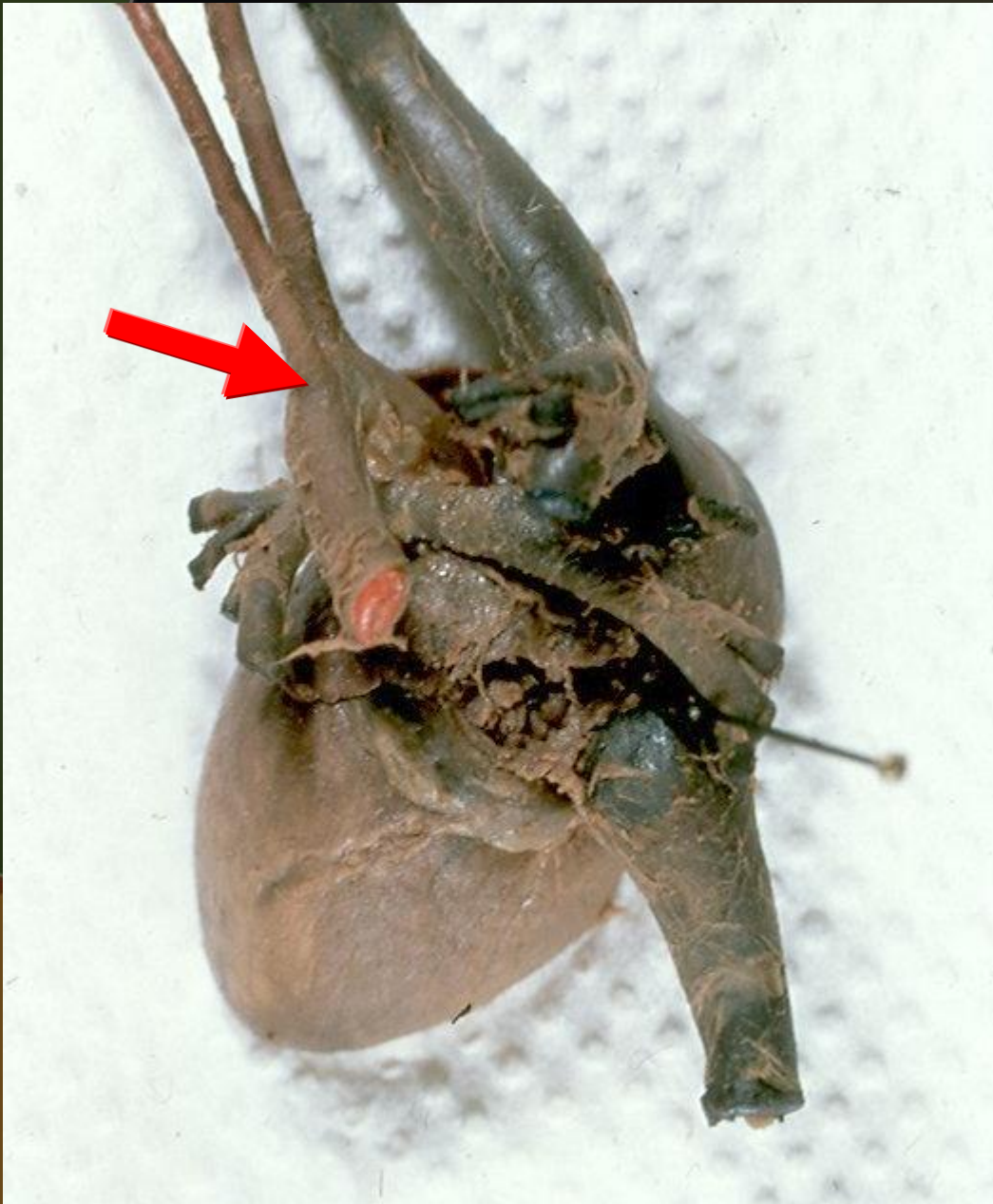
Right atrium



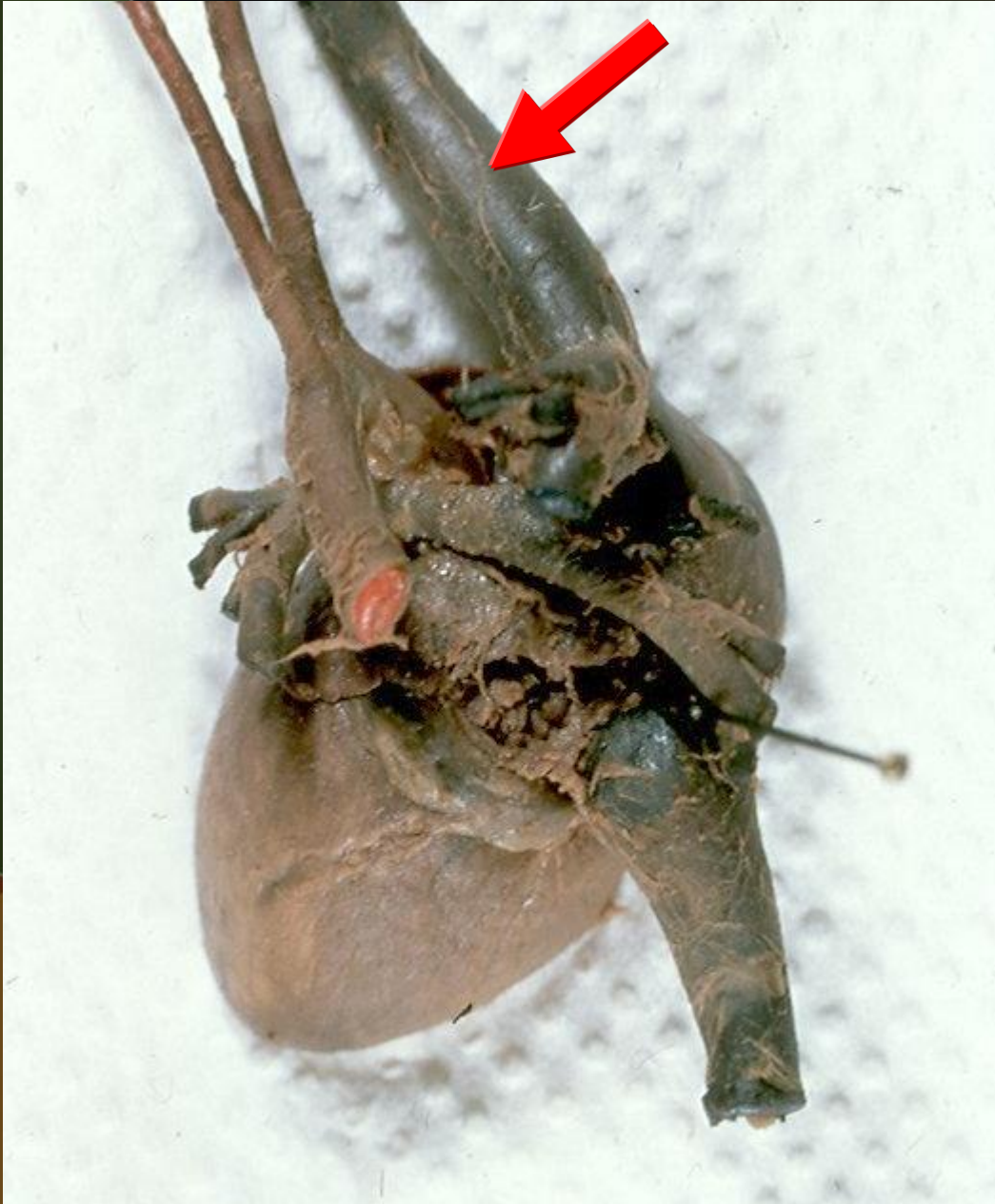Aortic arch



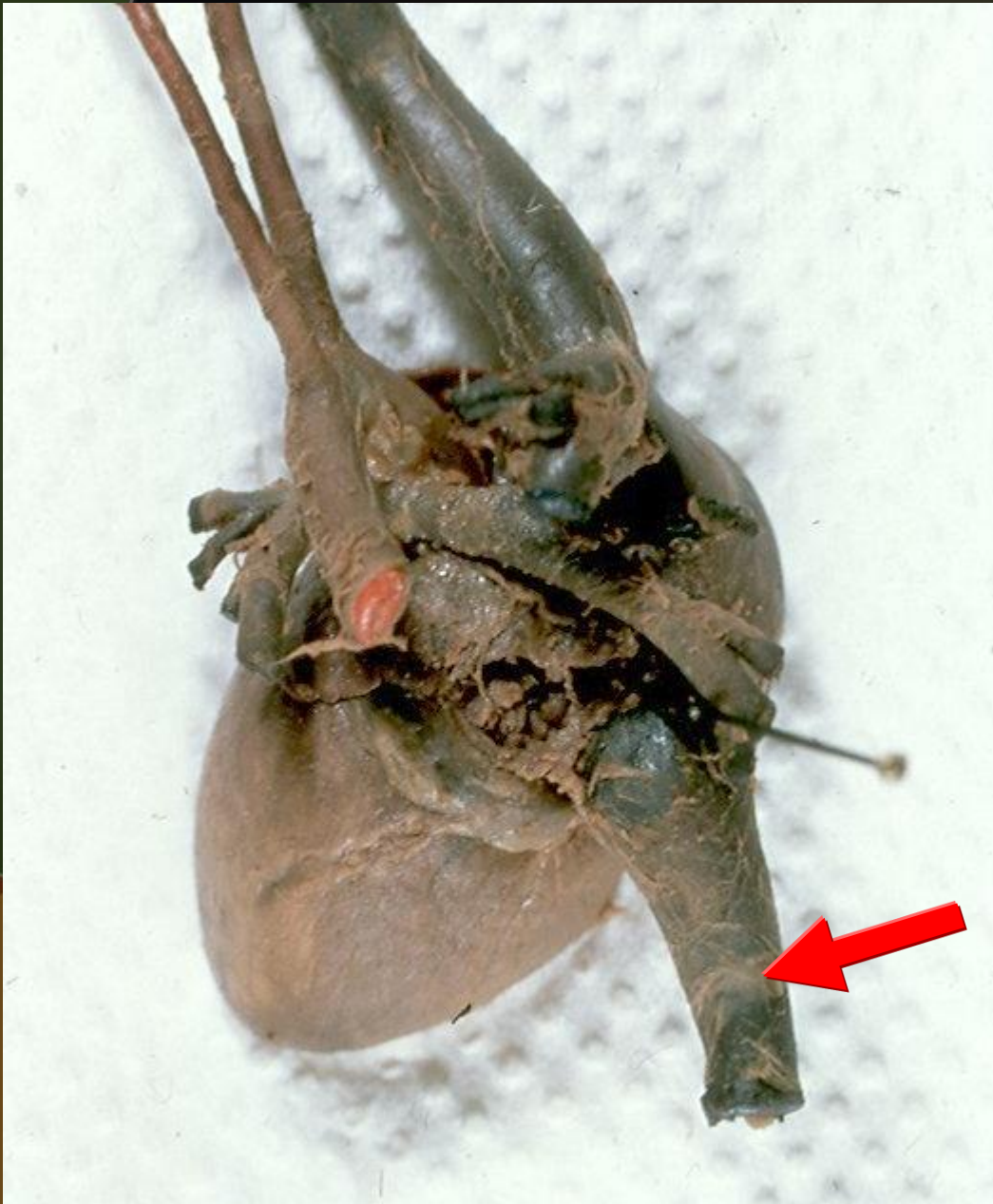
Aortic arch



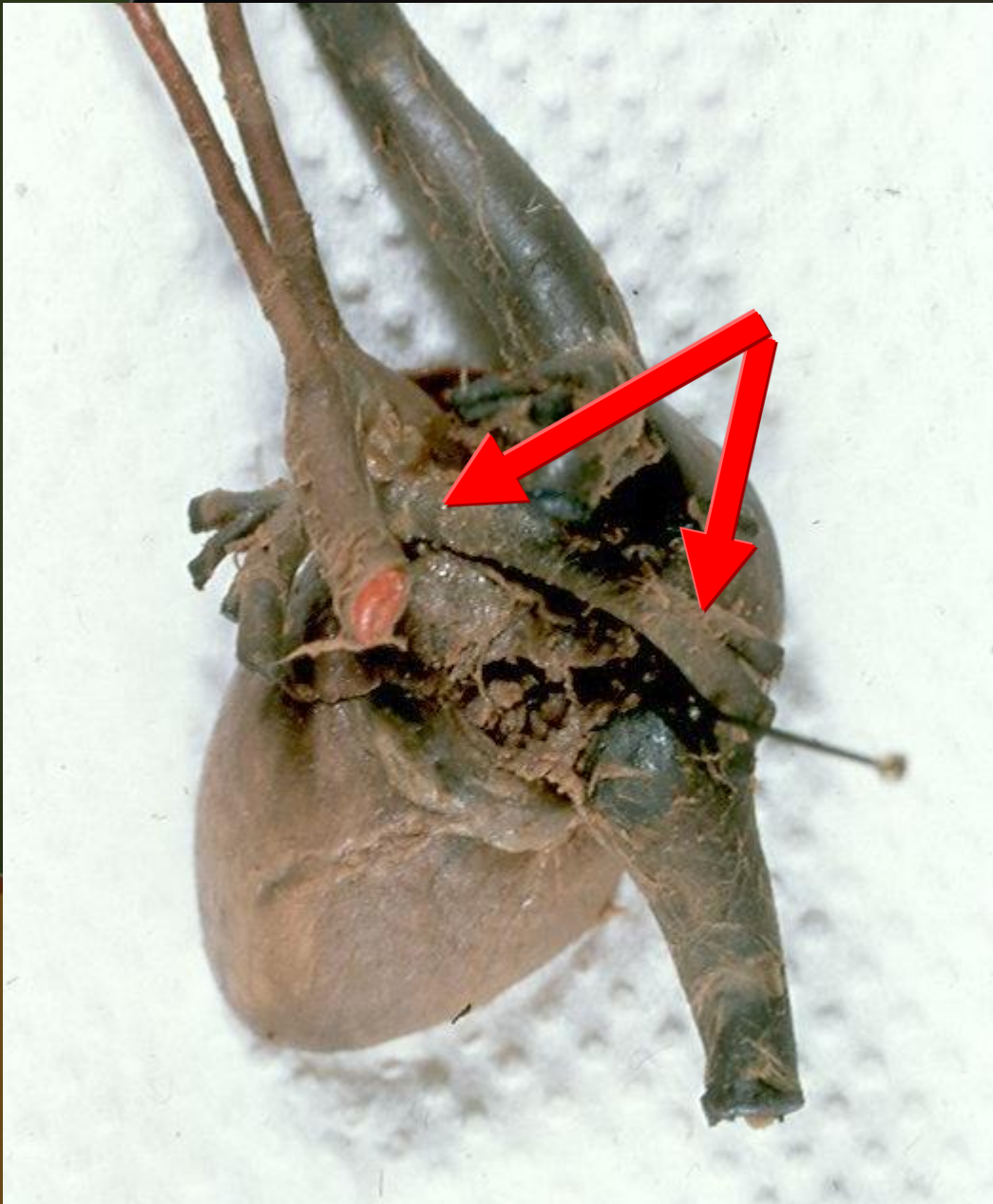Precava



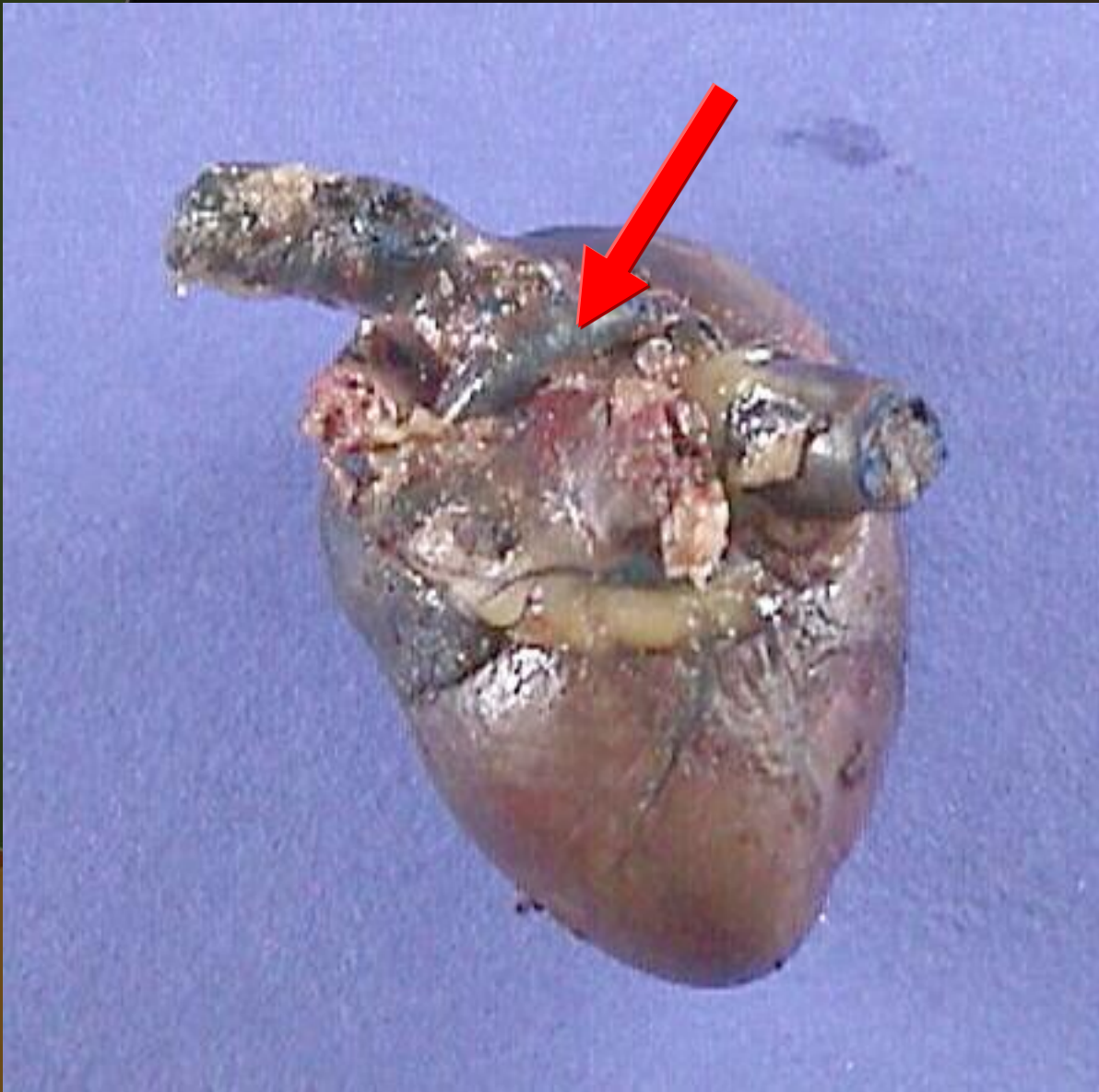
Postcava



Pulmonary veins



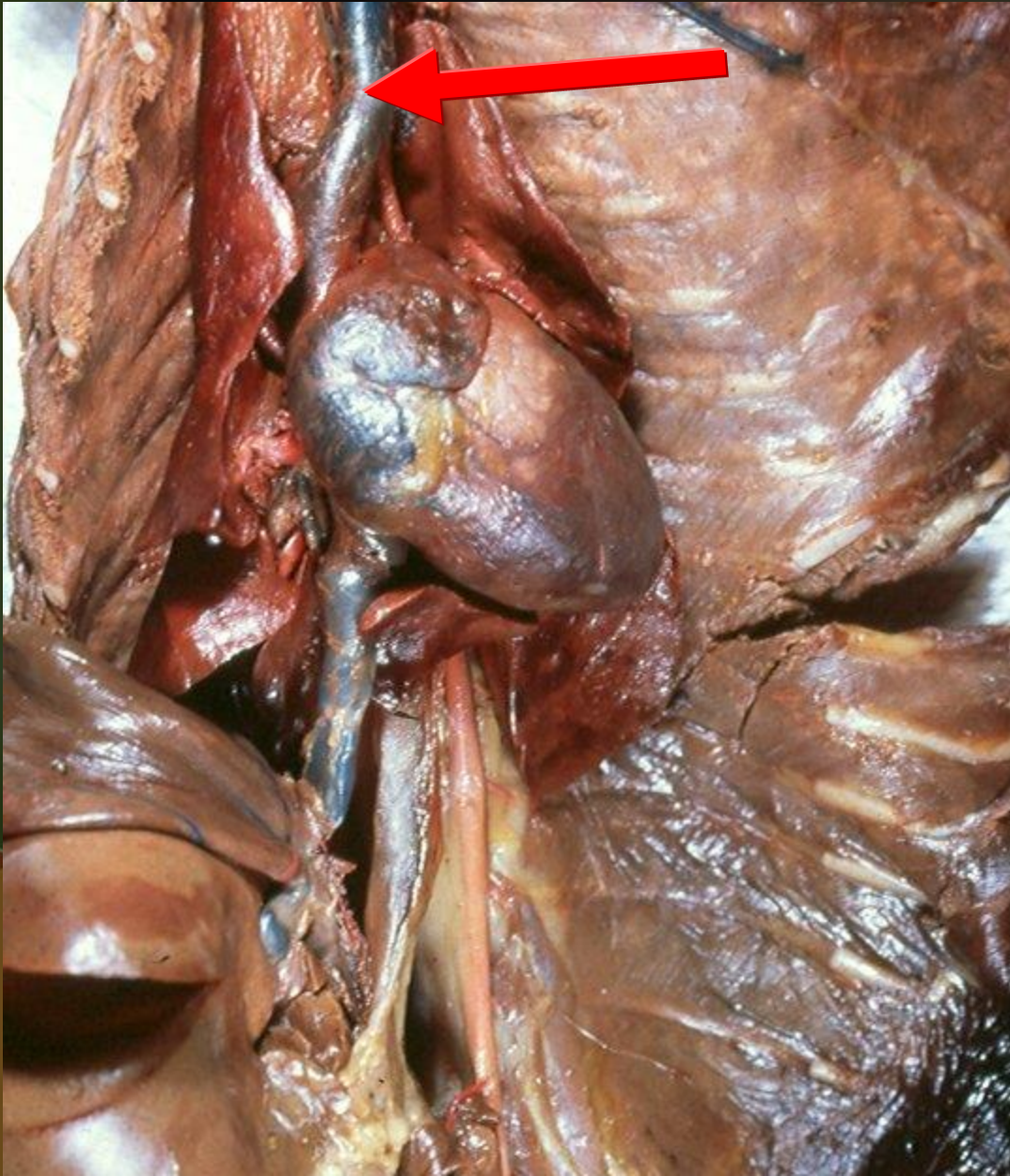
Pulmonary trunk



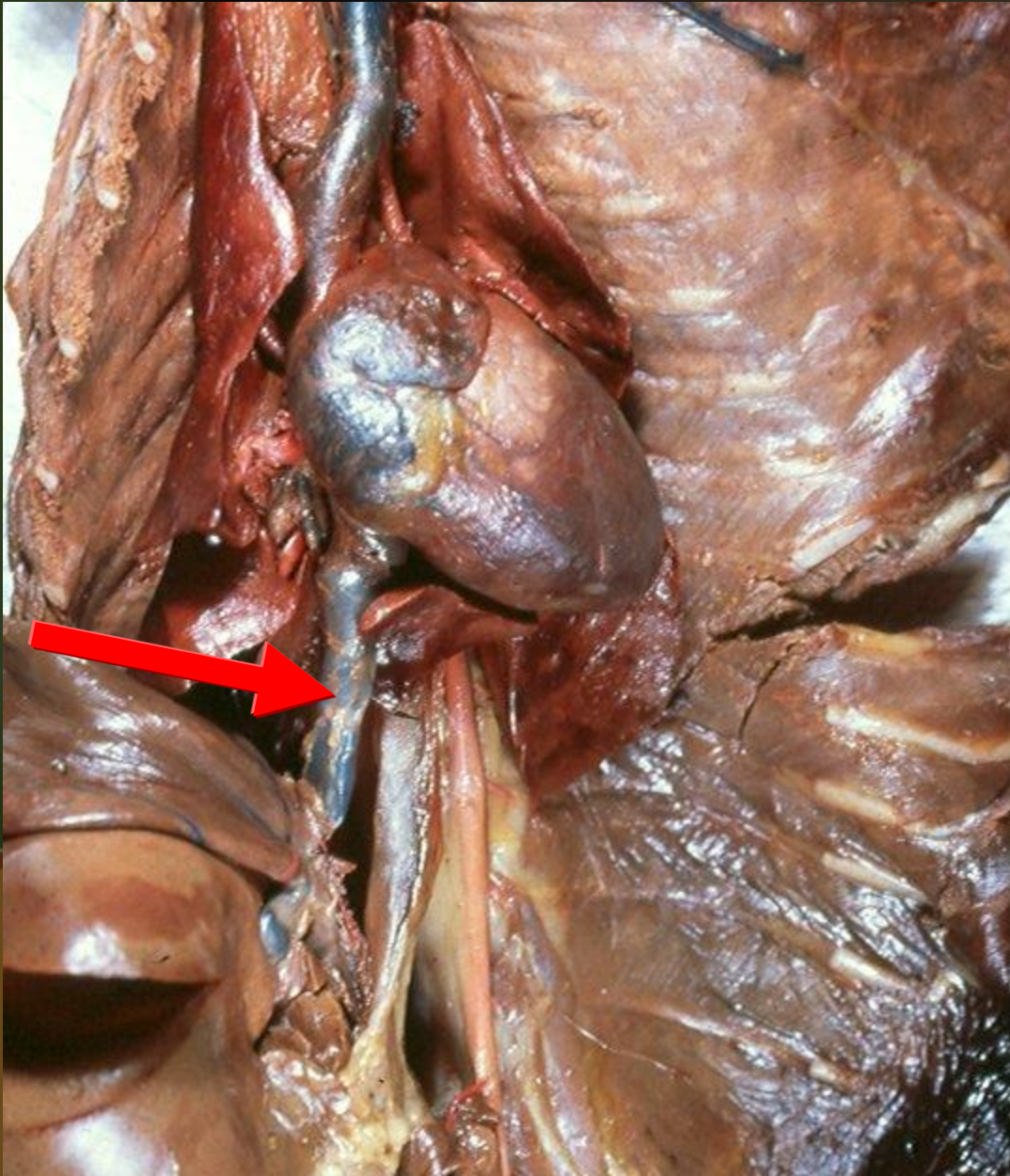
Blood Vessels



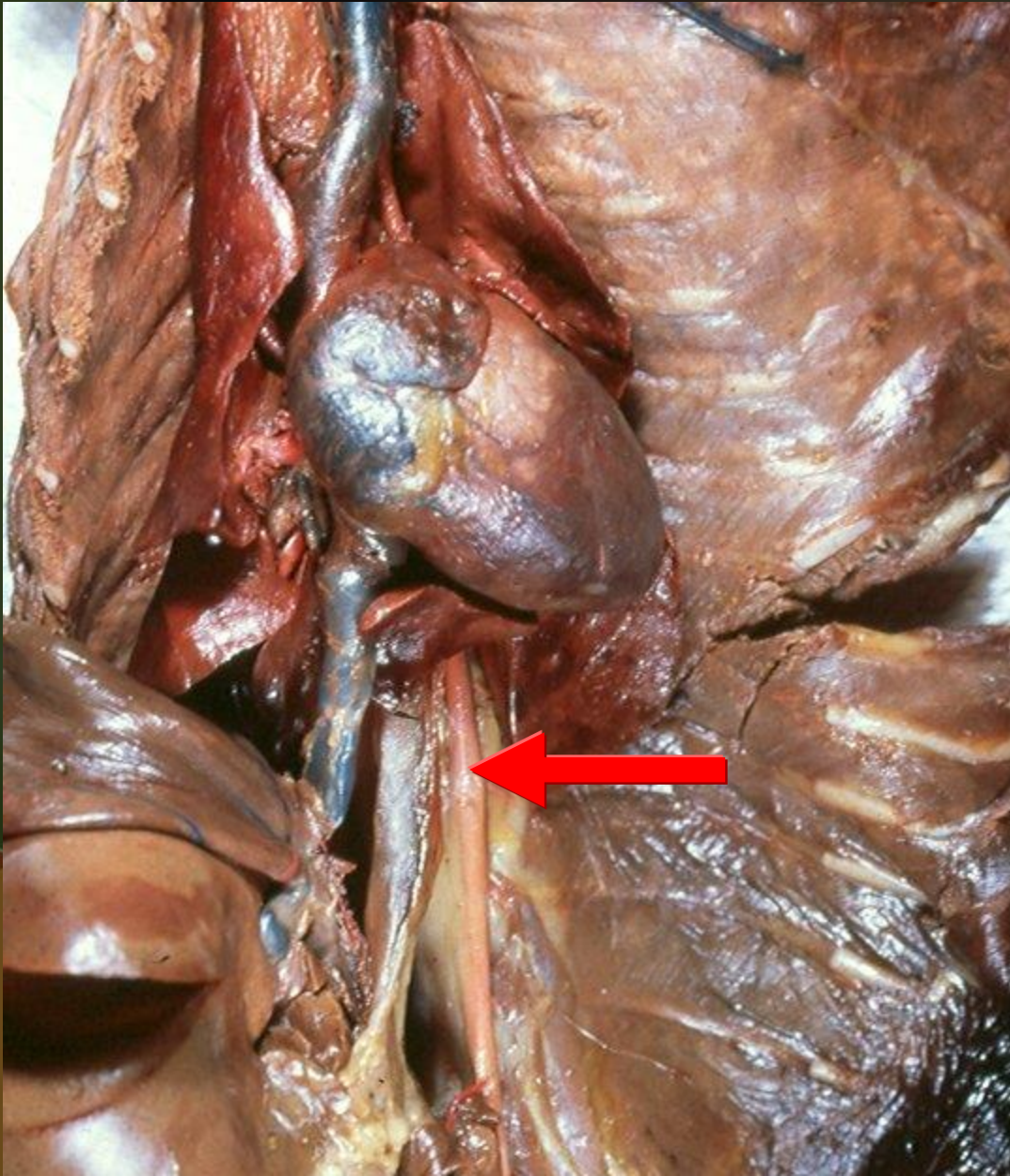
Precava



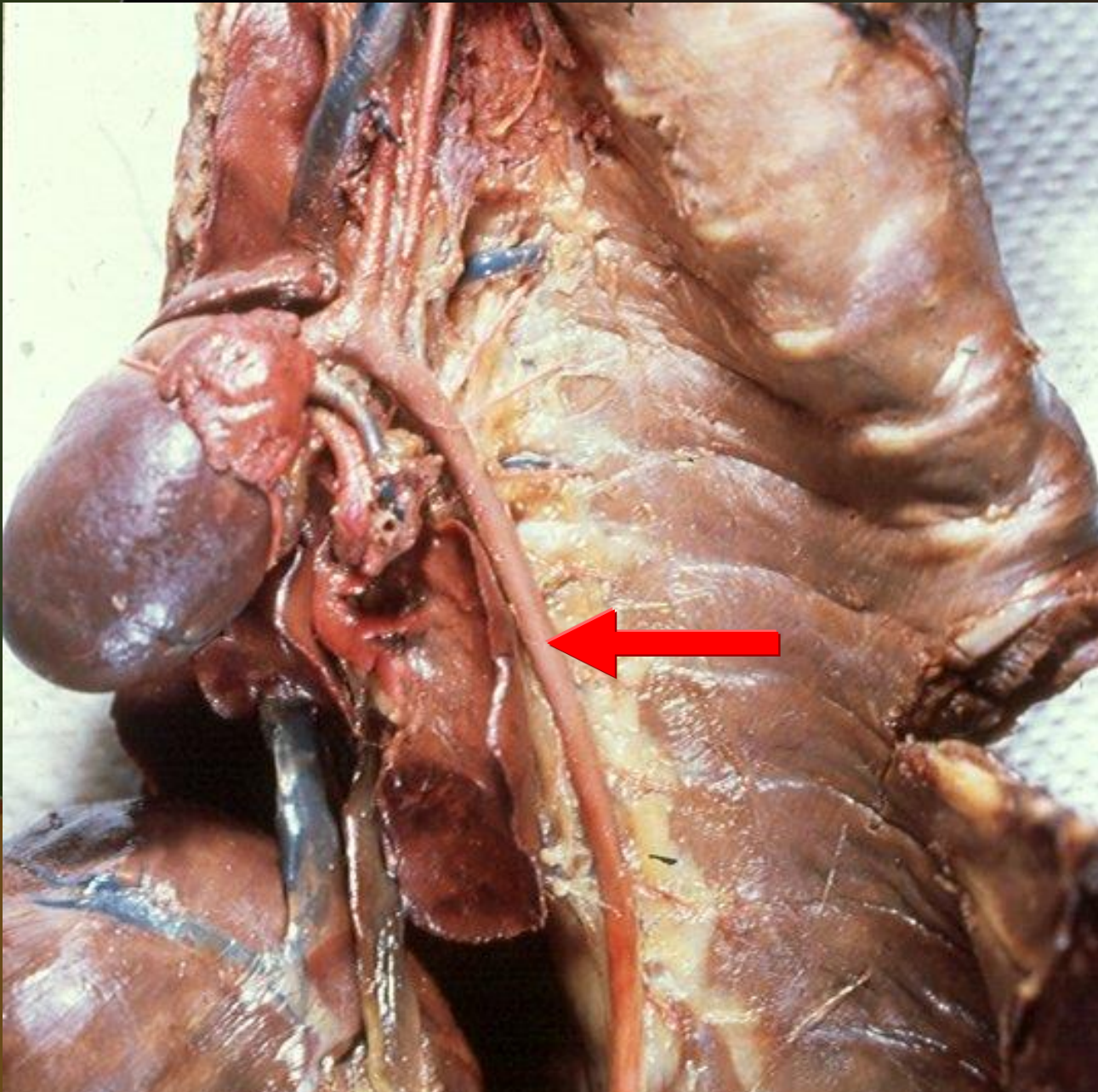
Postcava



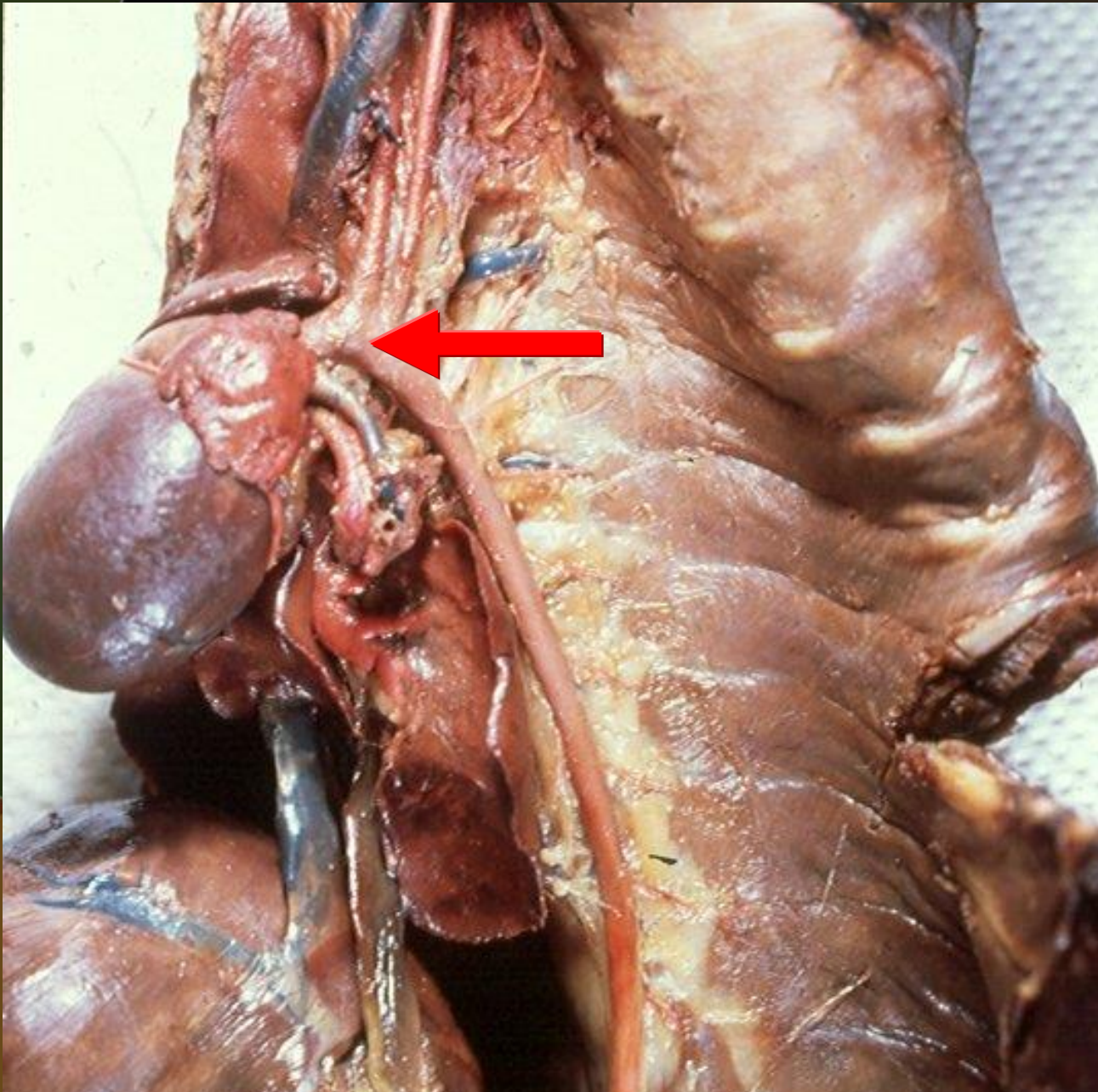
Thoracic aorta



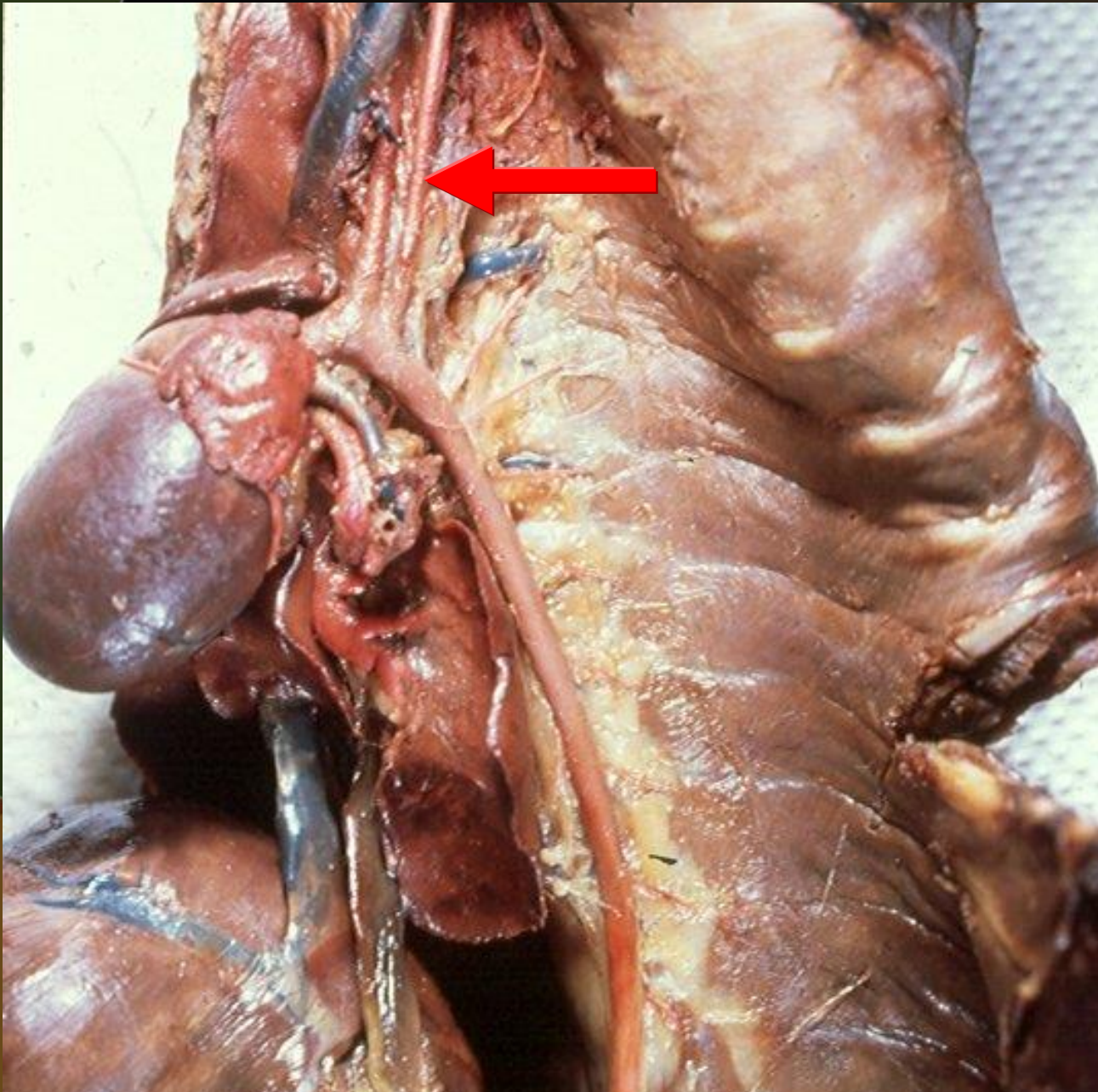
Thoracic aorta



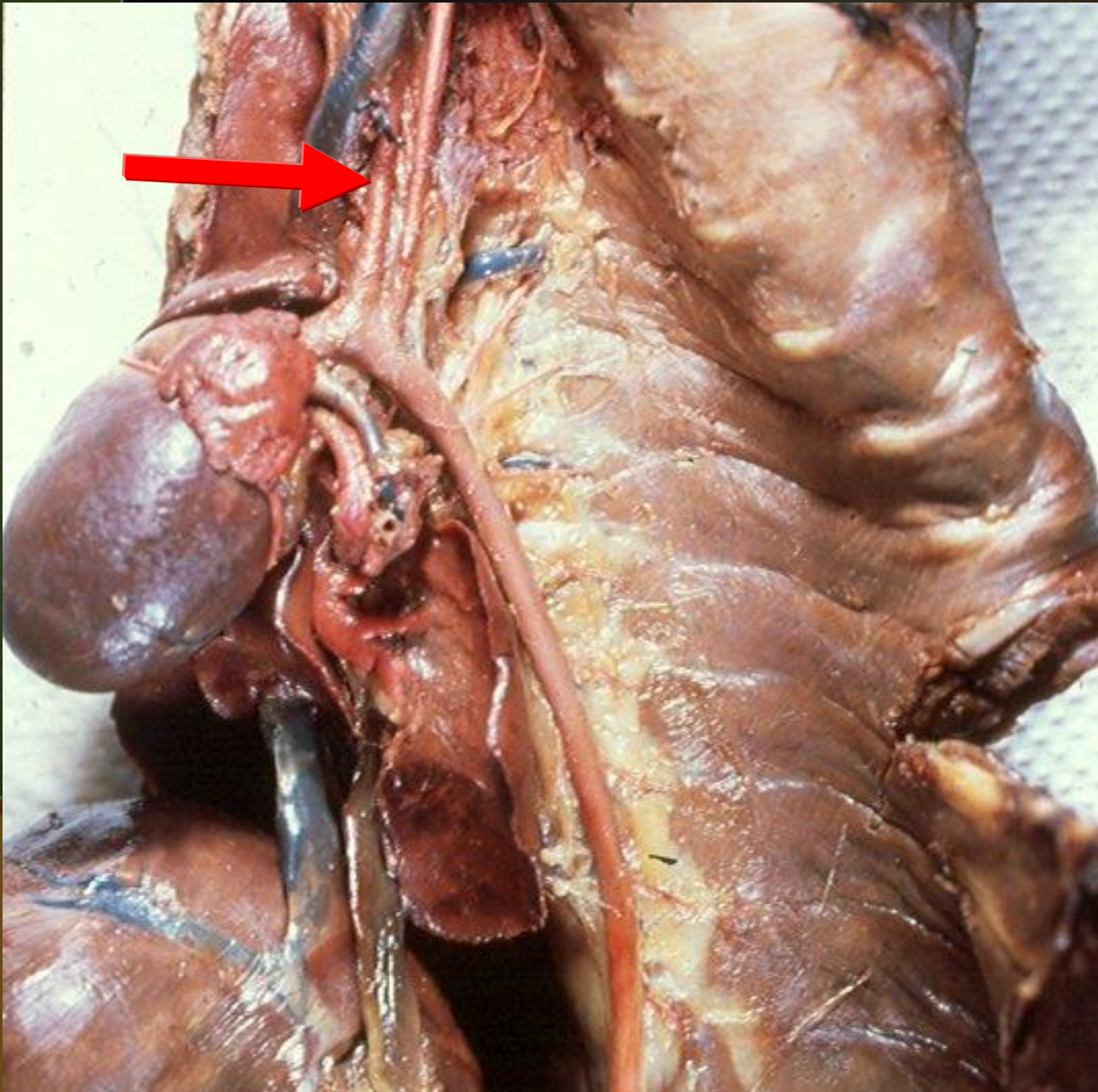
Aortic arch



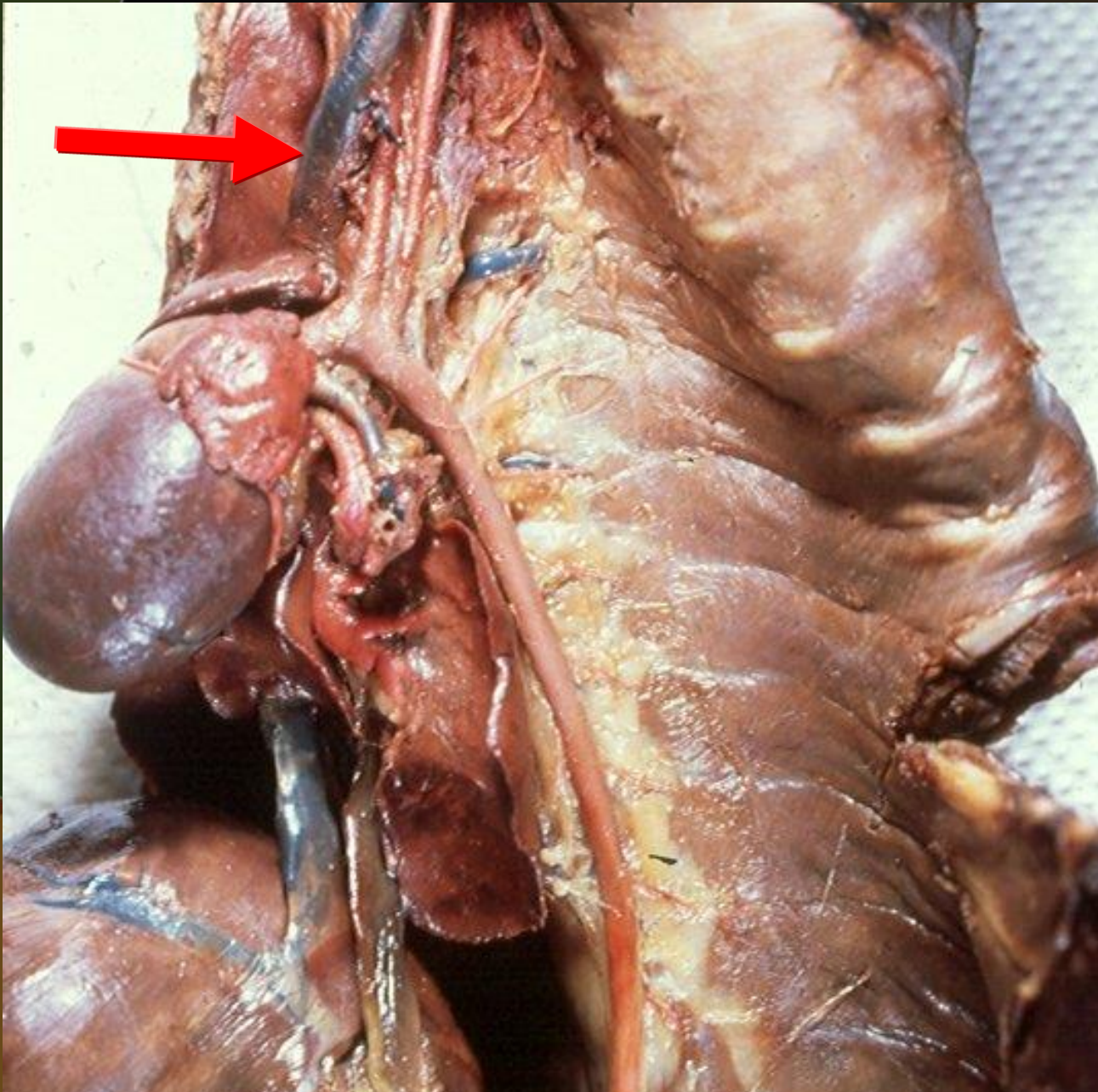
Left subclavian artery



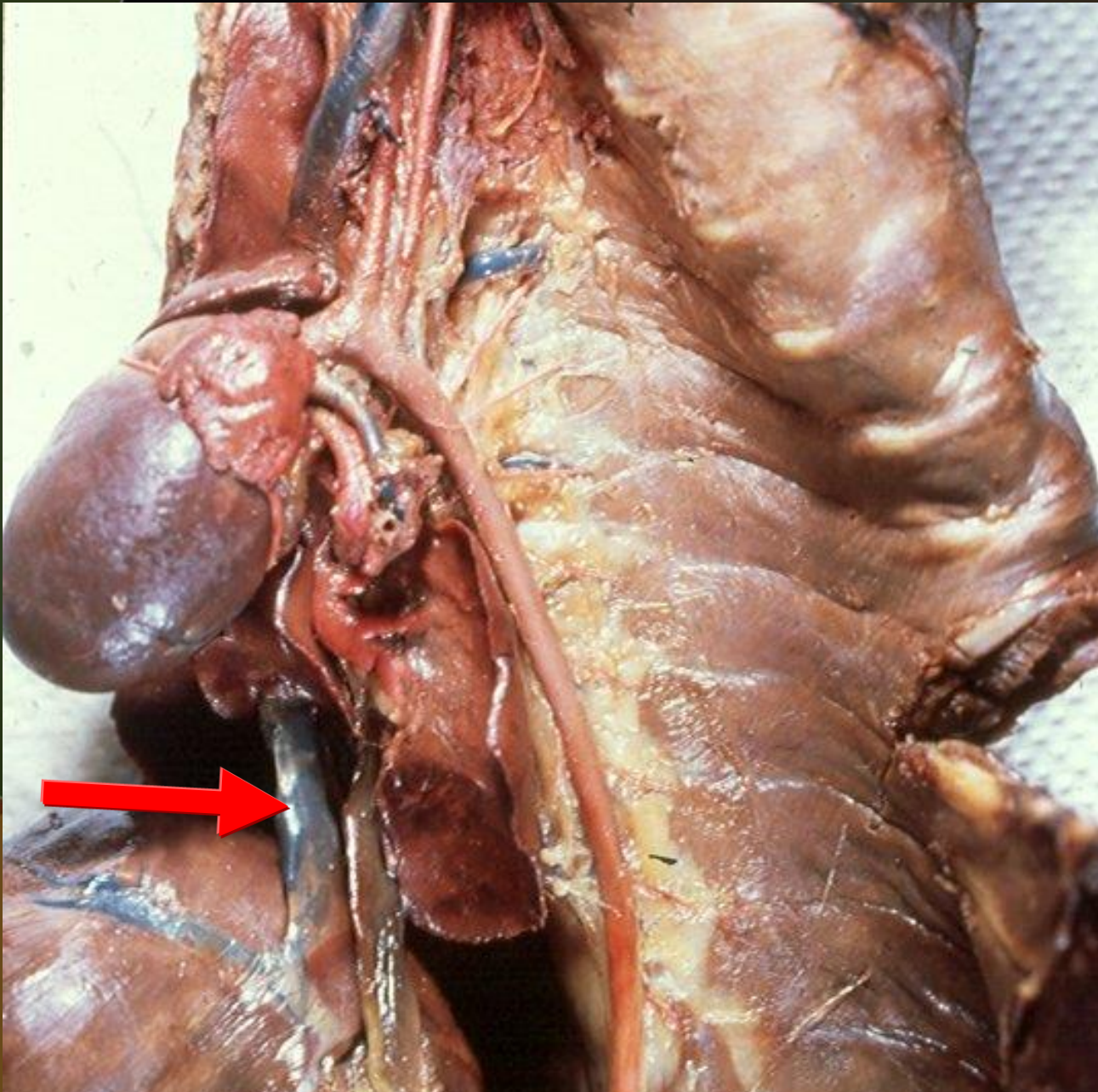
Brachiocephalic artery



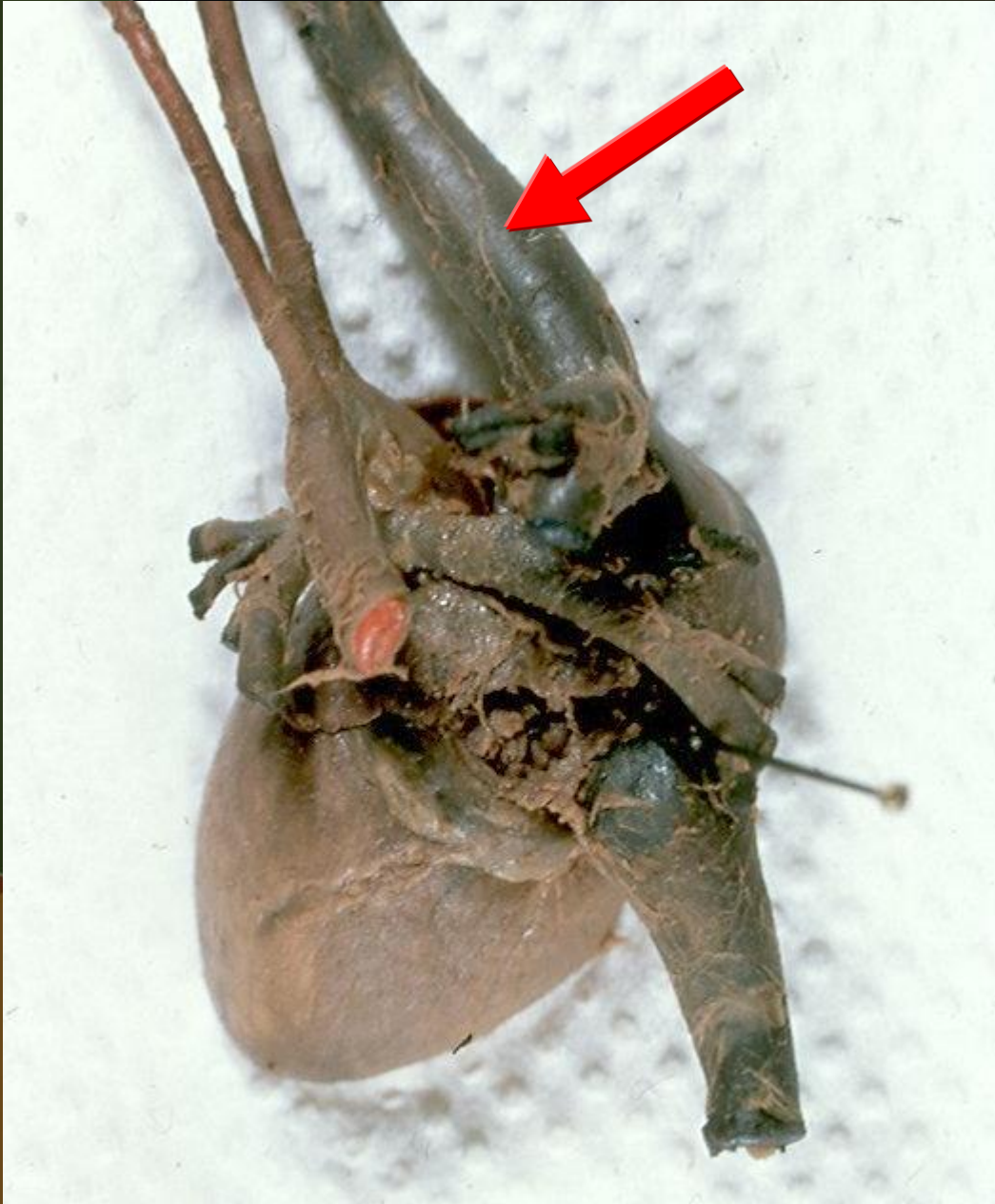
Precava



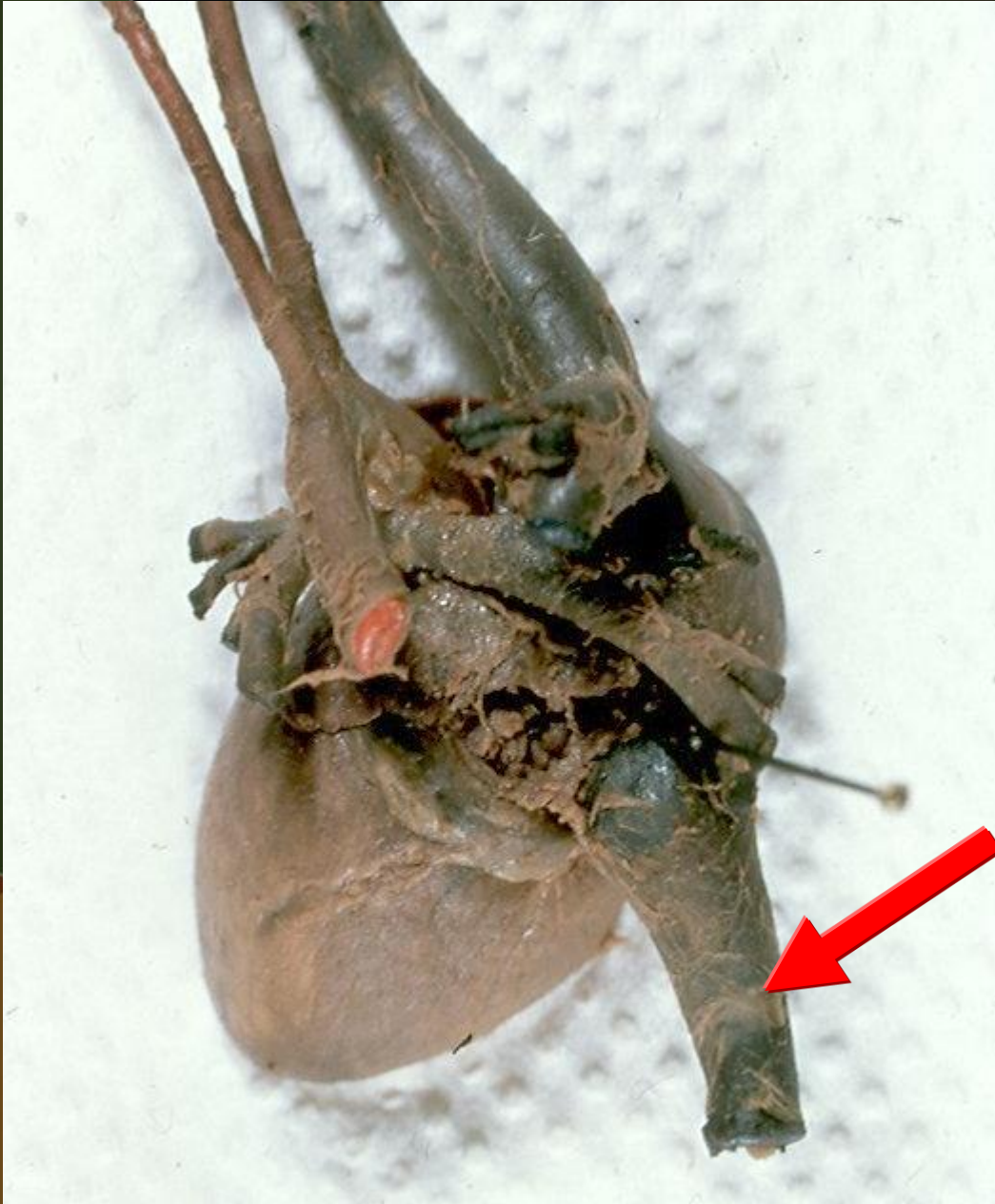
Postcava



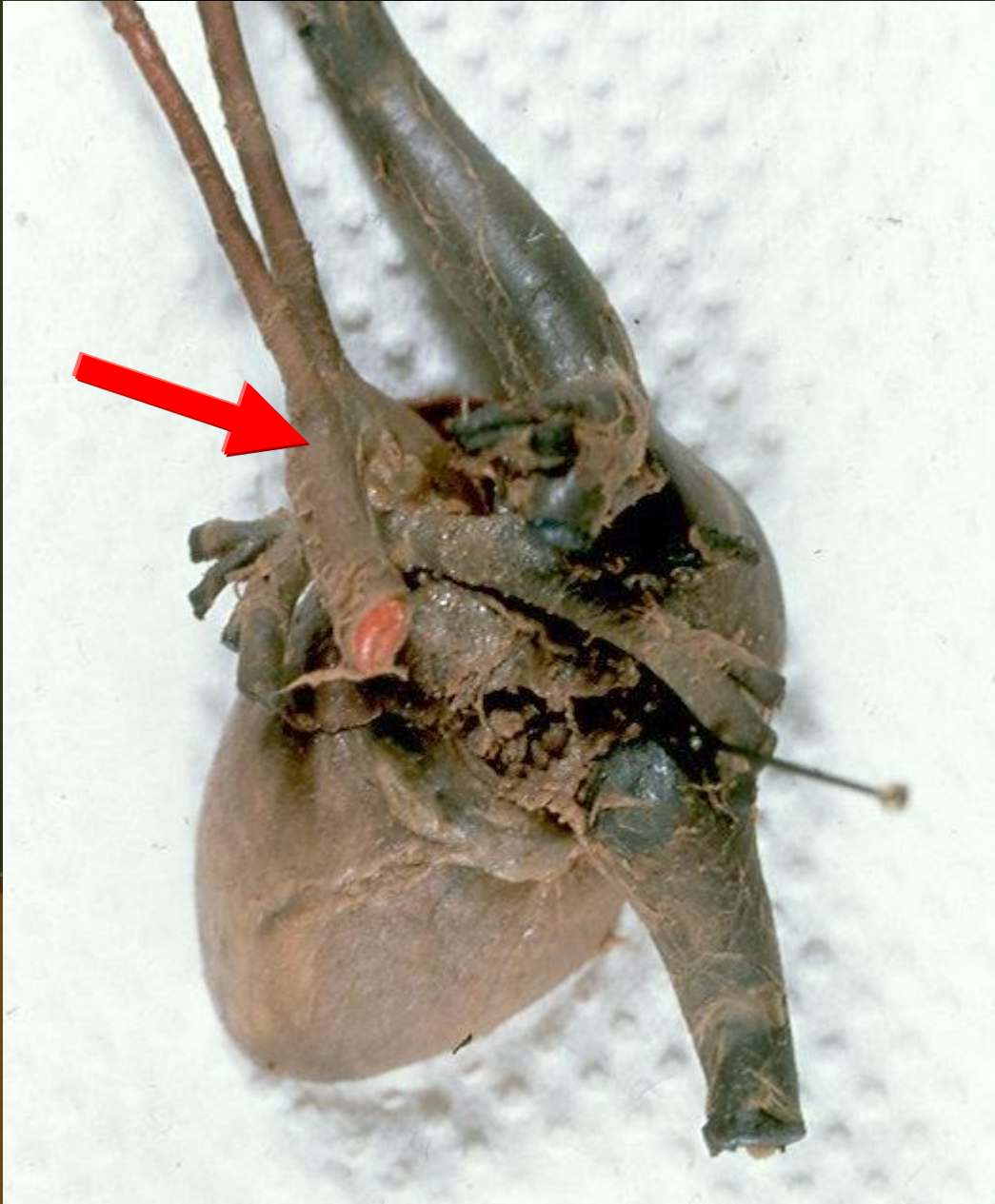
Precava



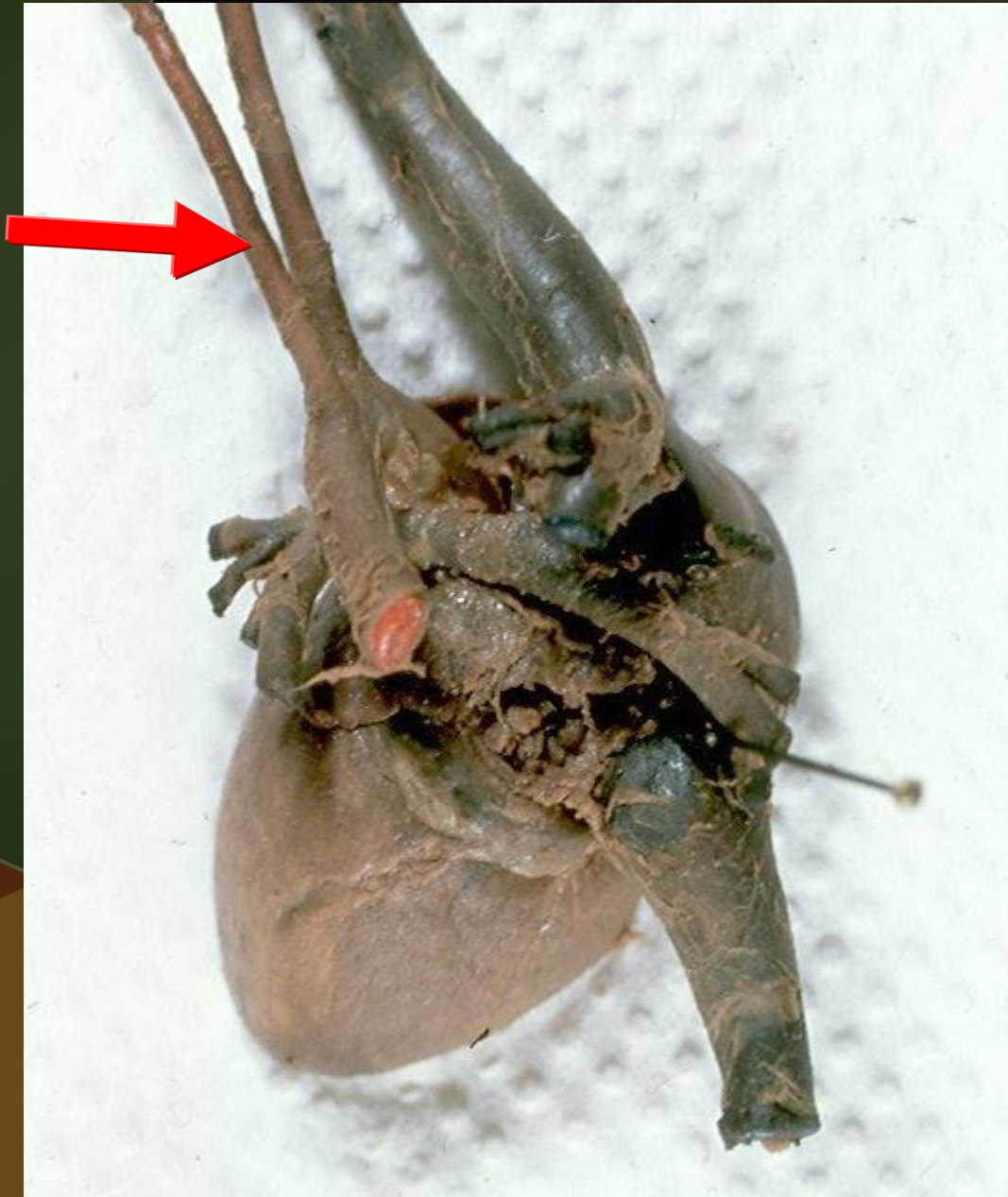
Postcava



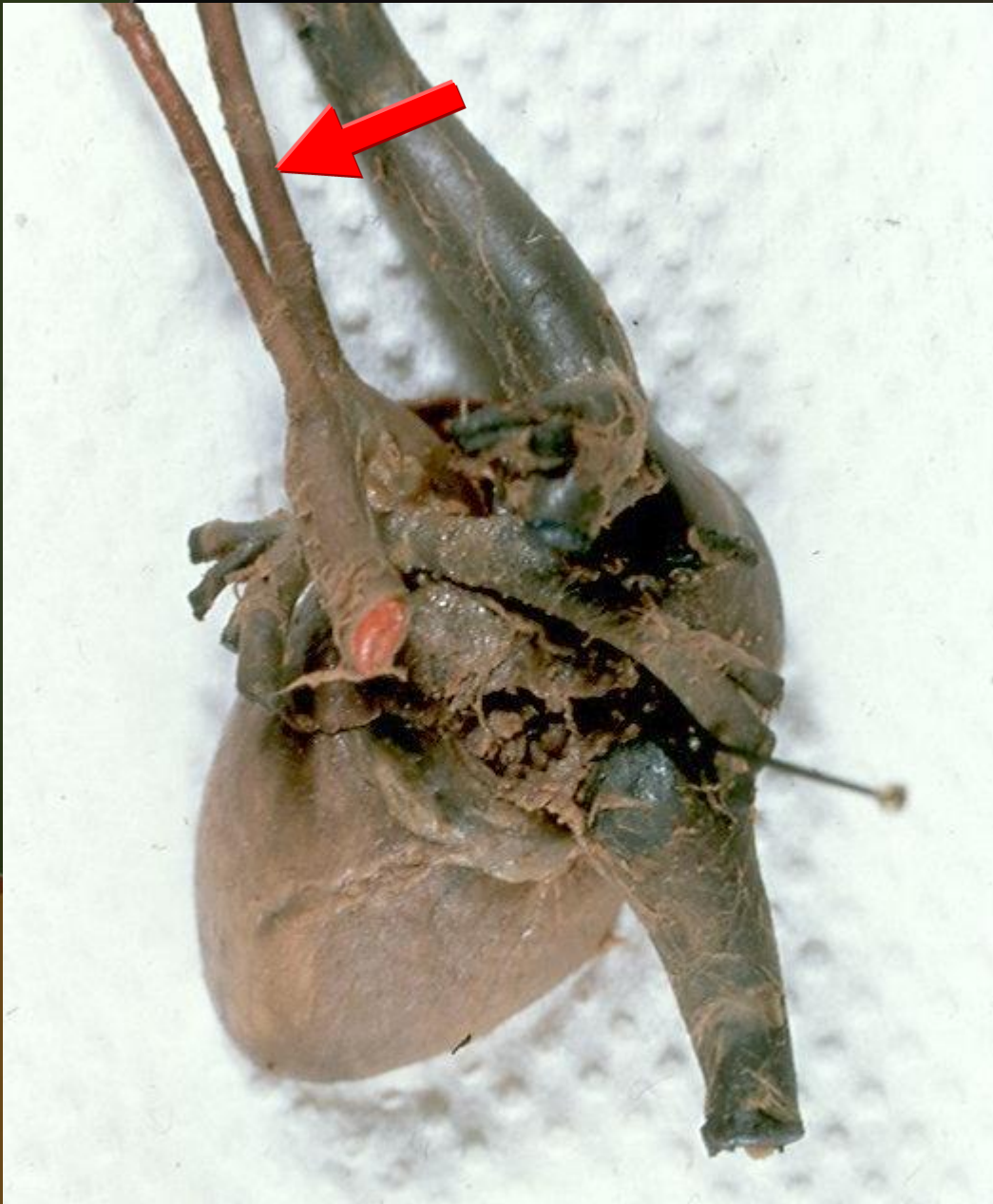
Aortic arch



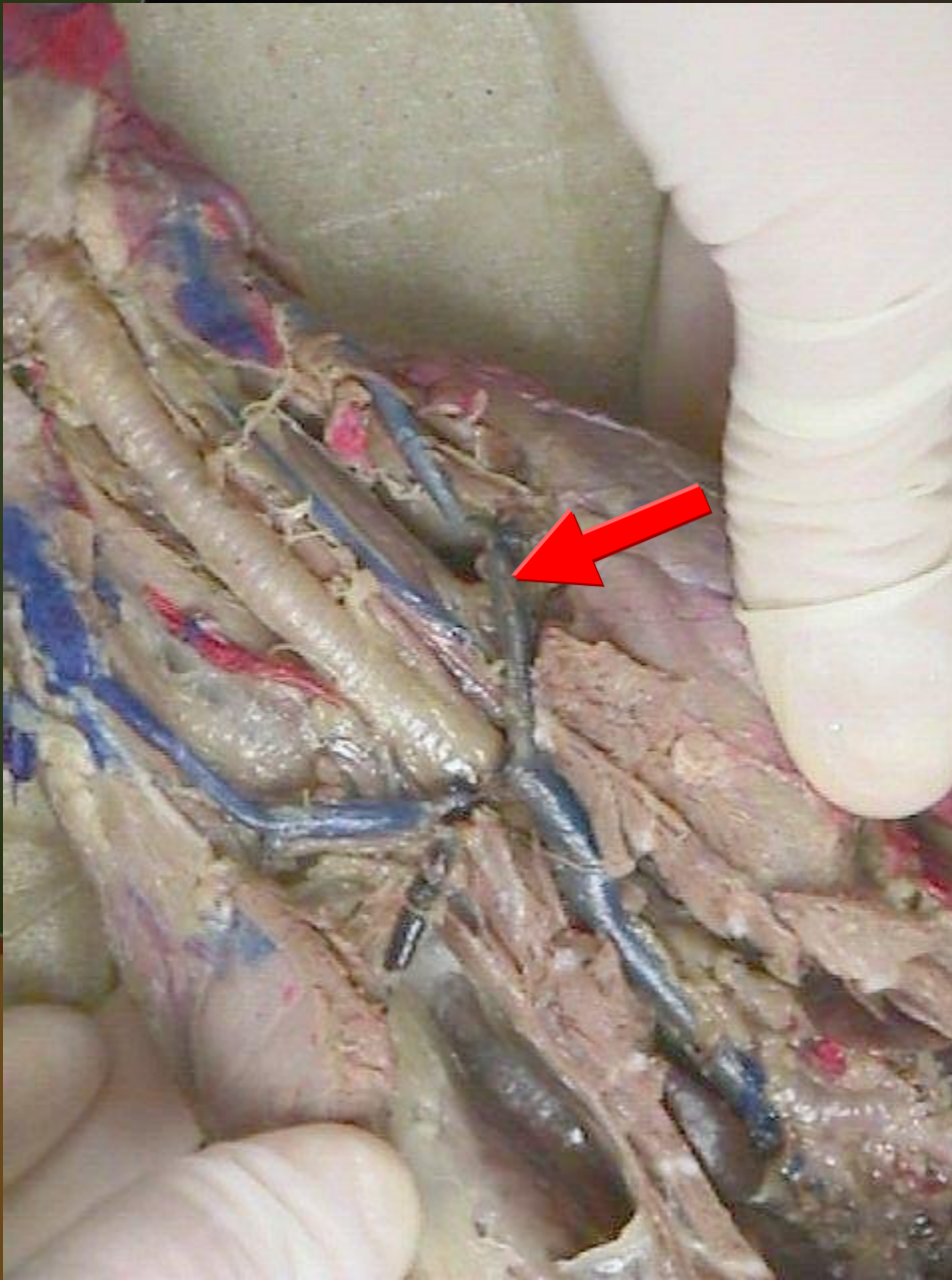
Left subclavian artery



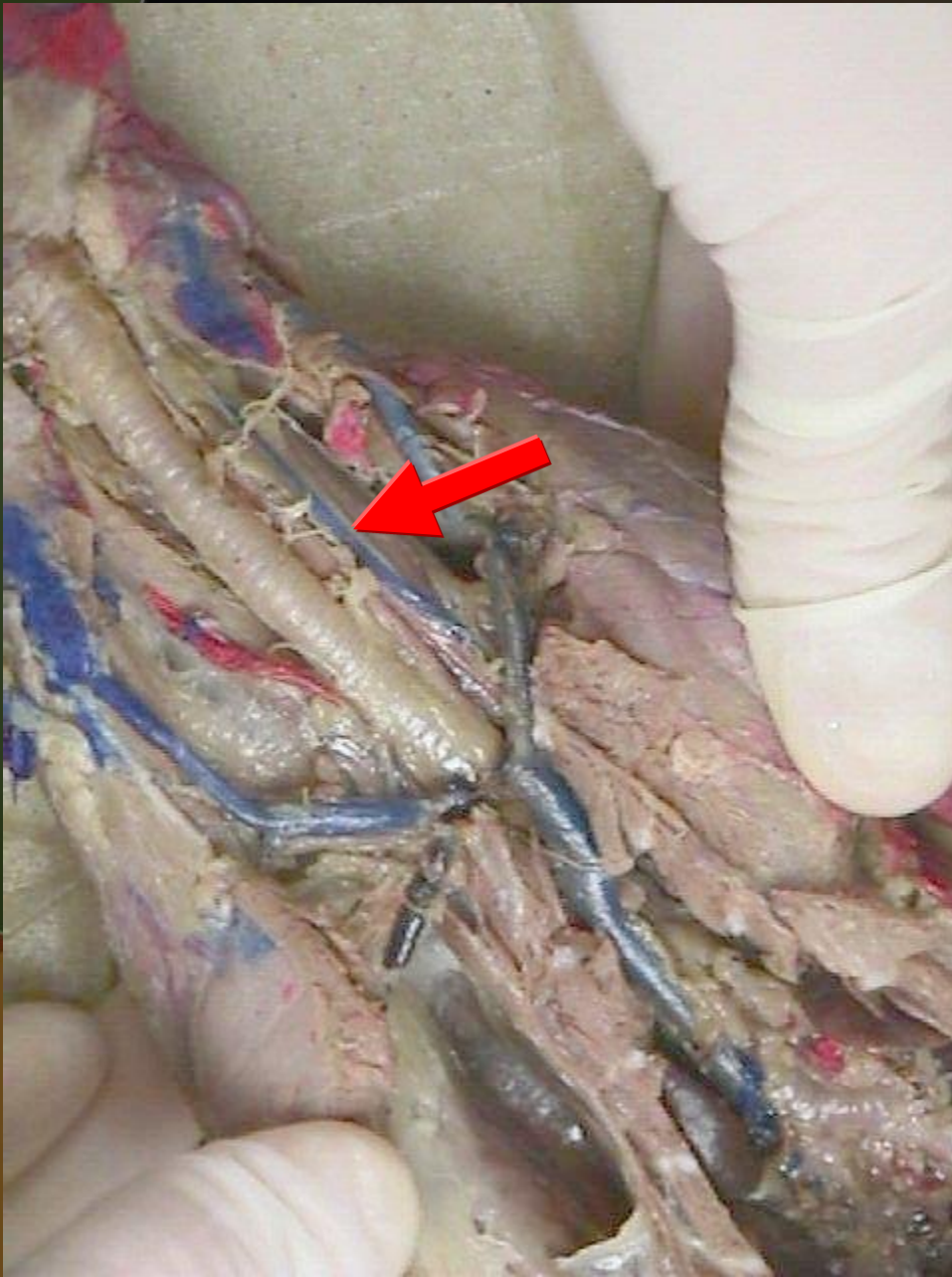
Brachiocephalic artery



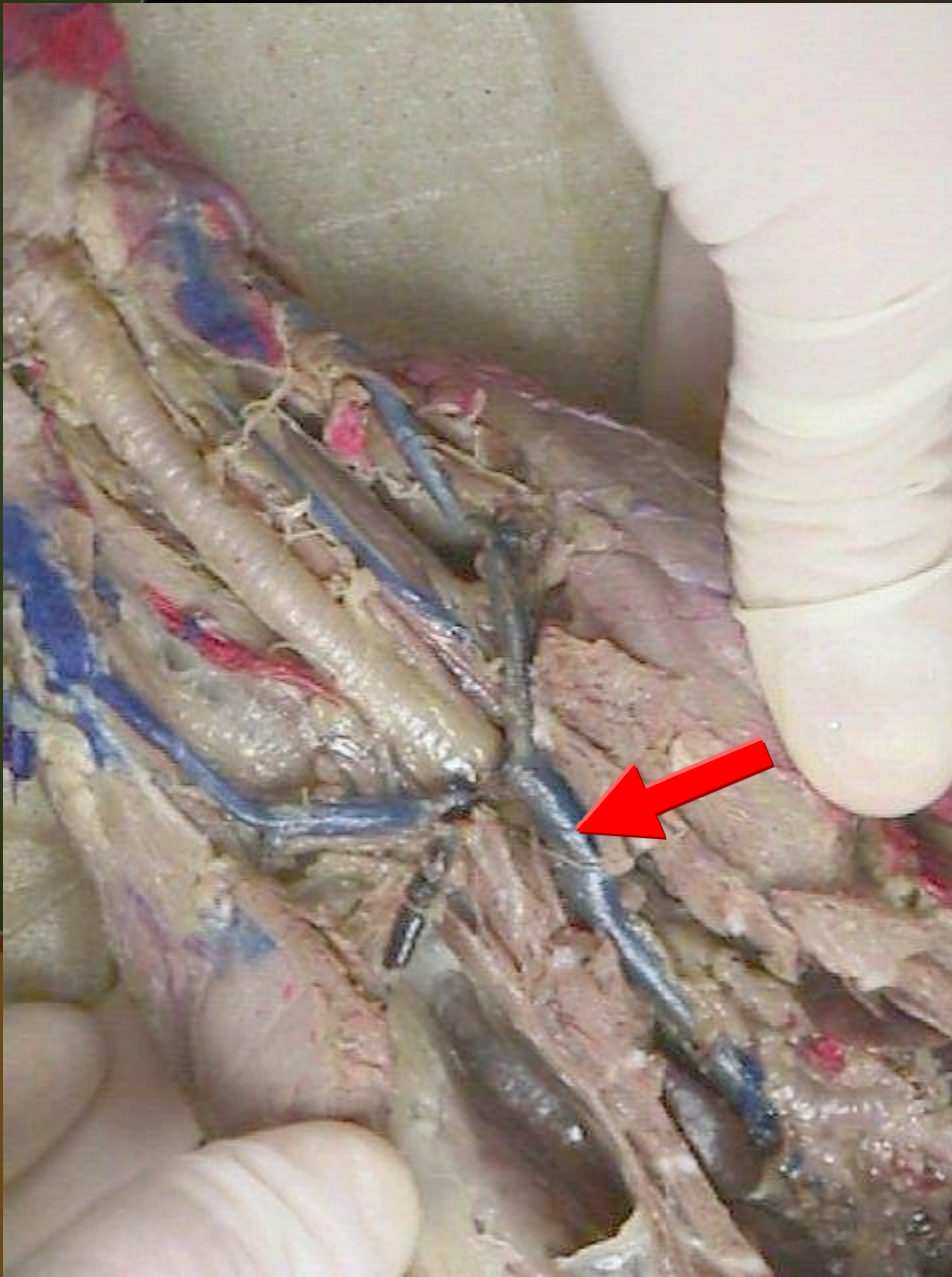
External jugular



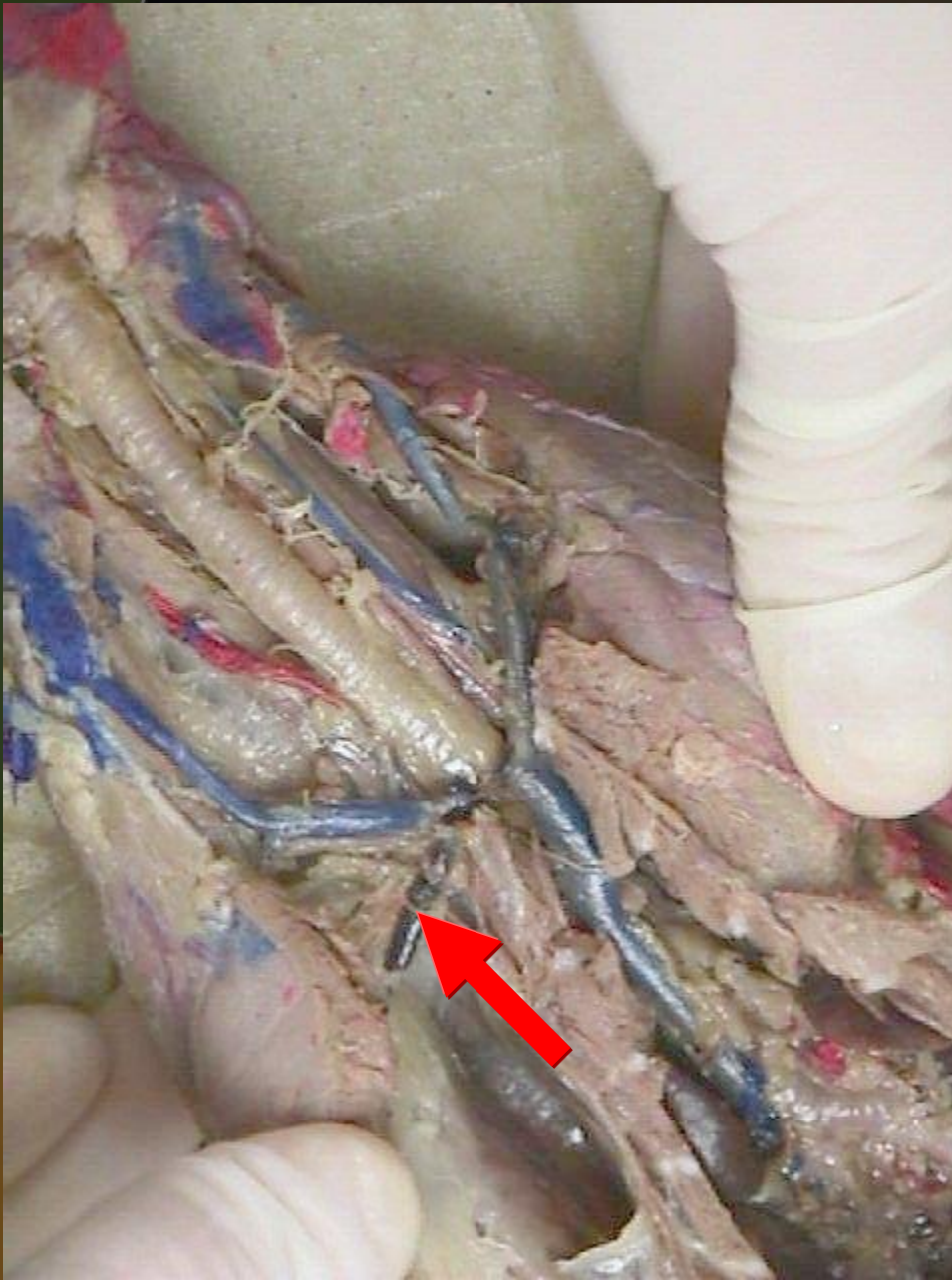
Internal jugular



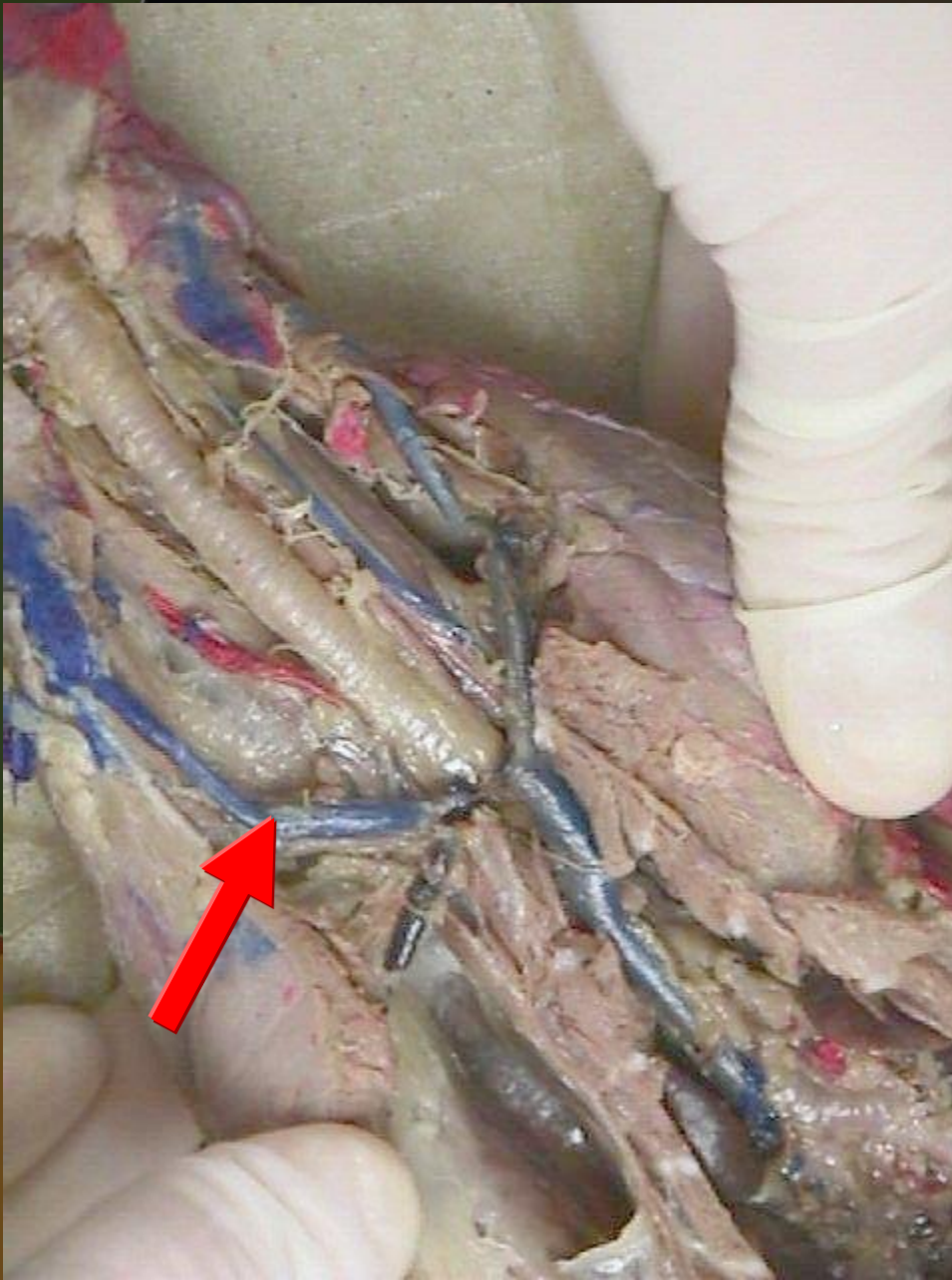
Precava



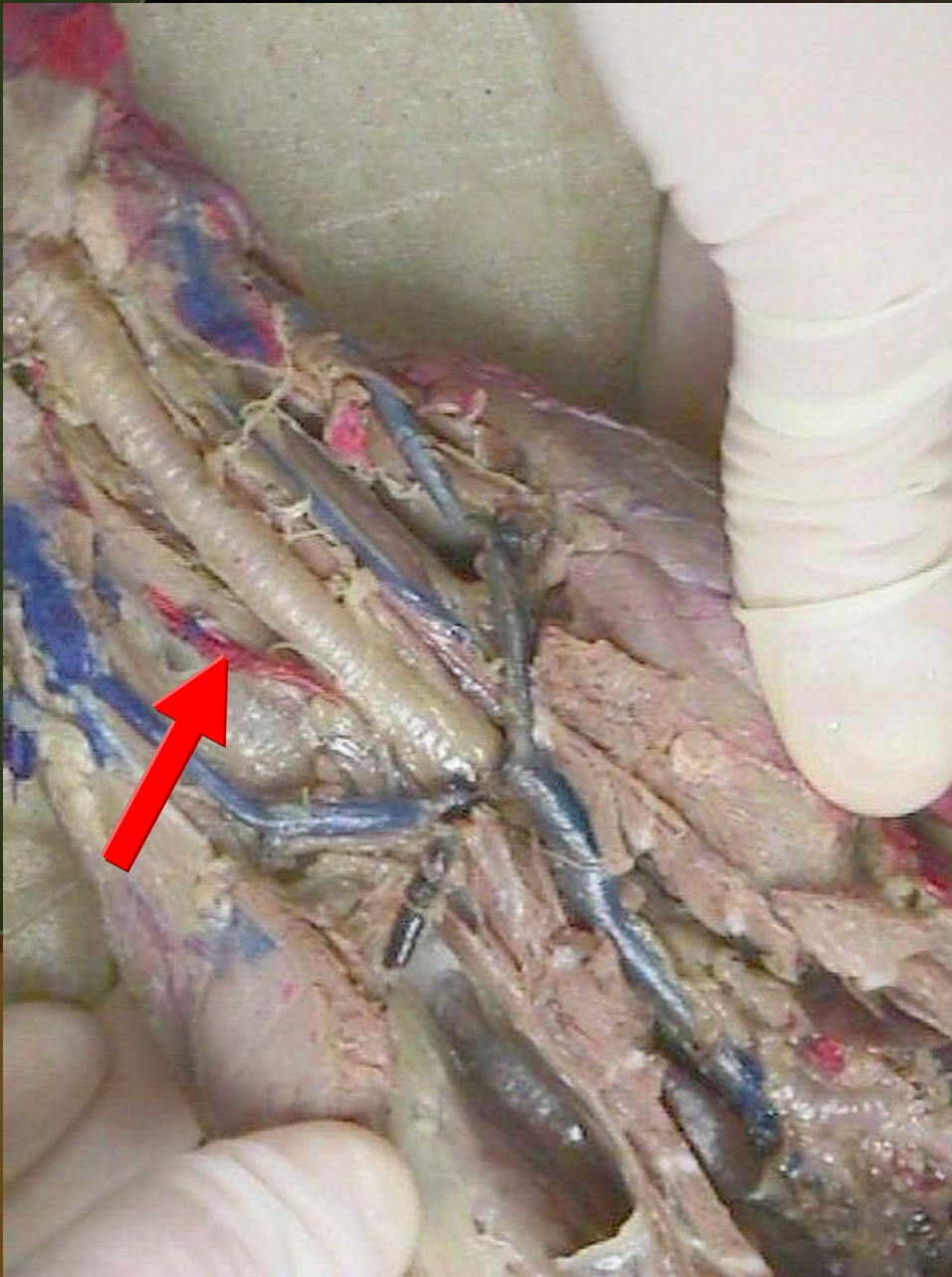Subclavian vein



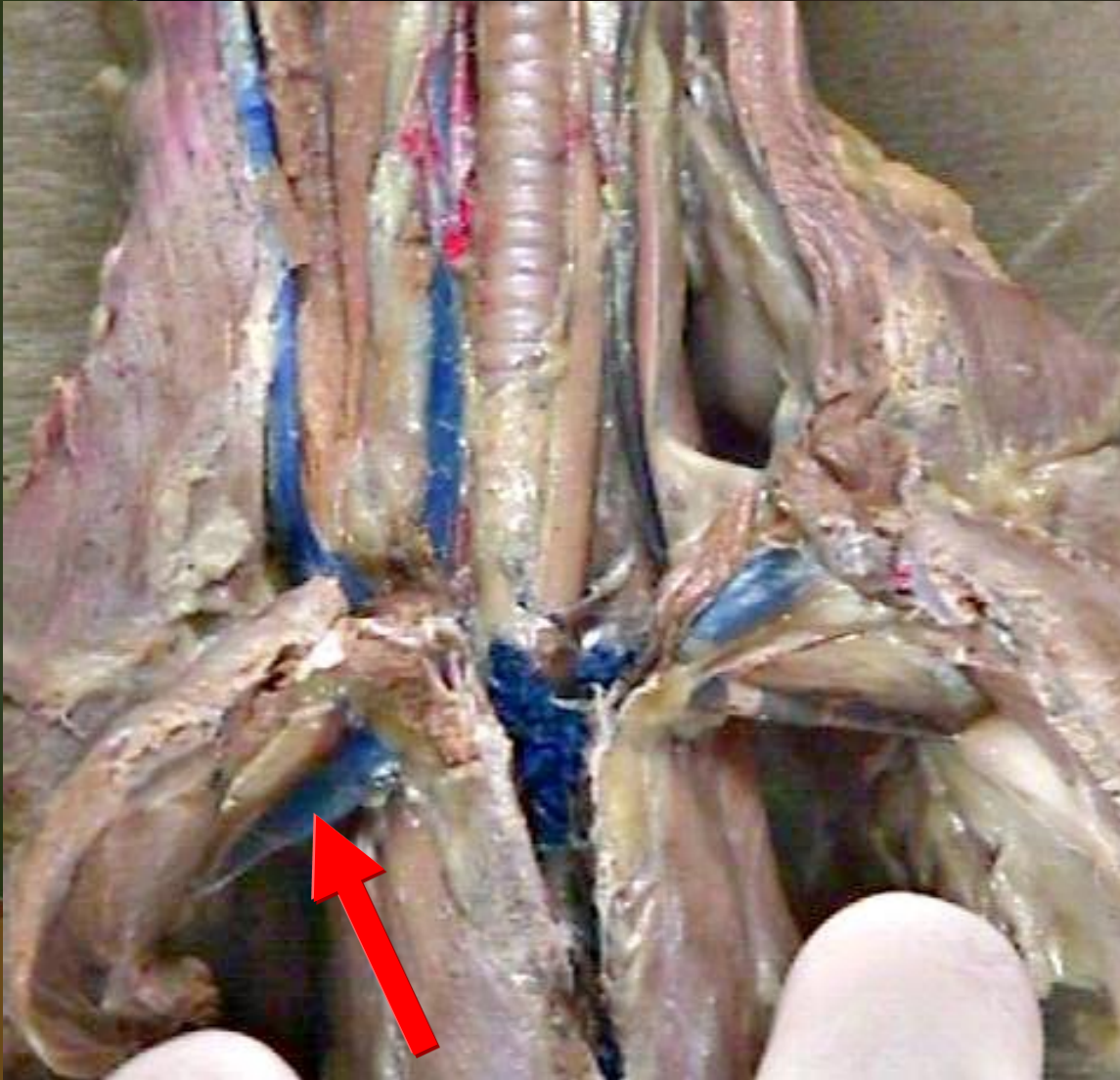
External jugular



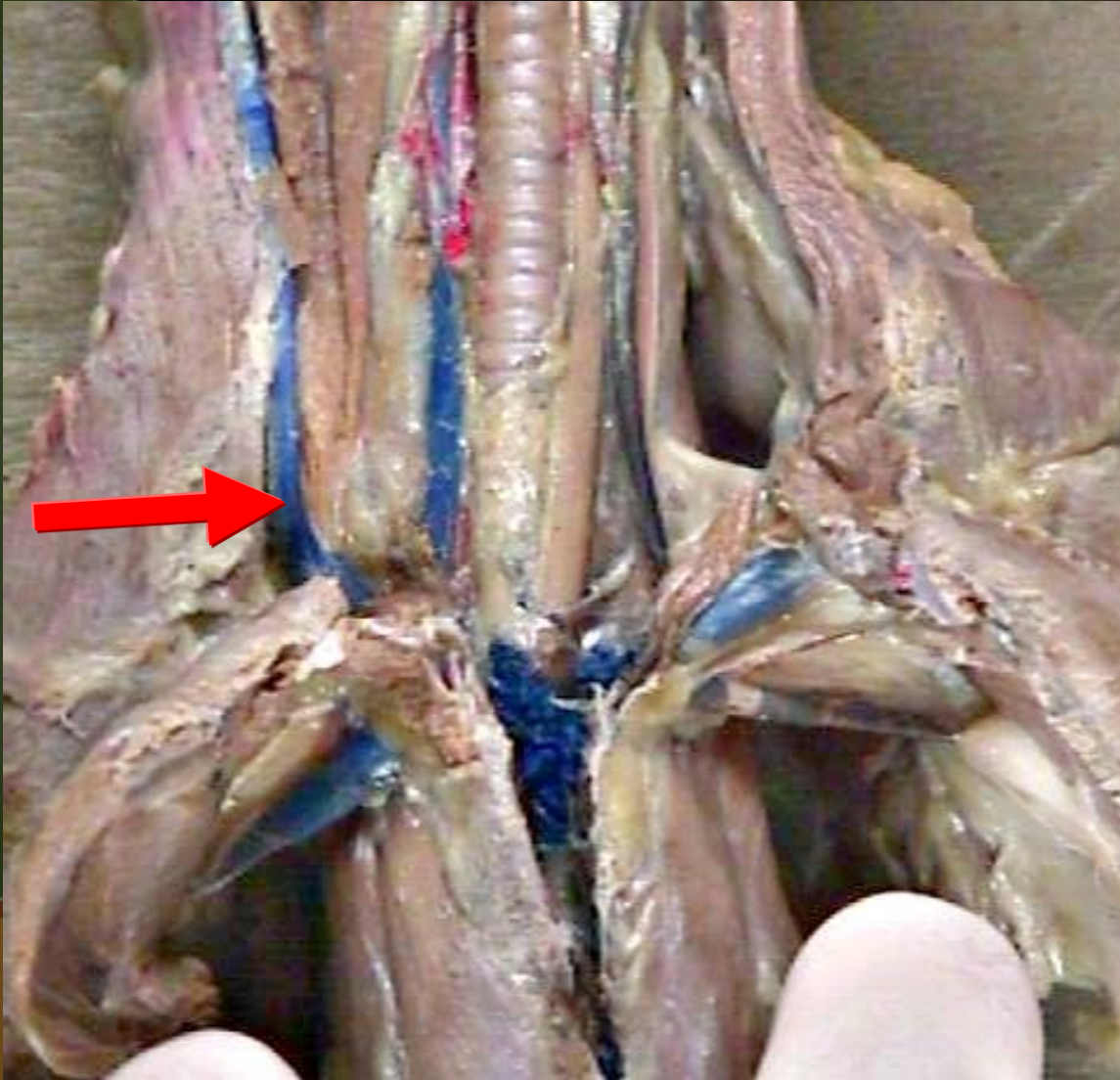
Common carotid



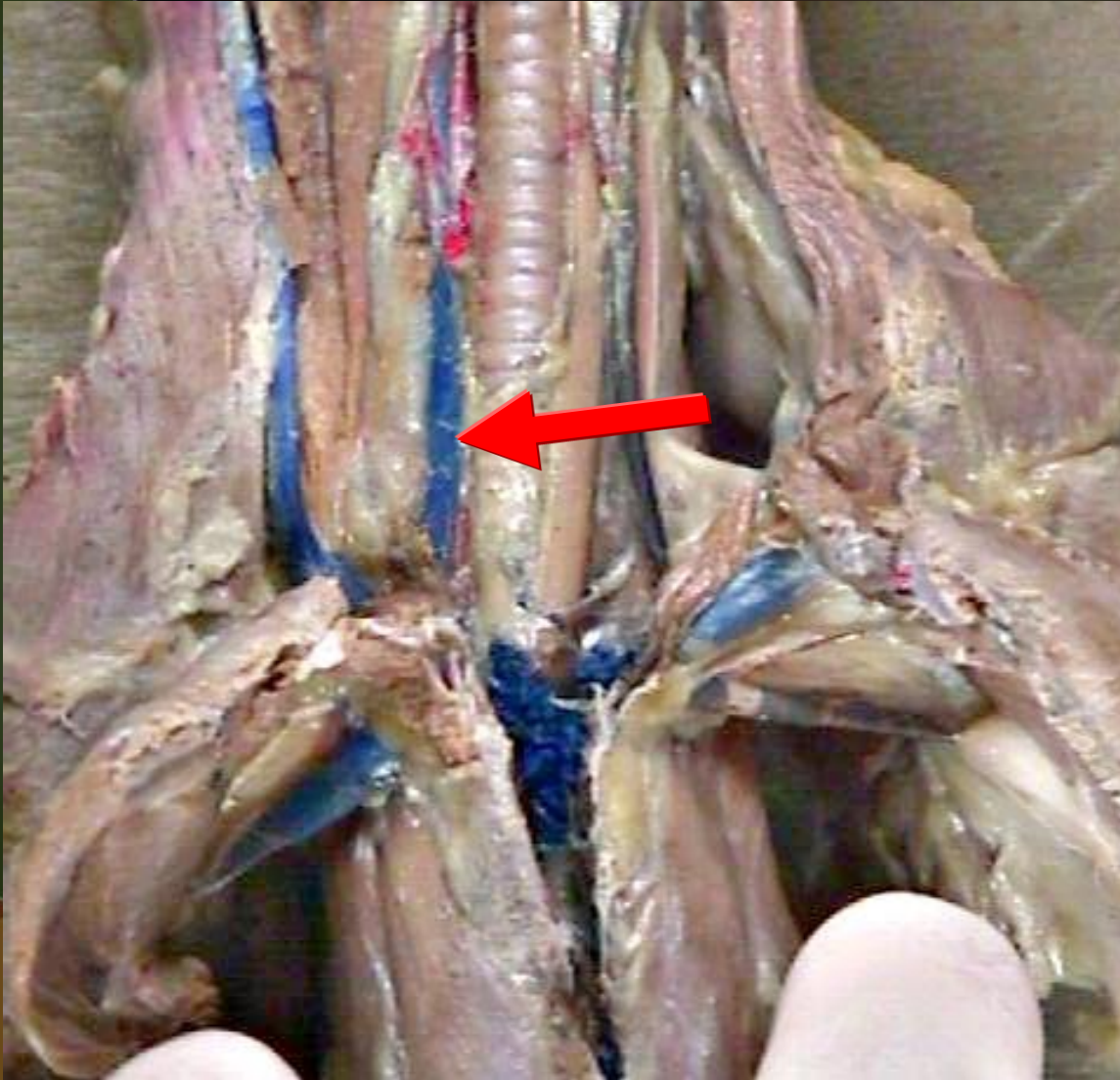
Subclavian vein



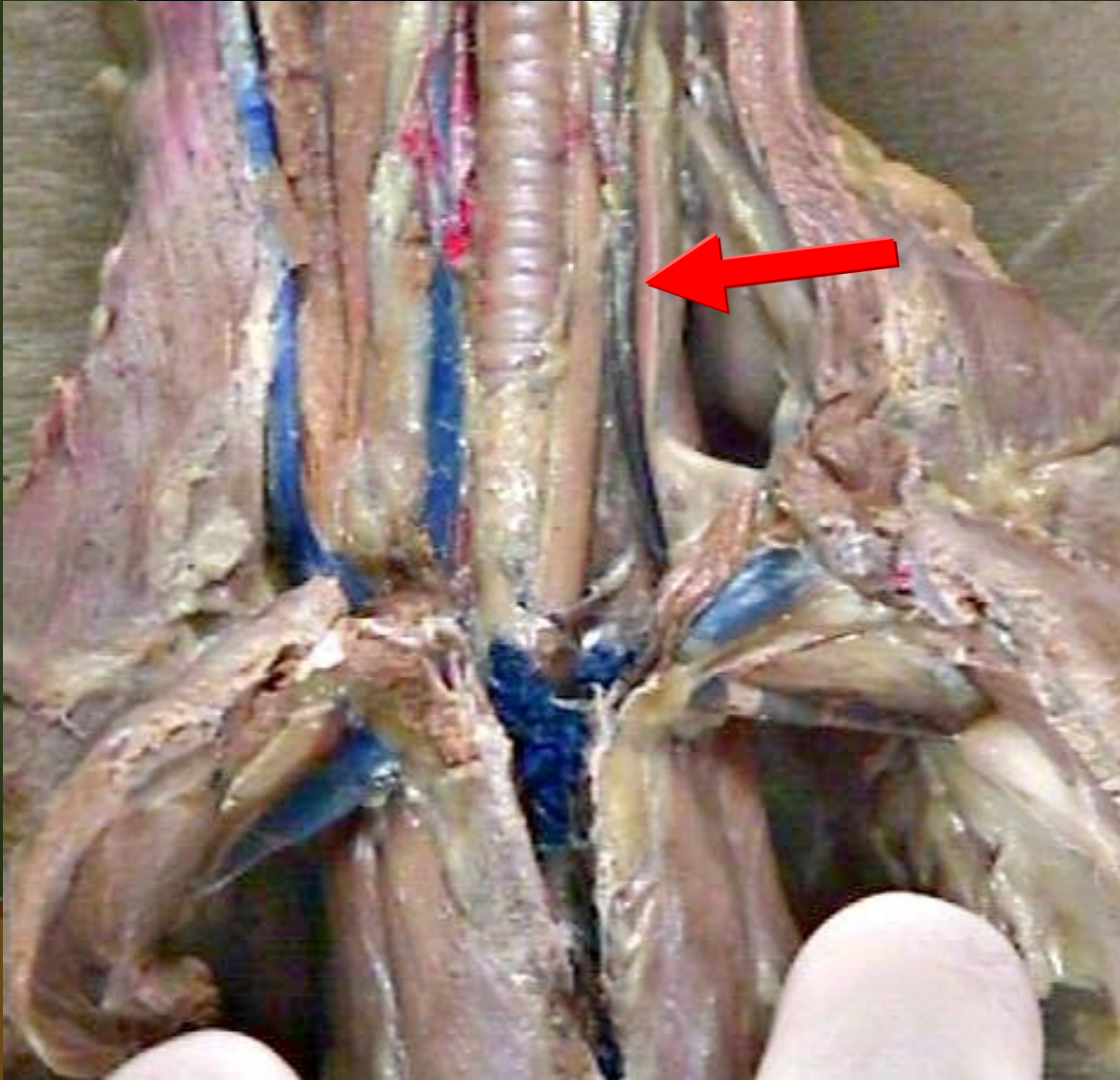
External jugular



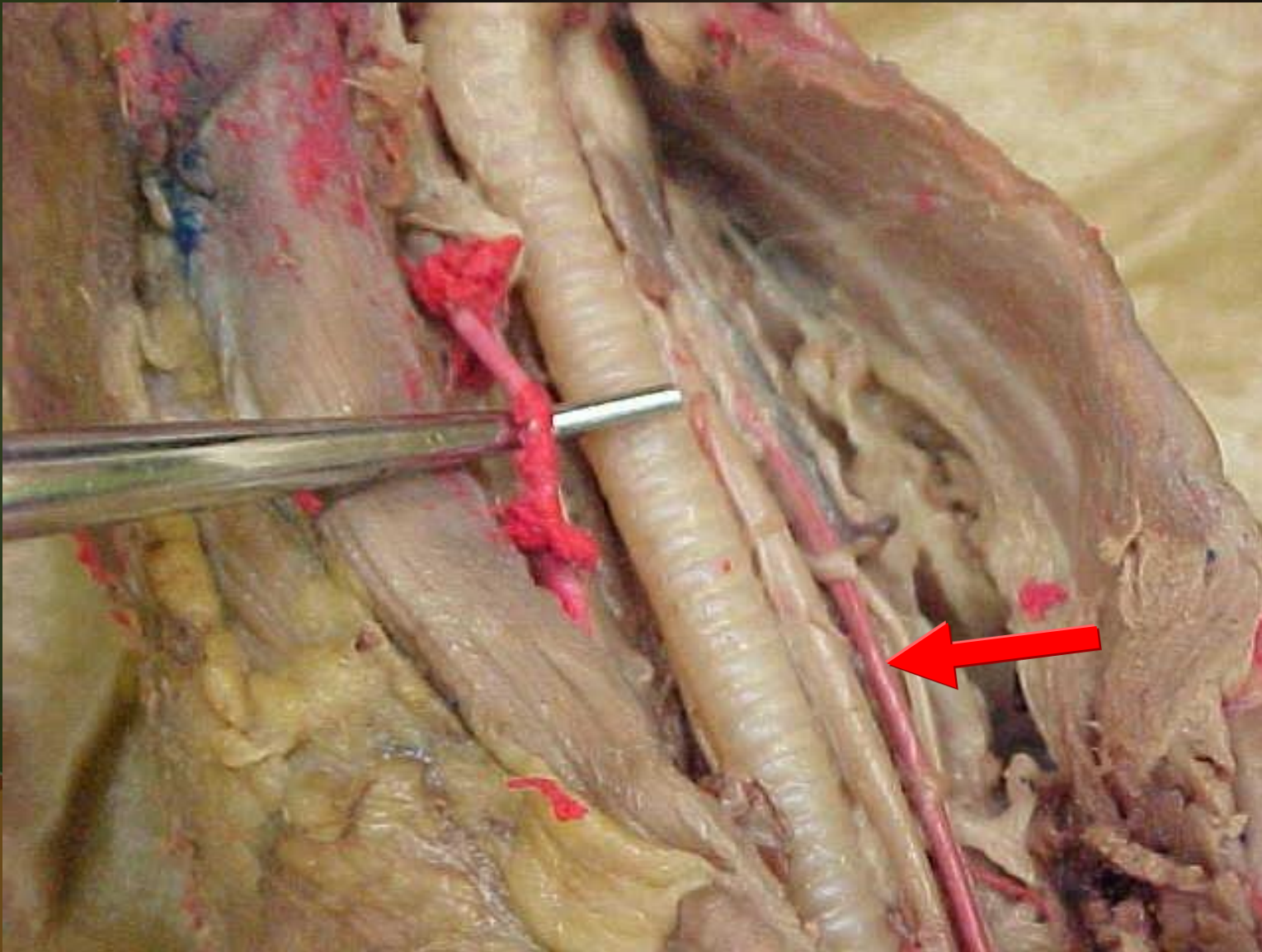
Internal jugular



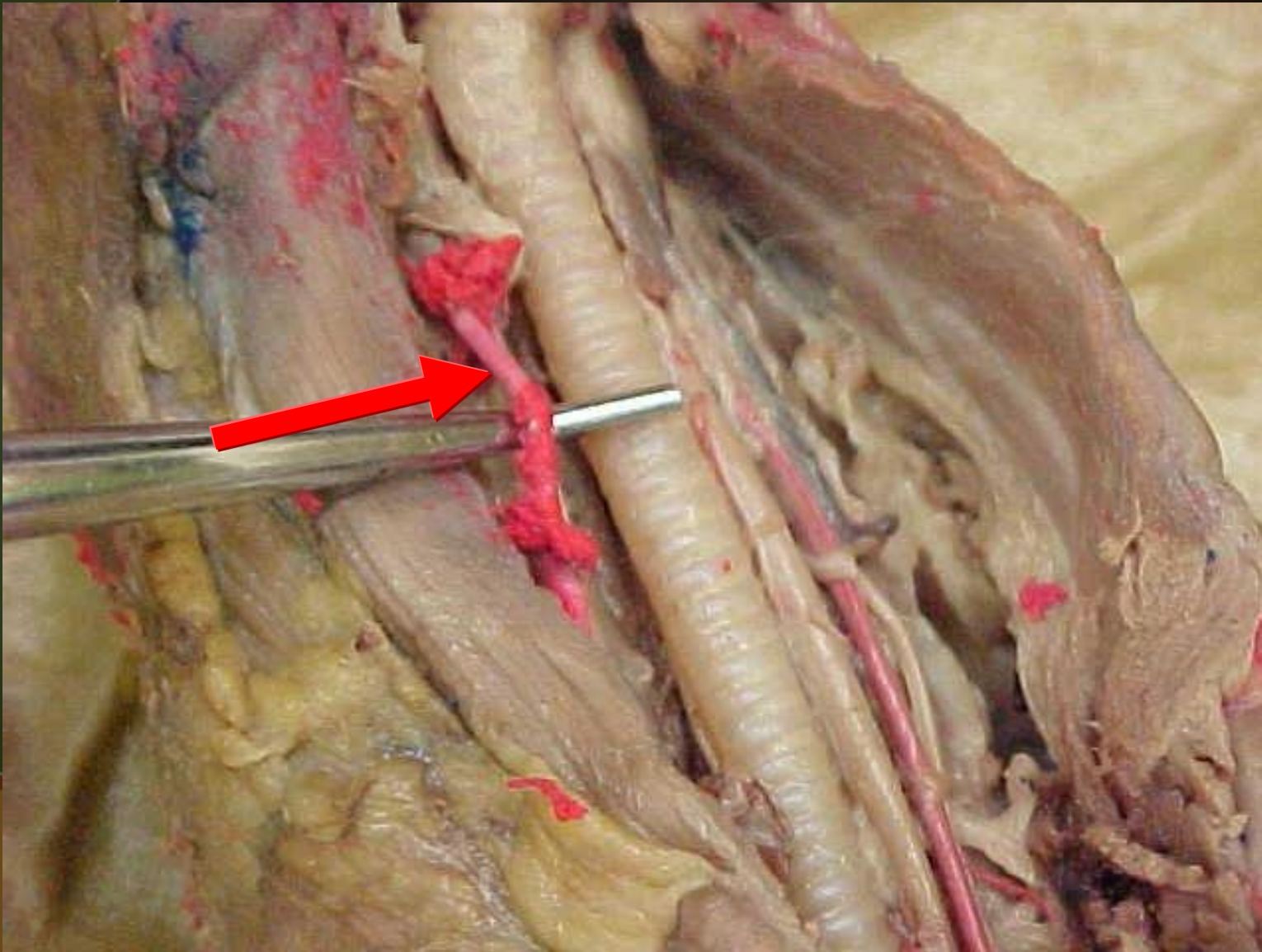
Common carotid



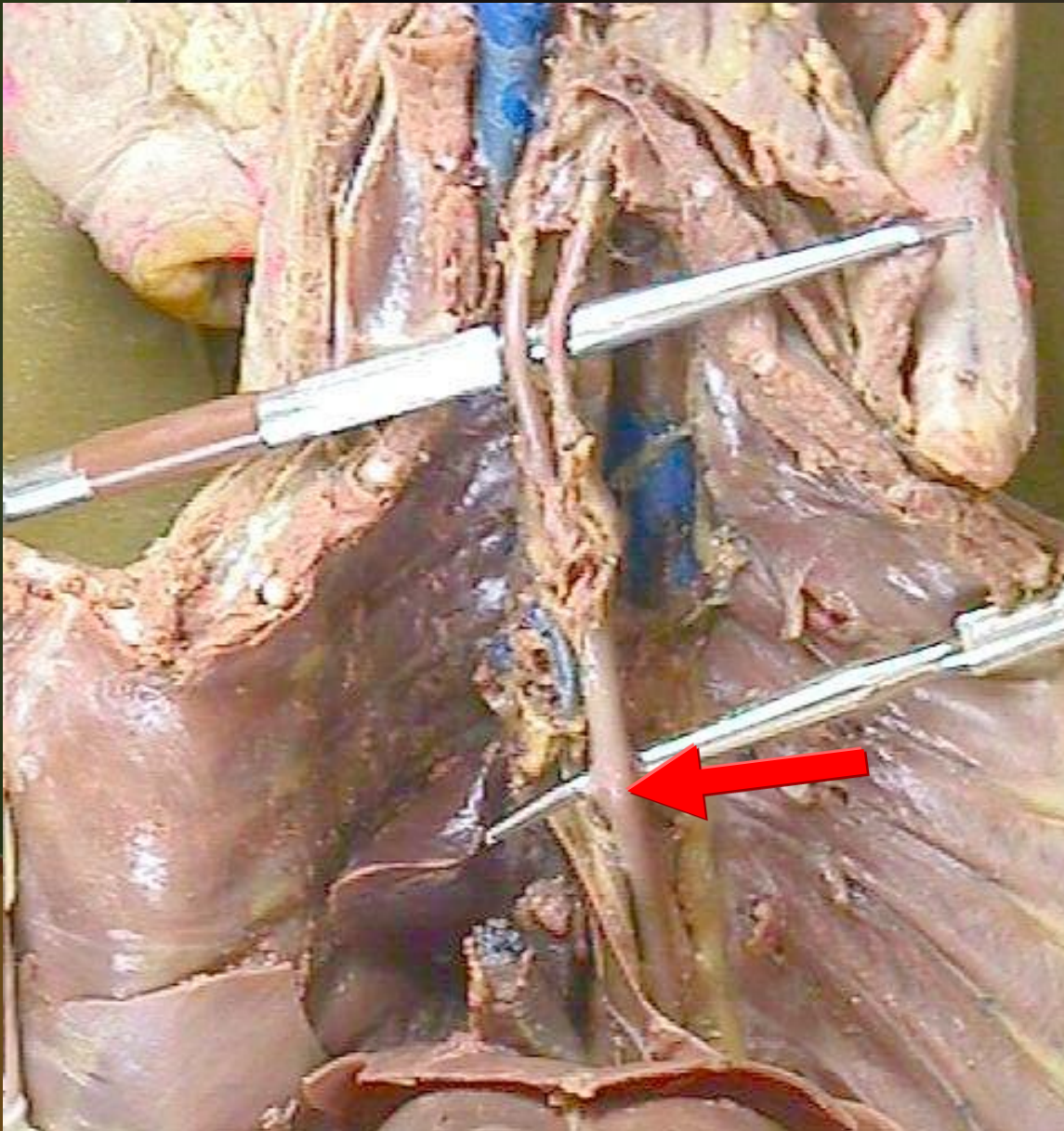
Common carotid



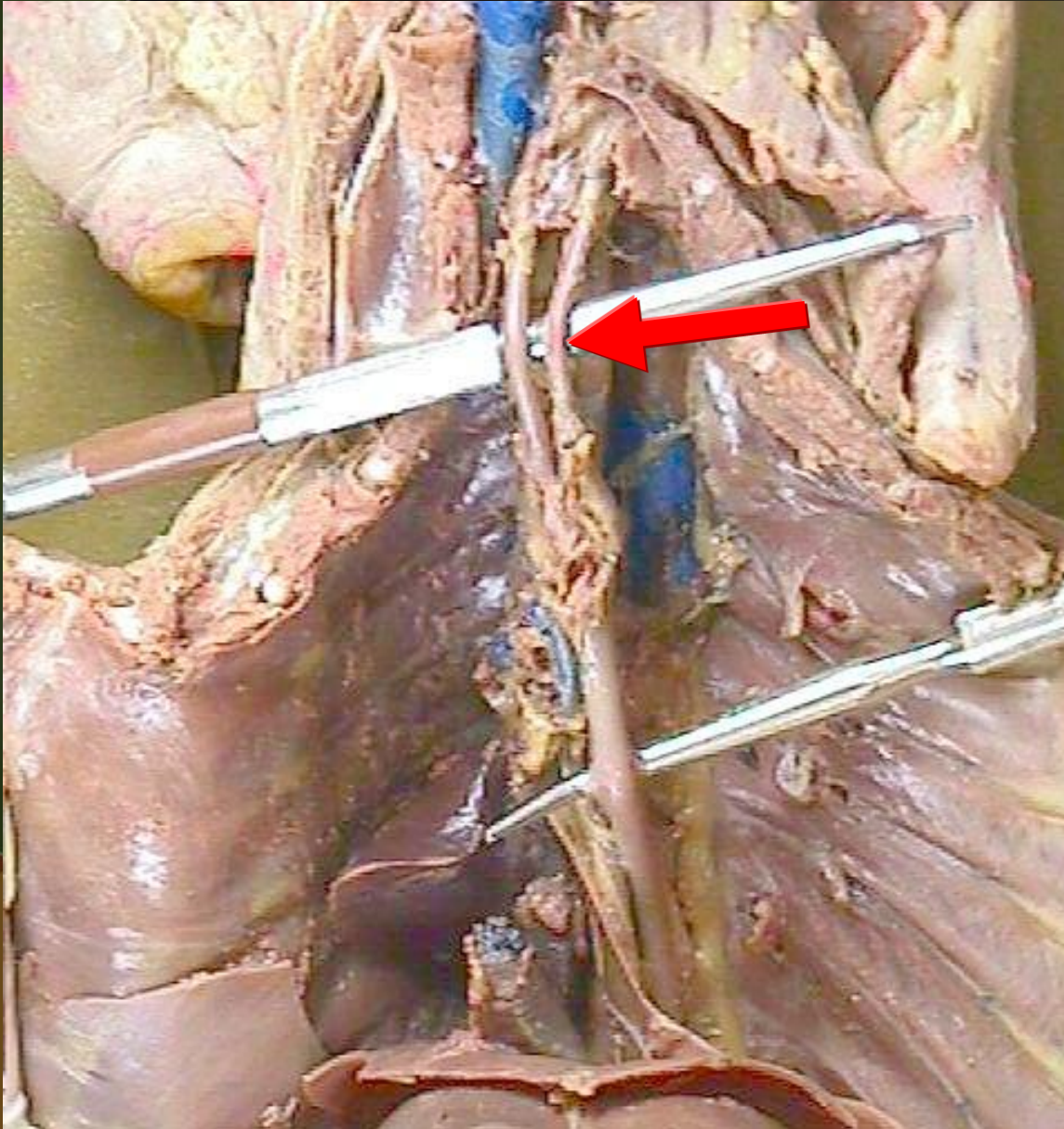
Common carotid



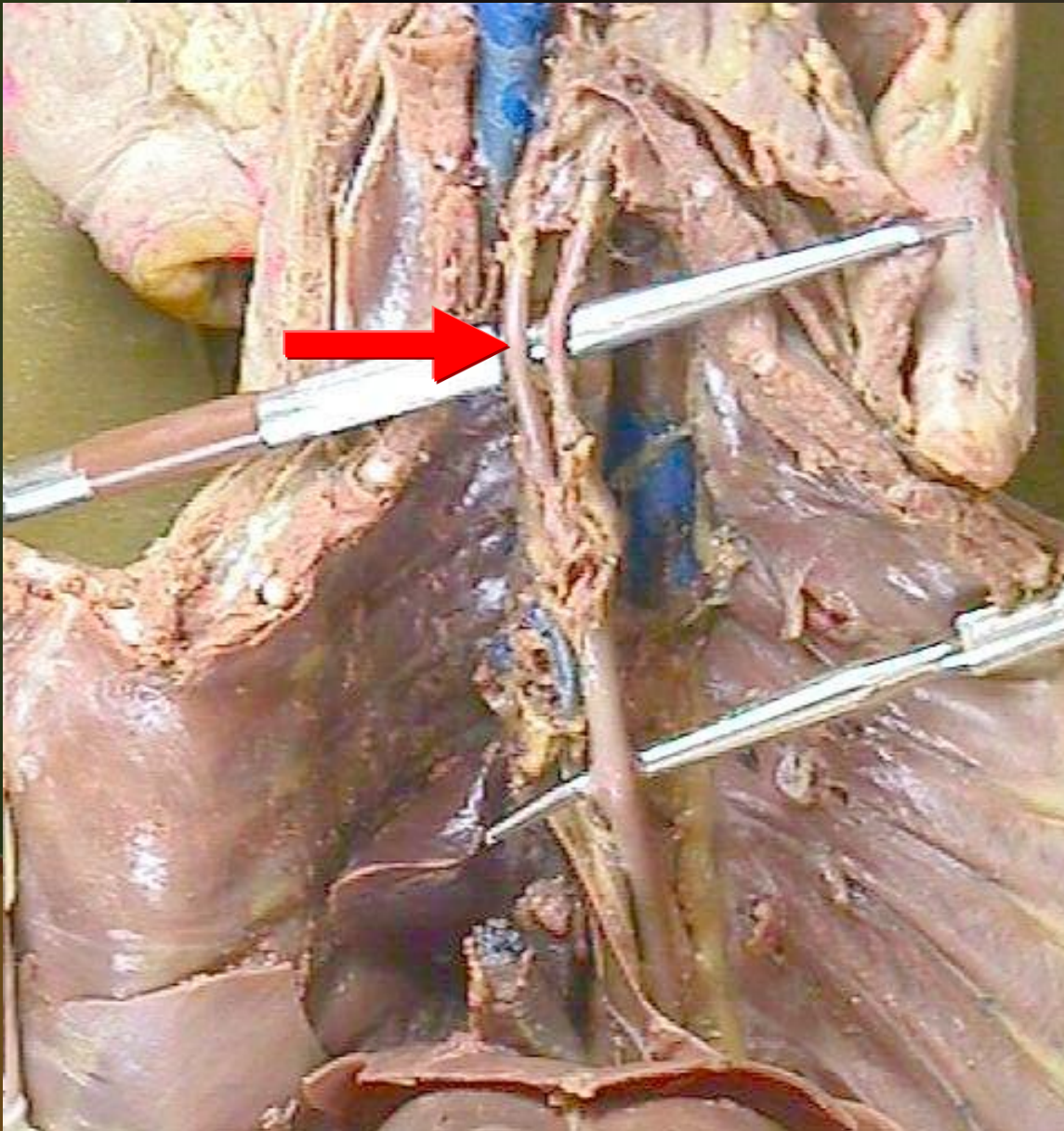
Thoracic aorta



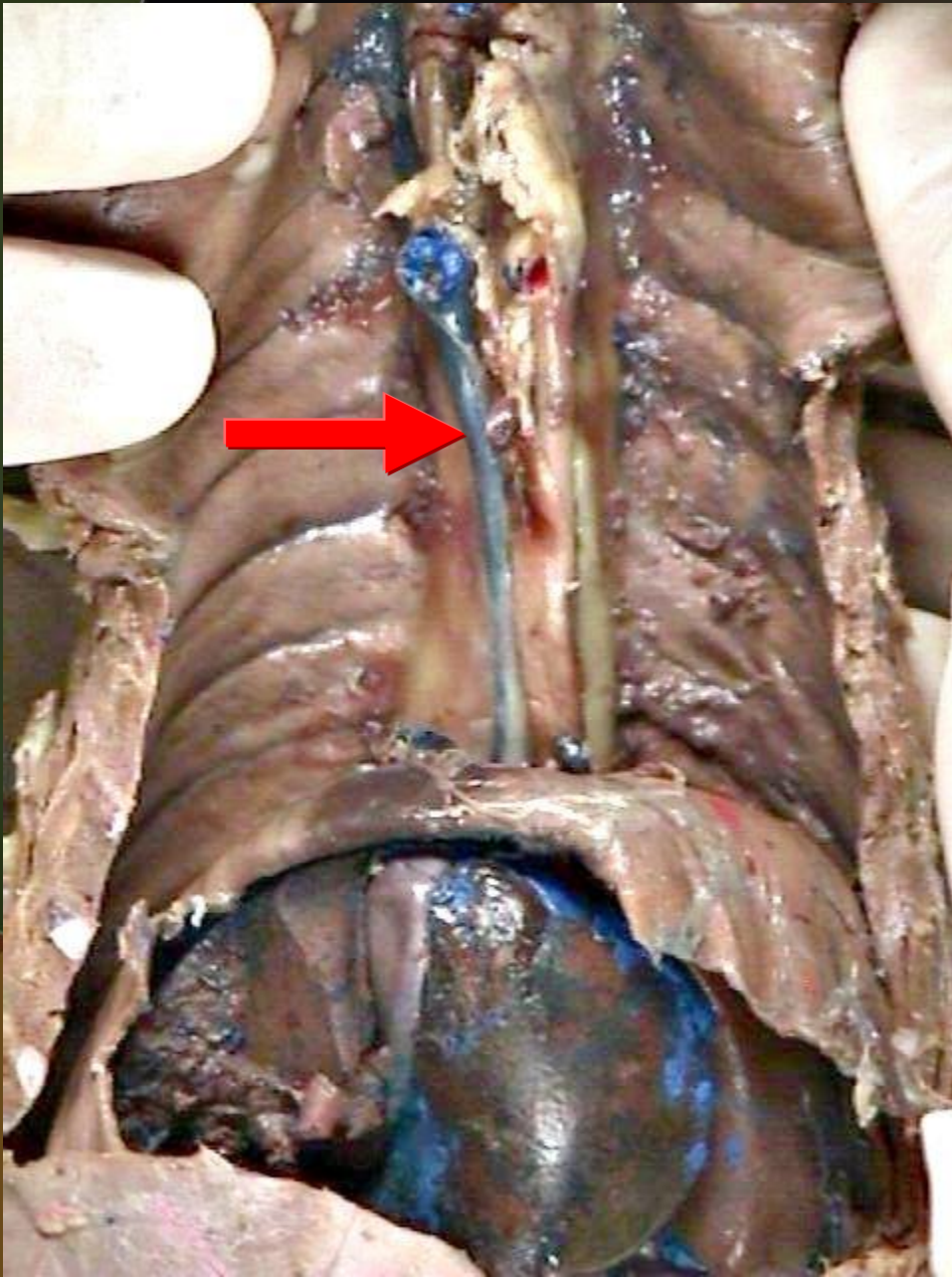
Left subclavian artery



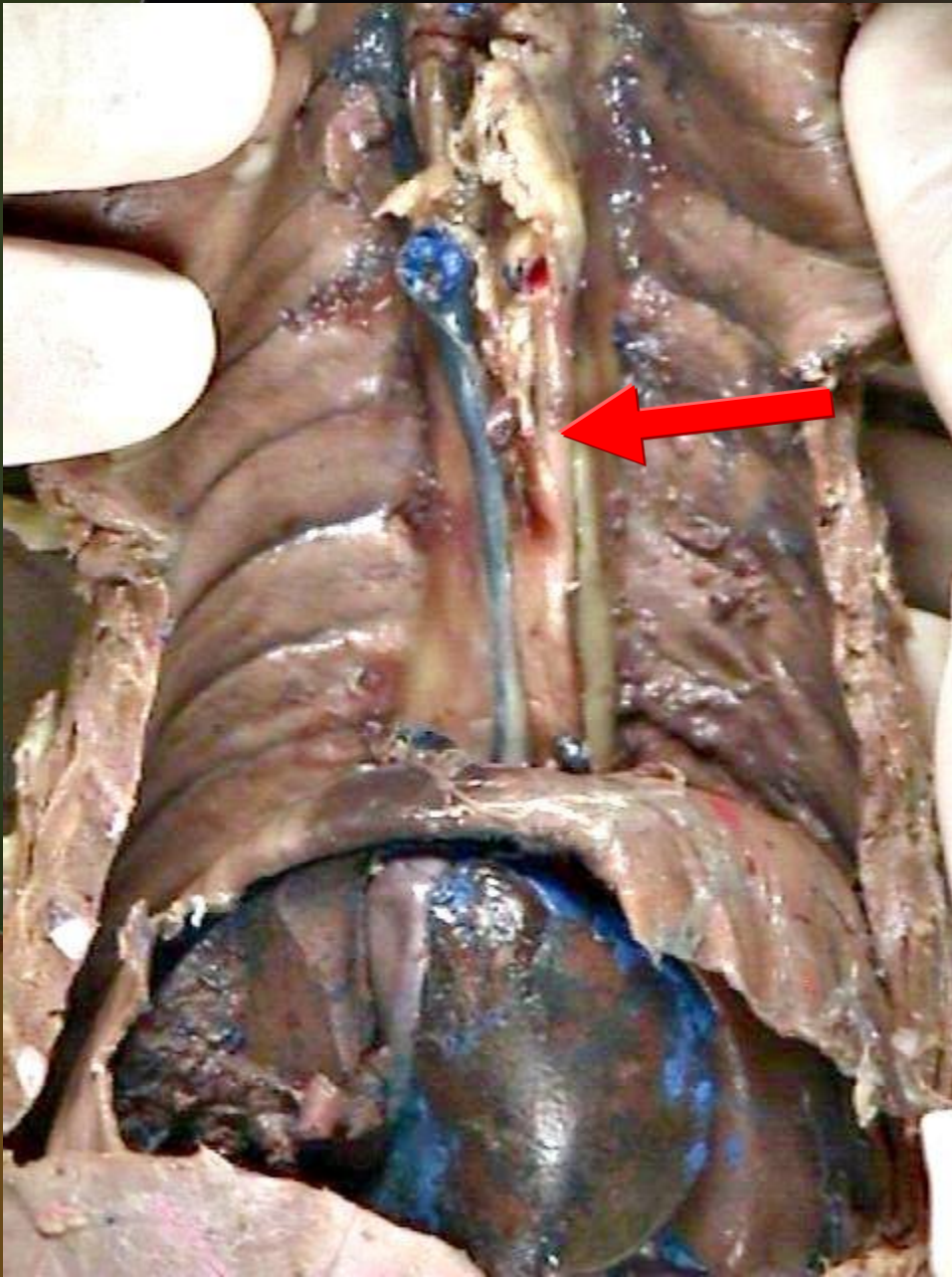
Brachiocephalic artery



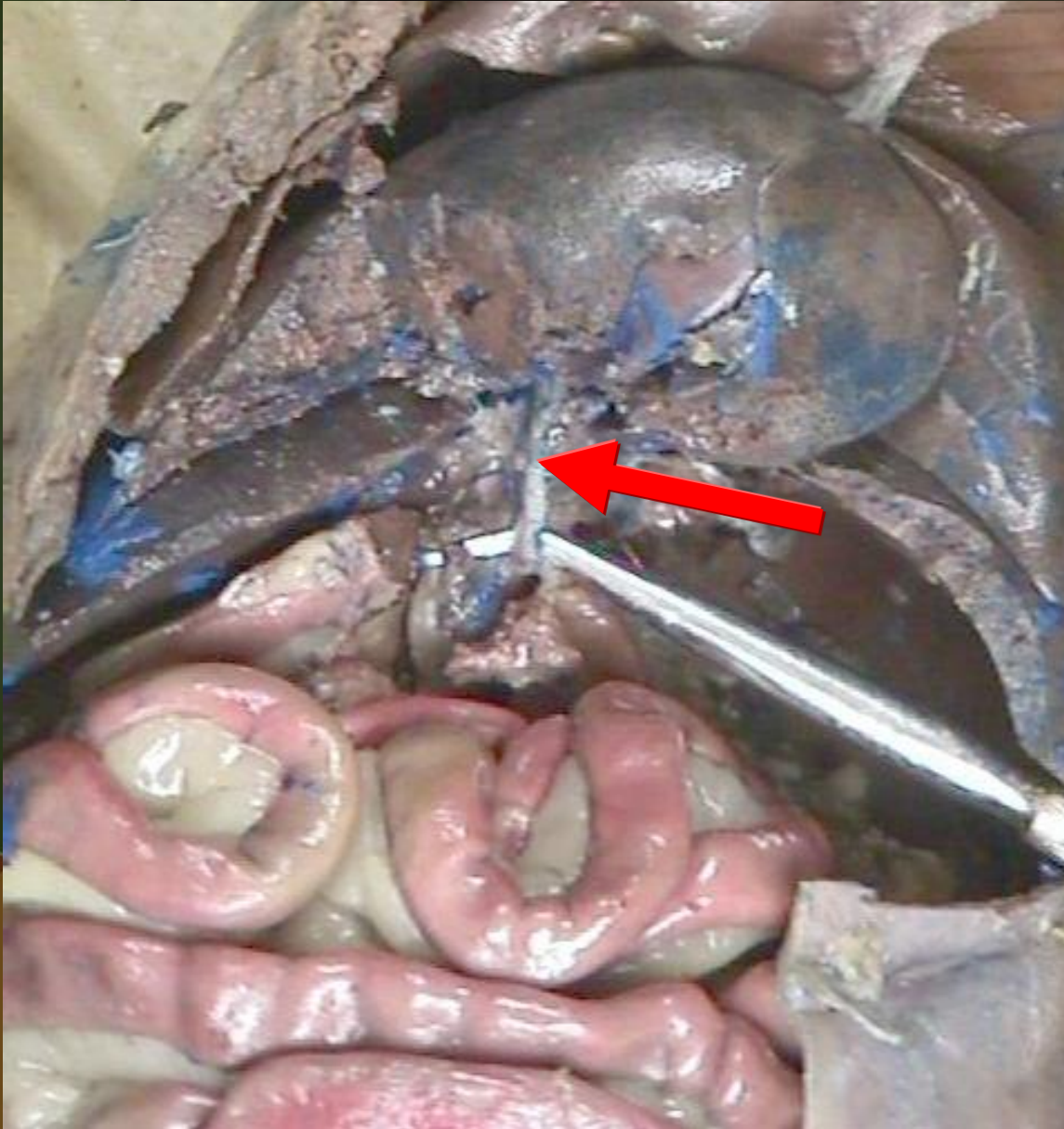
Azygous vein



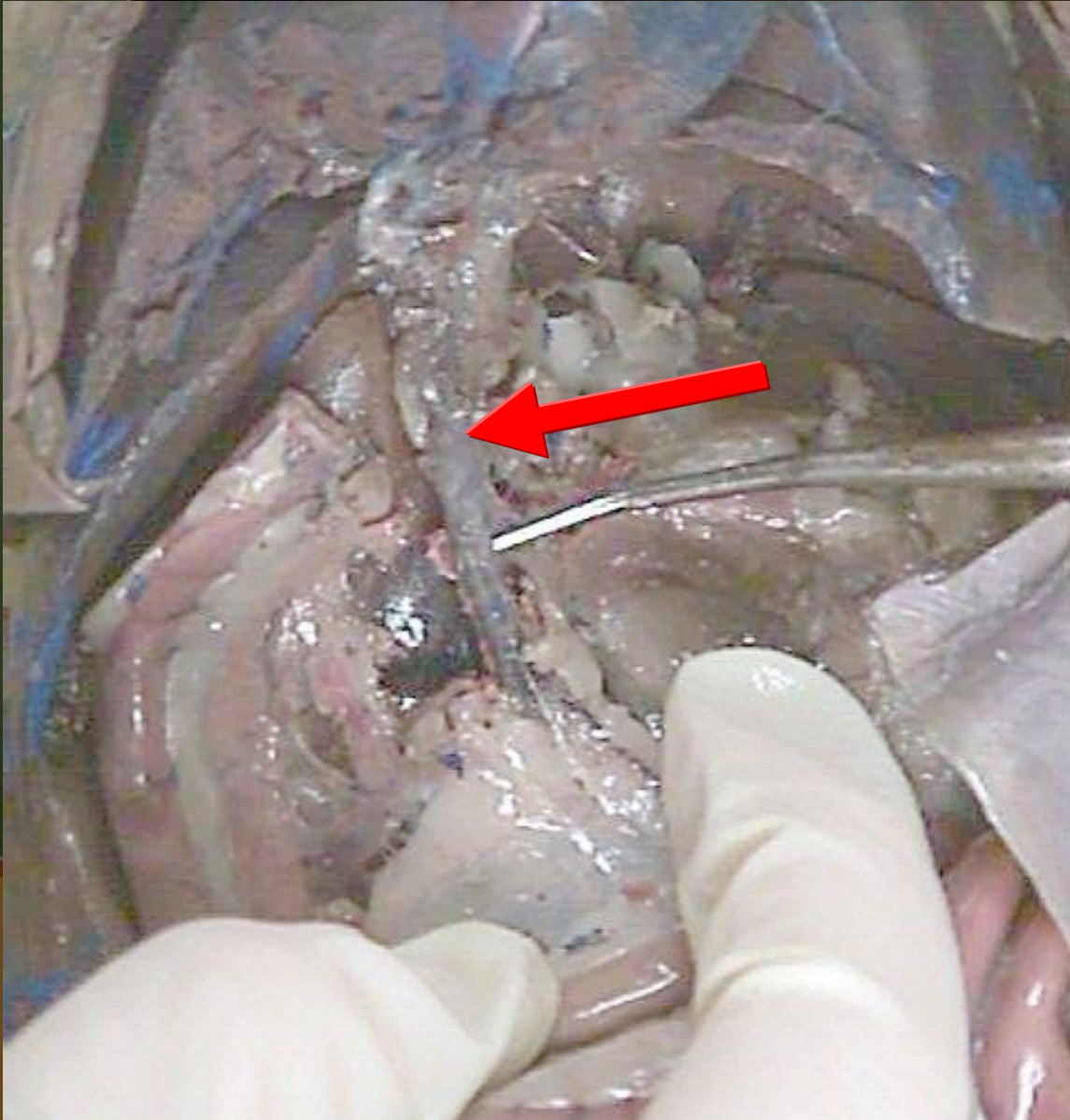
Thoracic aorta



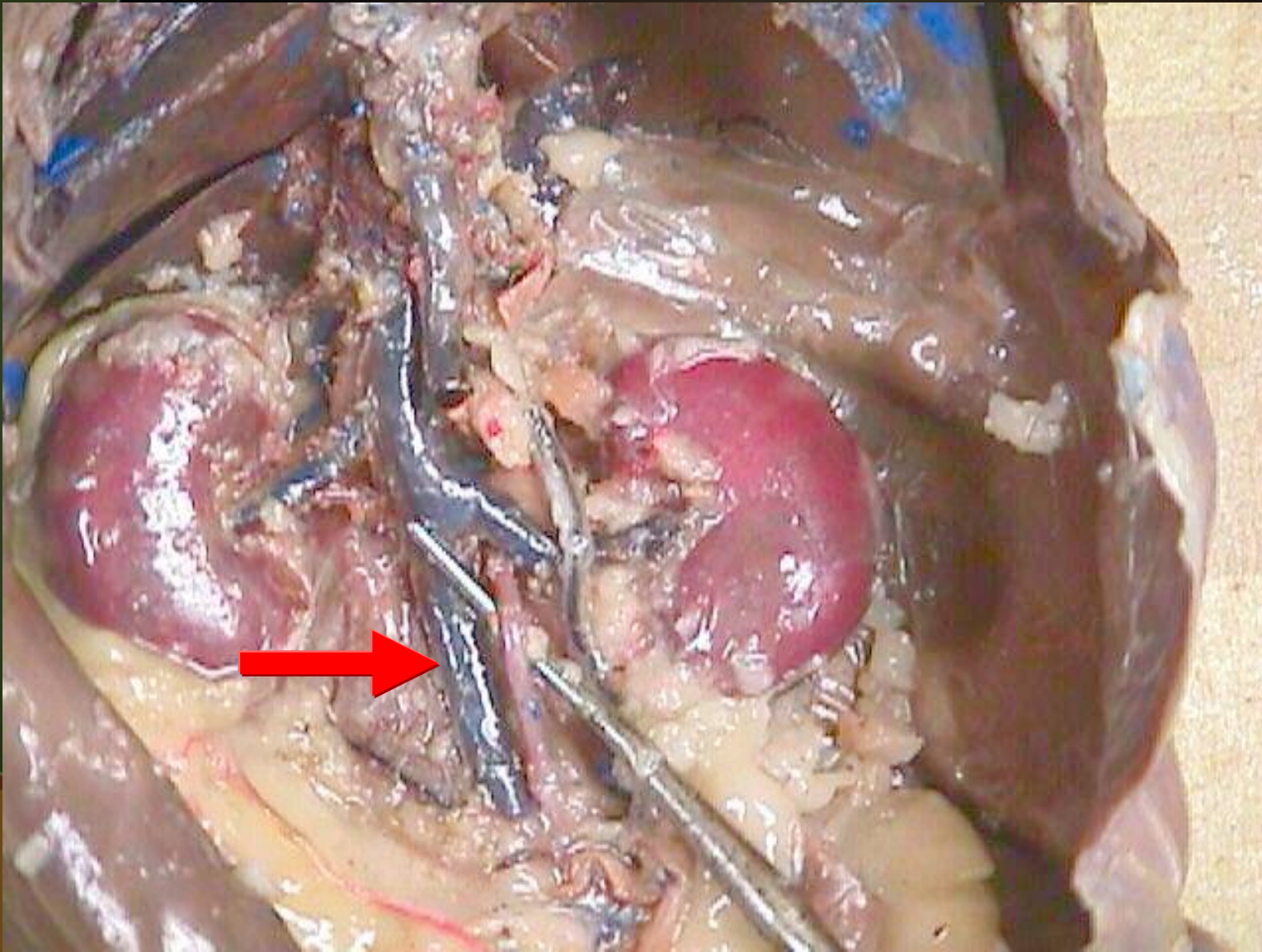
Hepatic portal vein



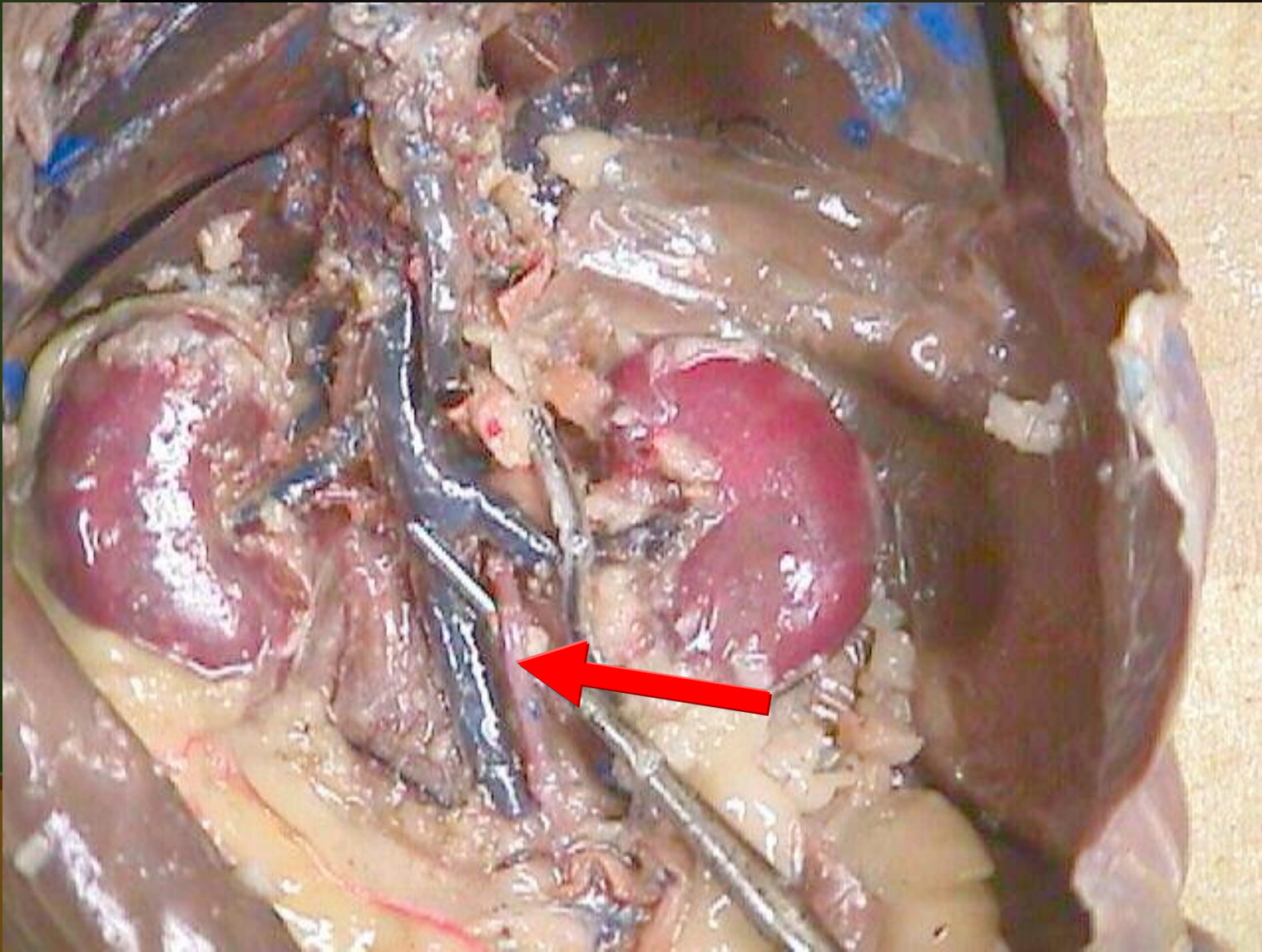
Hepatic portal vein



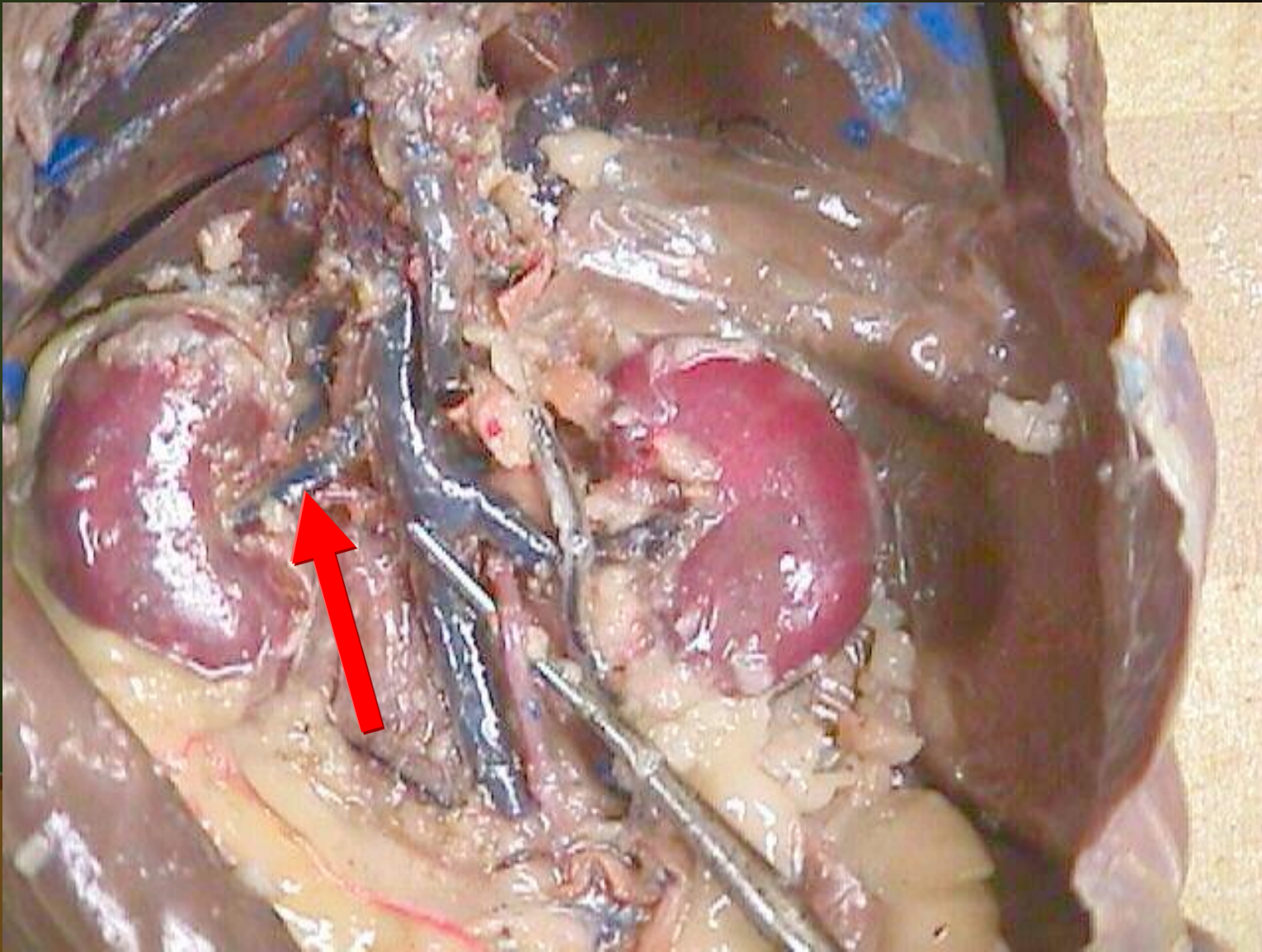
Postcava



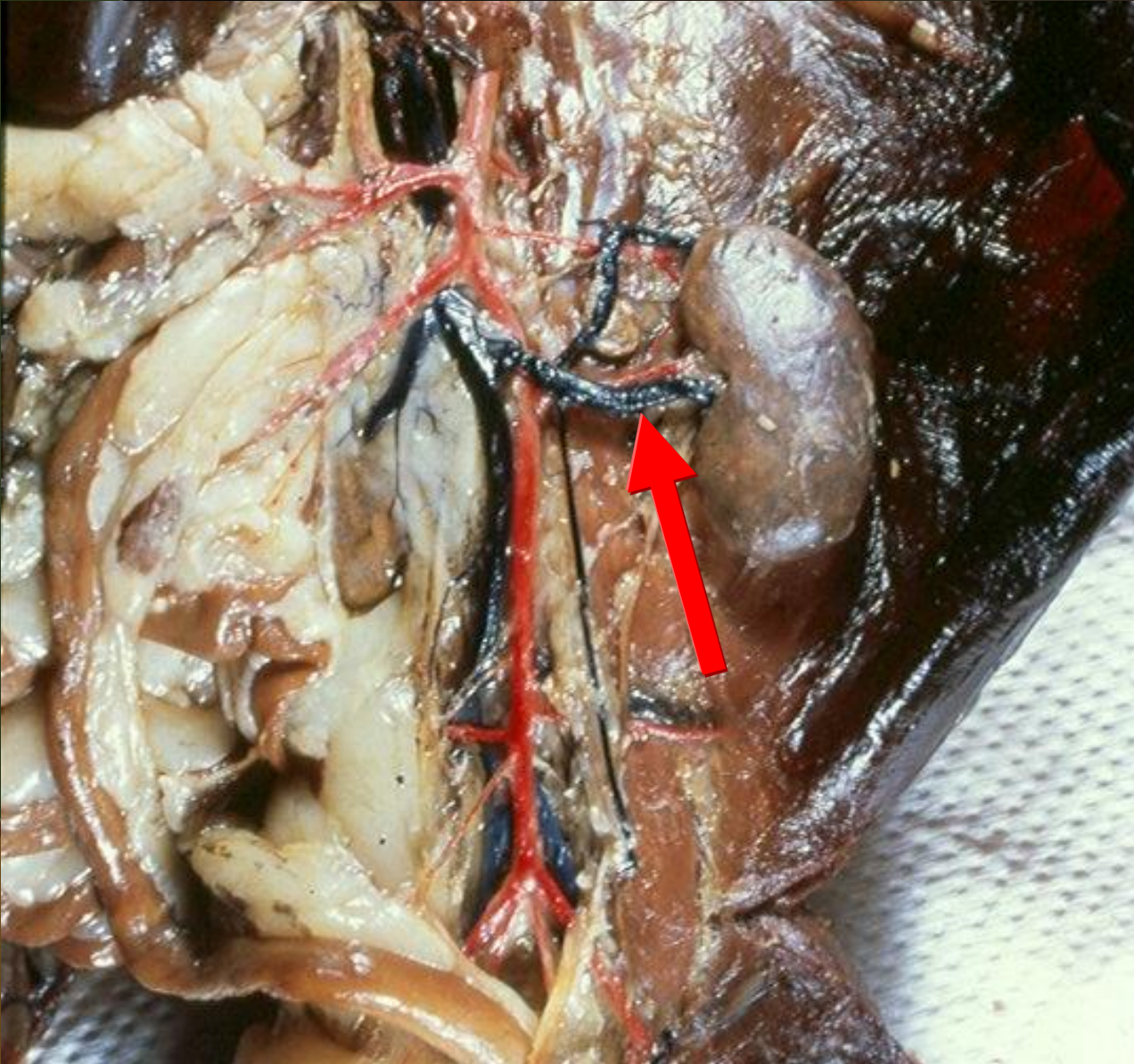
Abdominal aorta



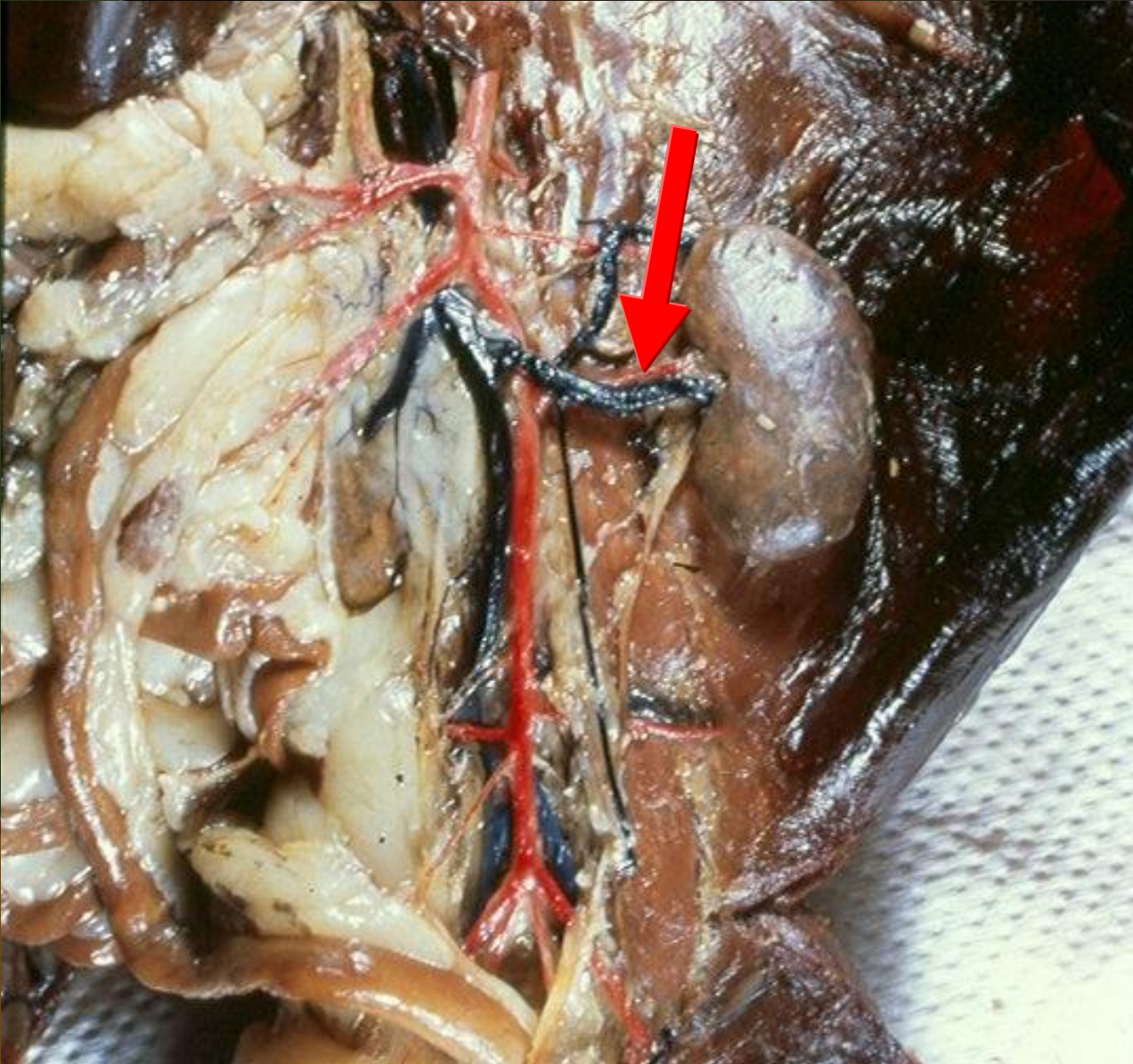
Renal vein



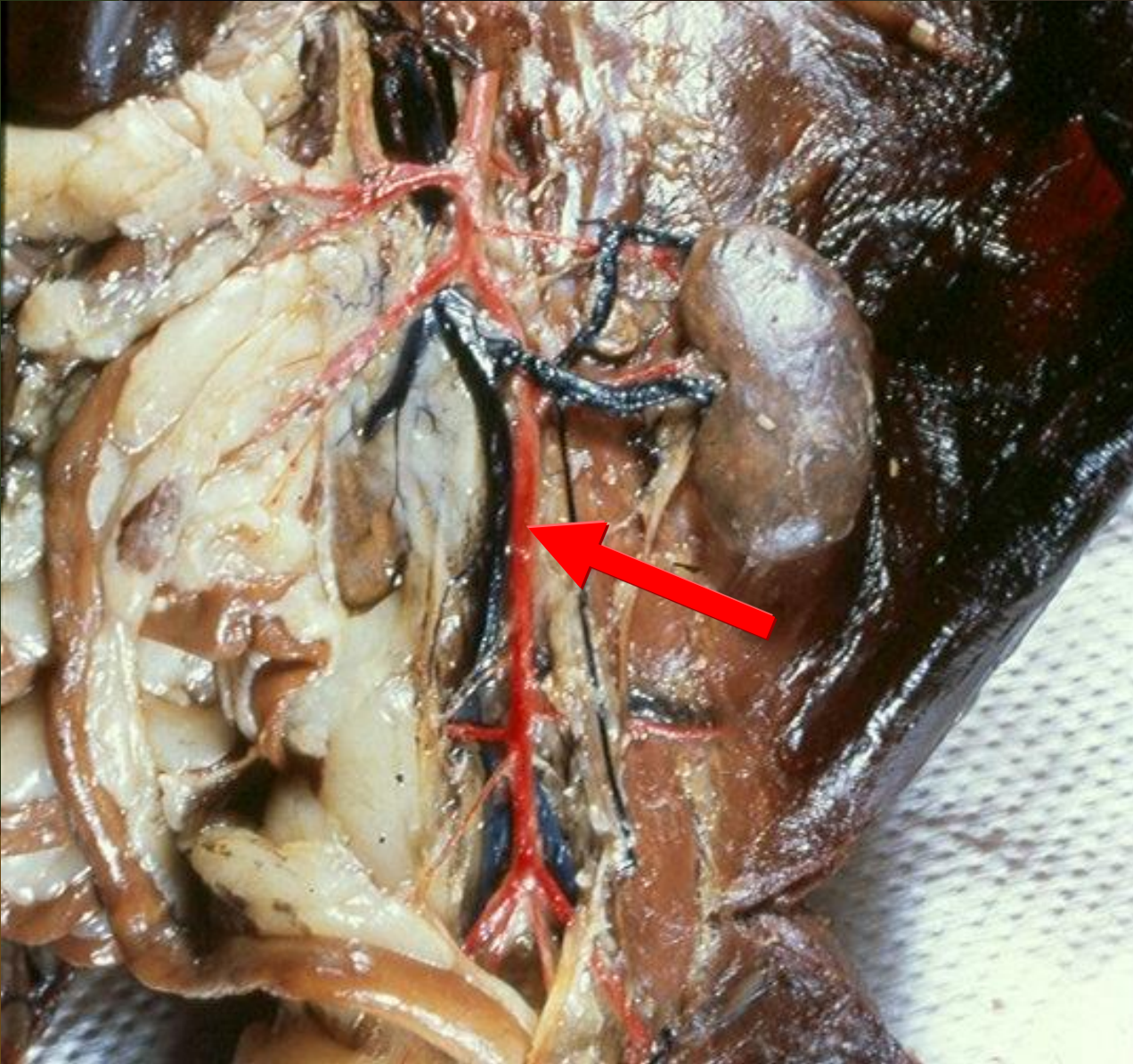
Renal vein



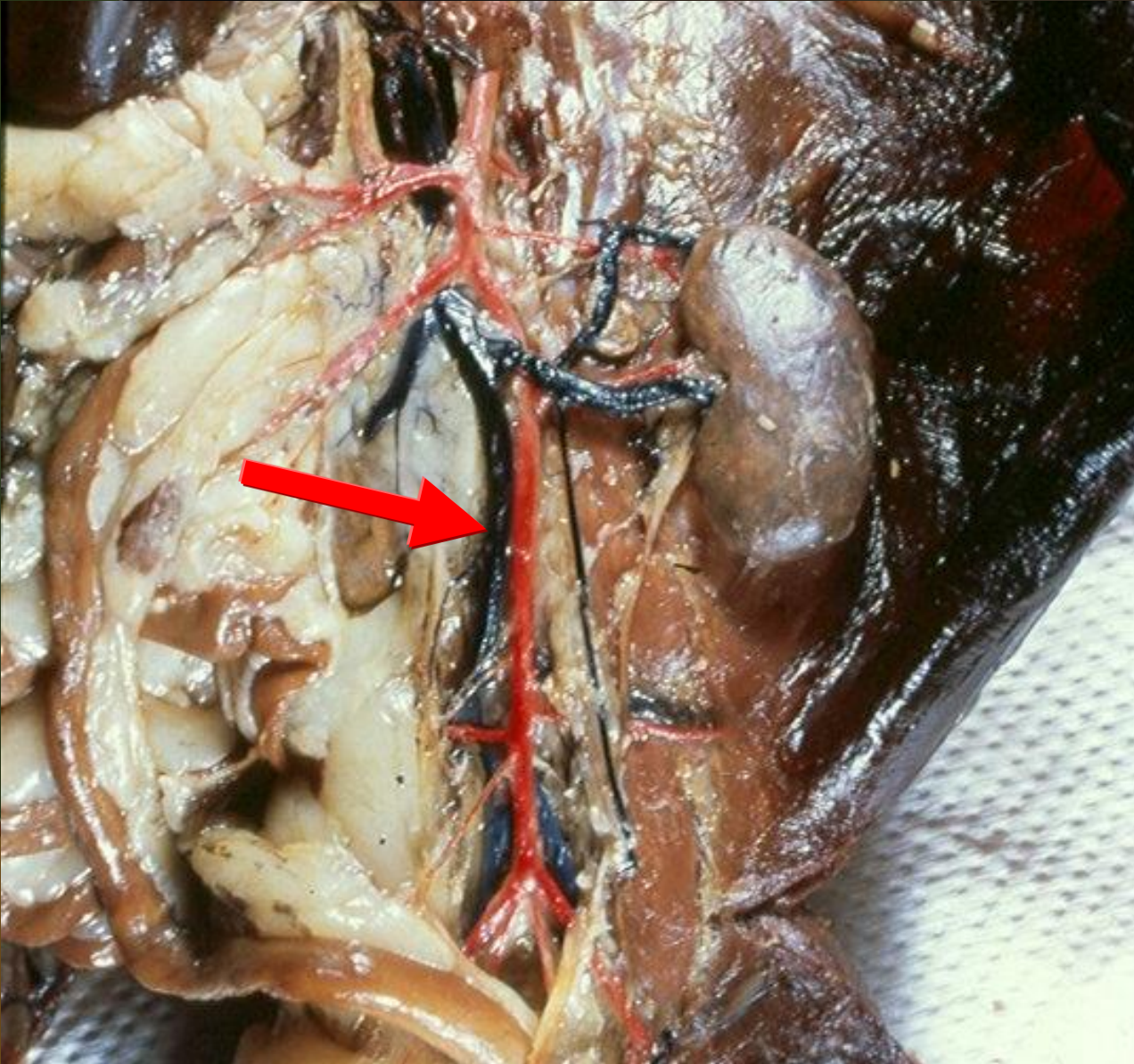
Renal artery



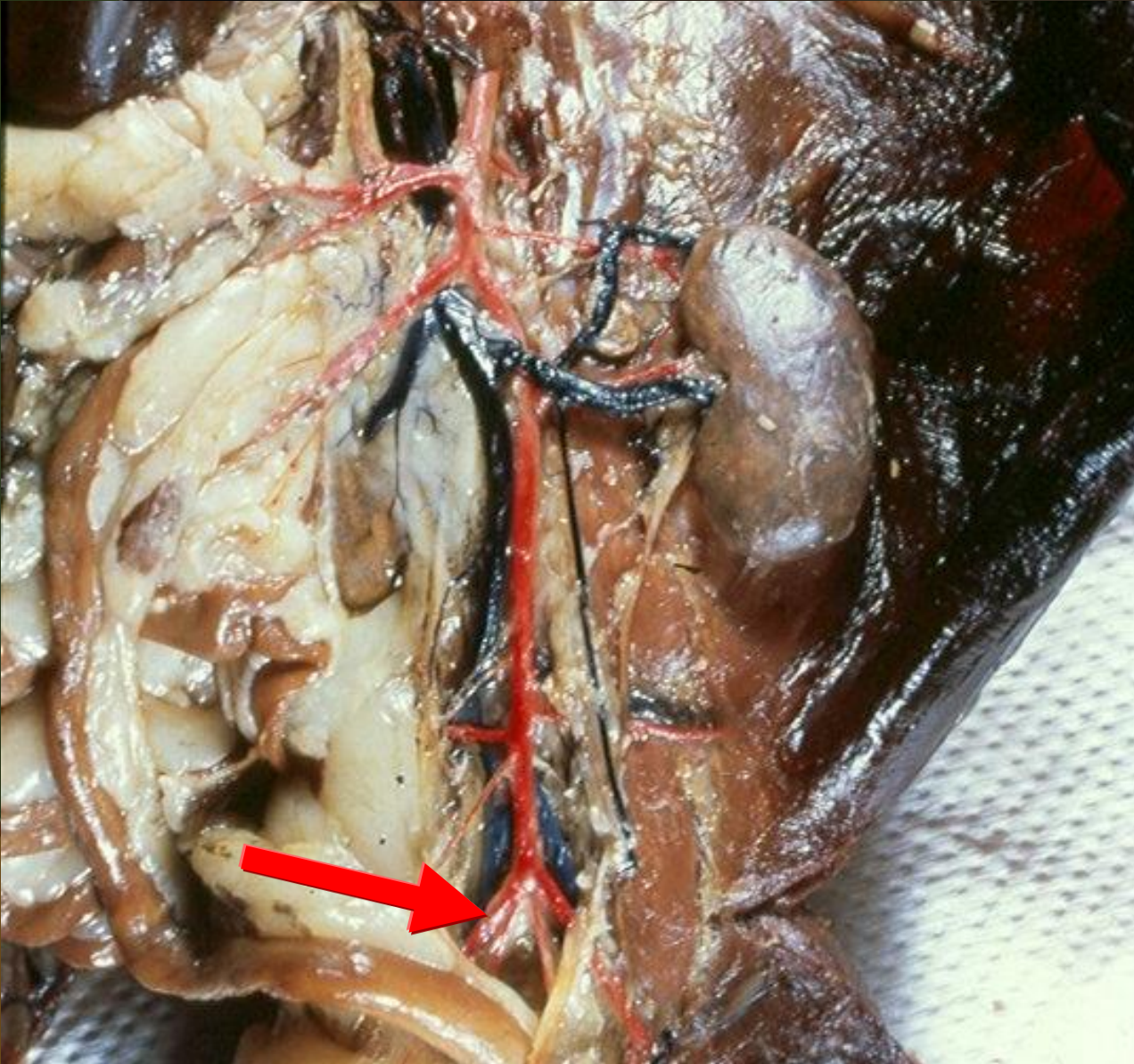
Abdominal aorta



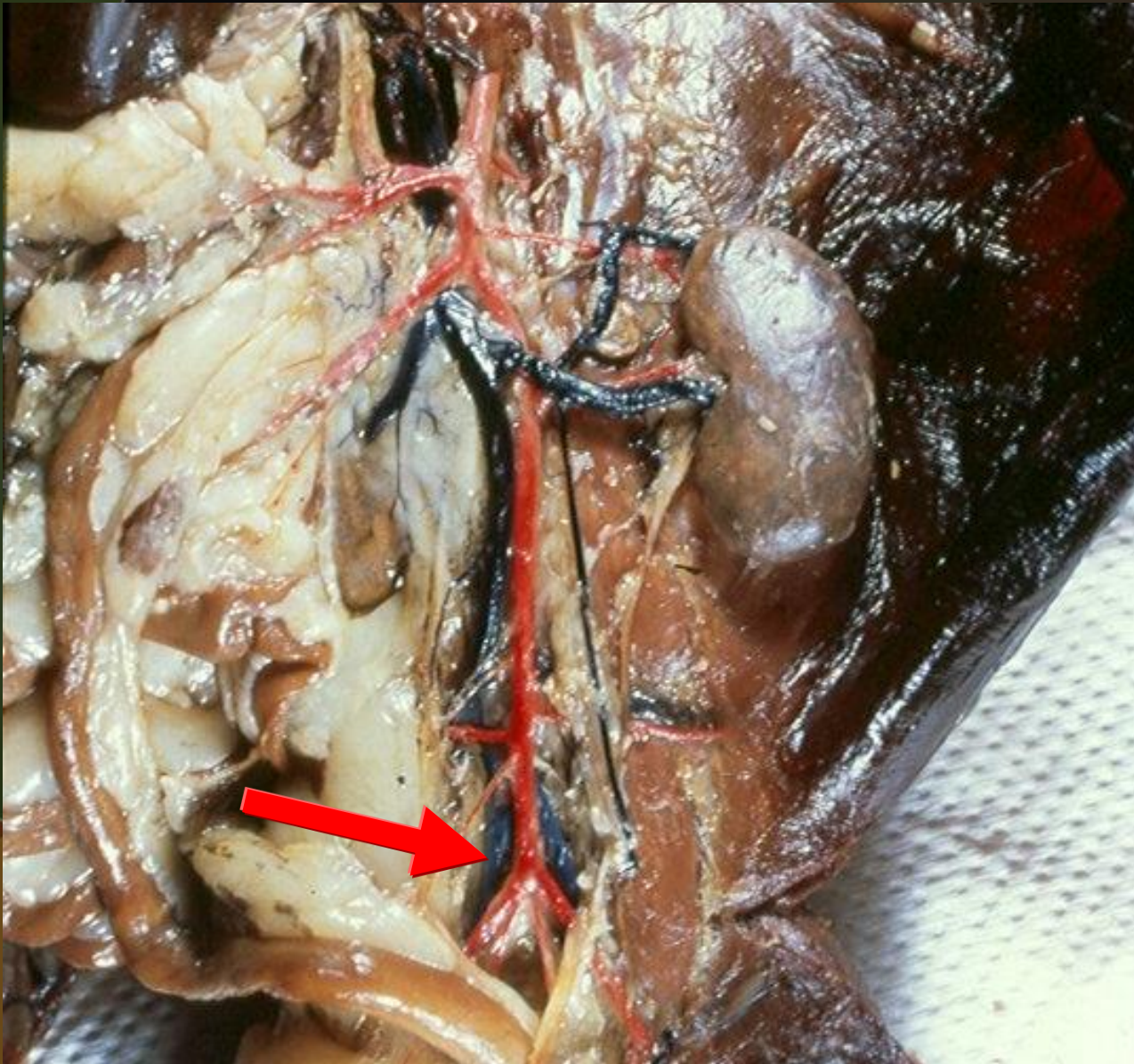
Postcava



Iliac artery



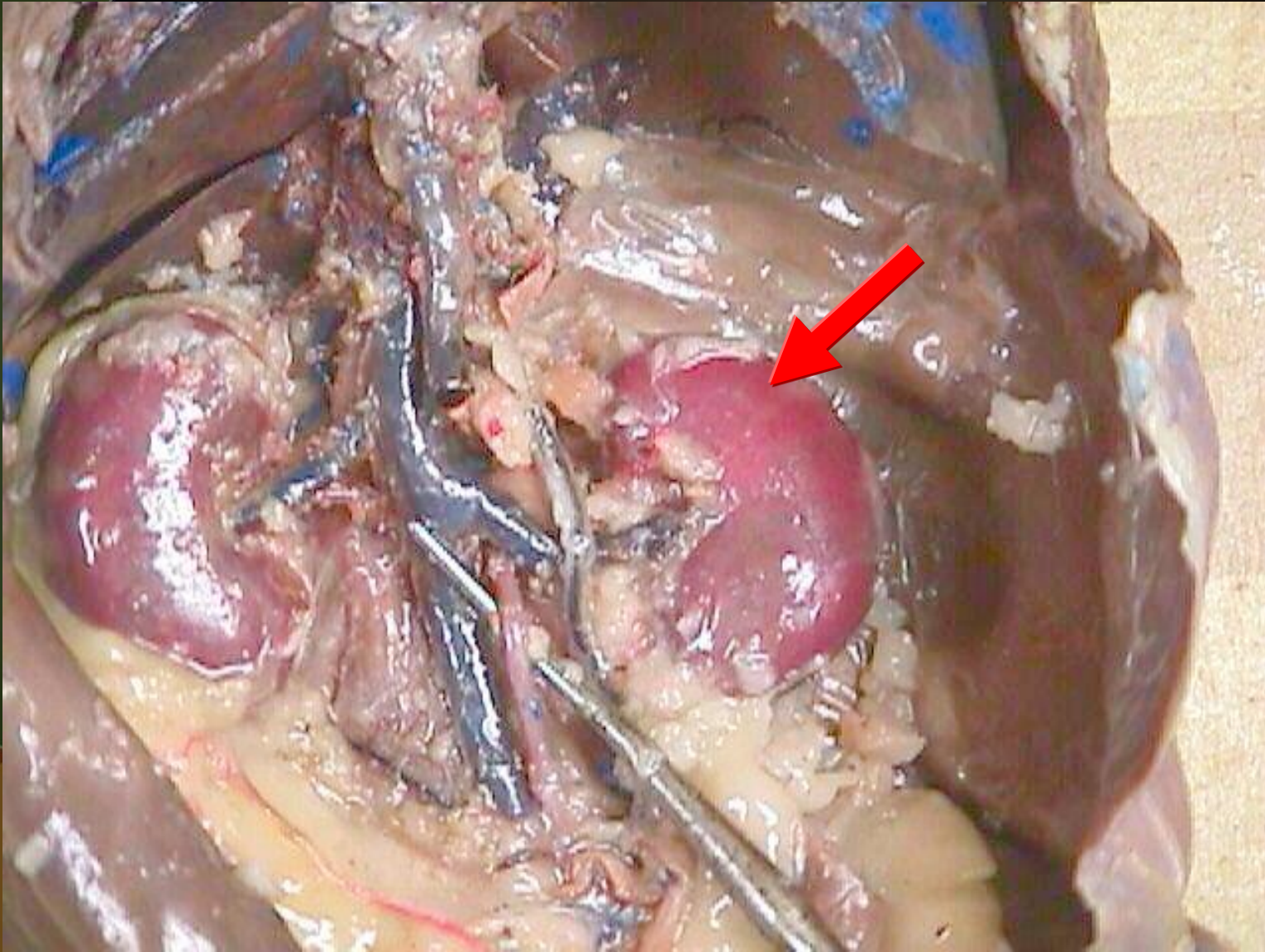
Iliac vein



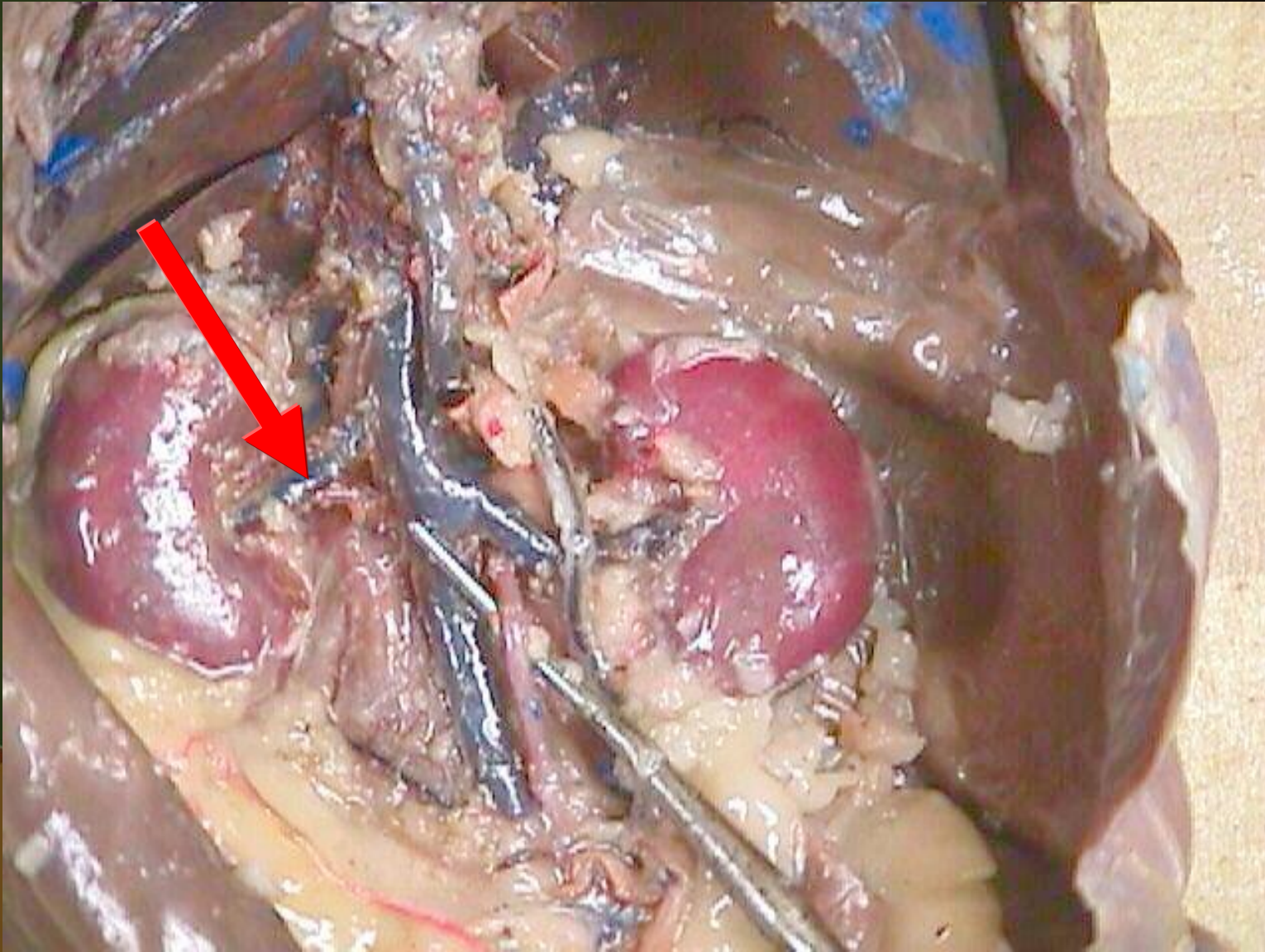
Urinary System



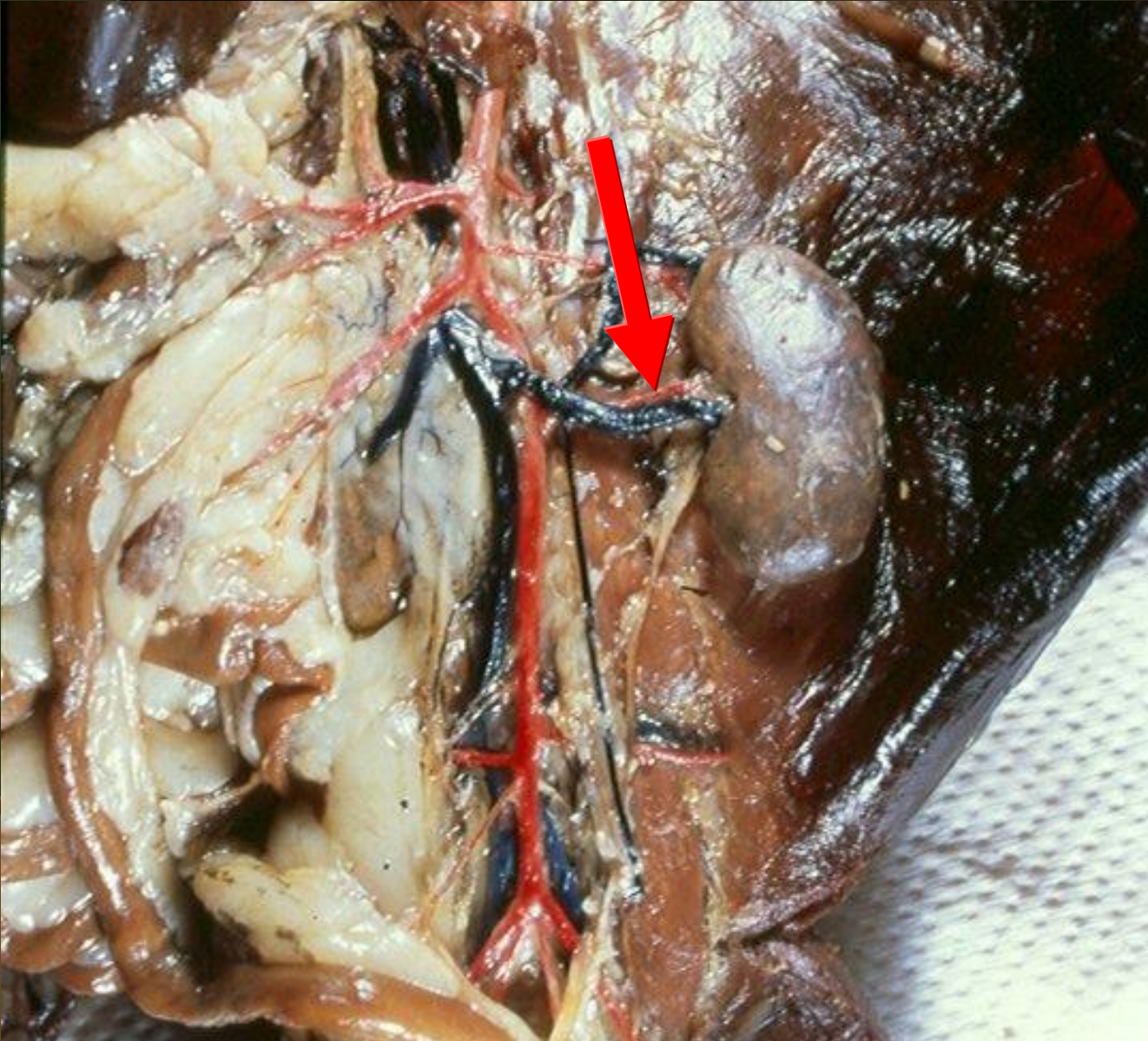
Kidney



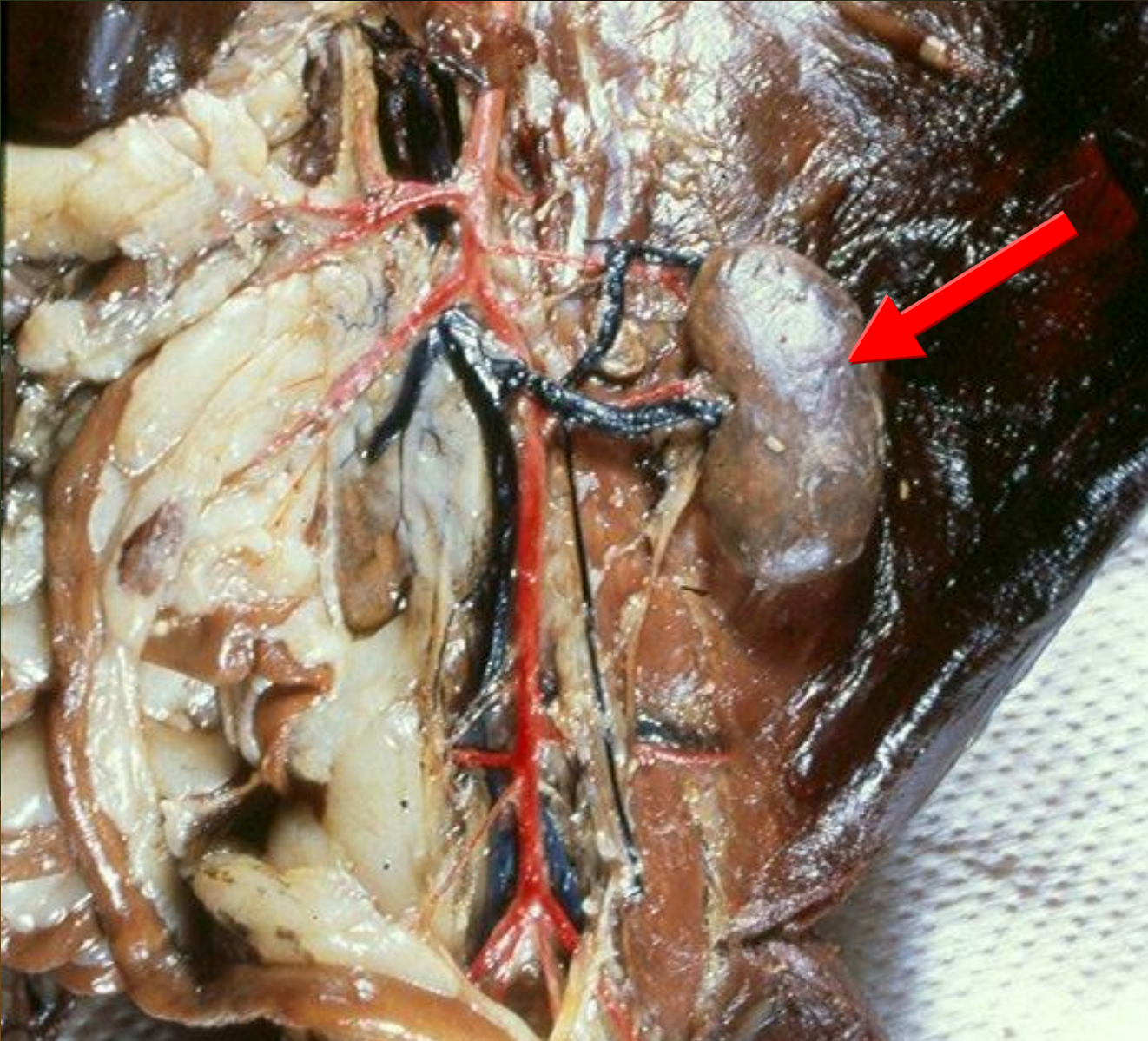
Renal vein



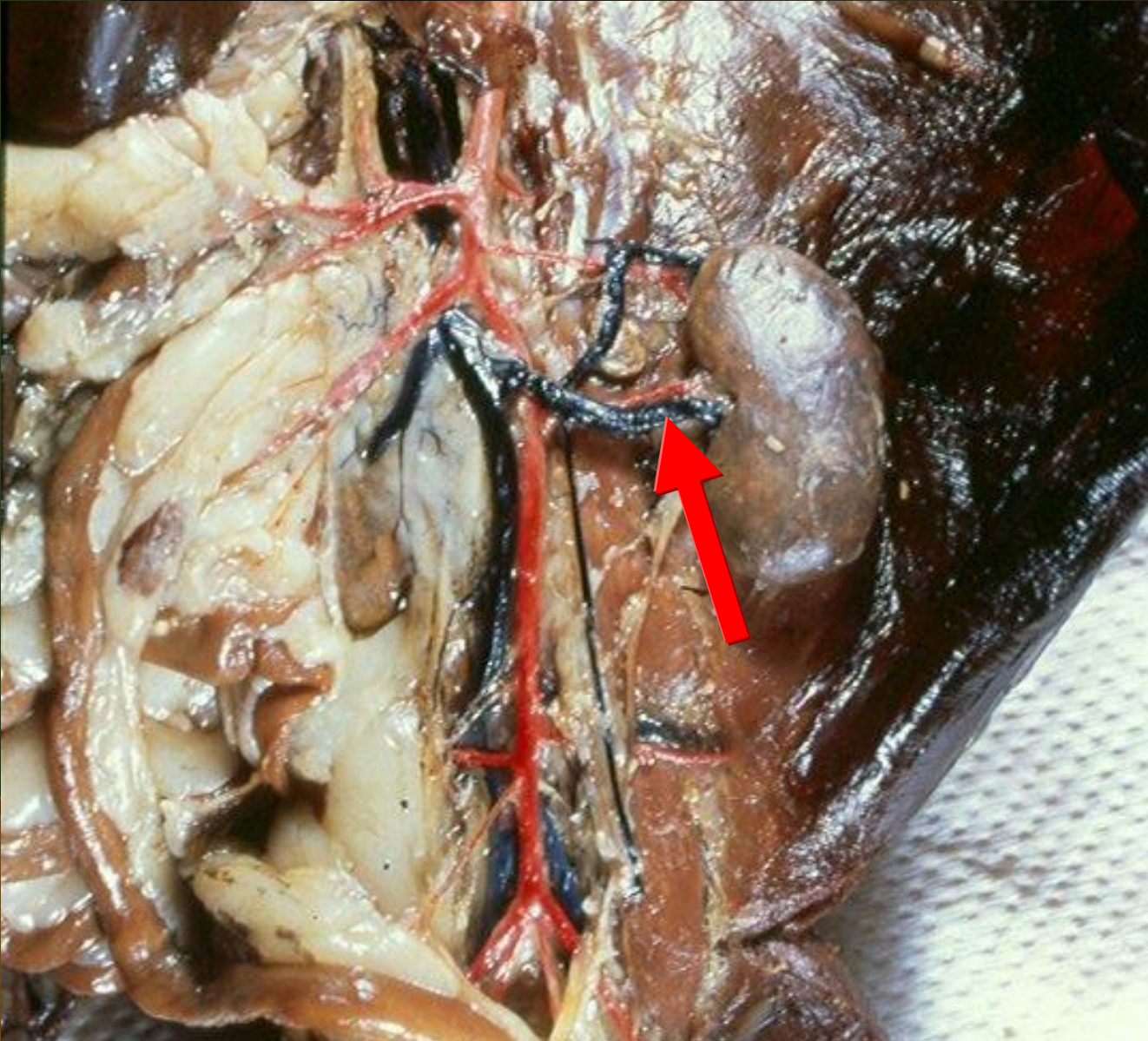
Renal artery



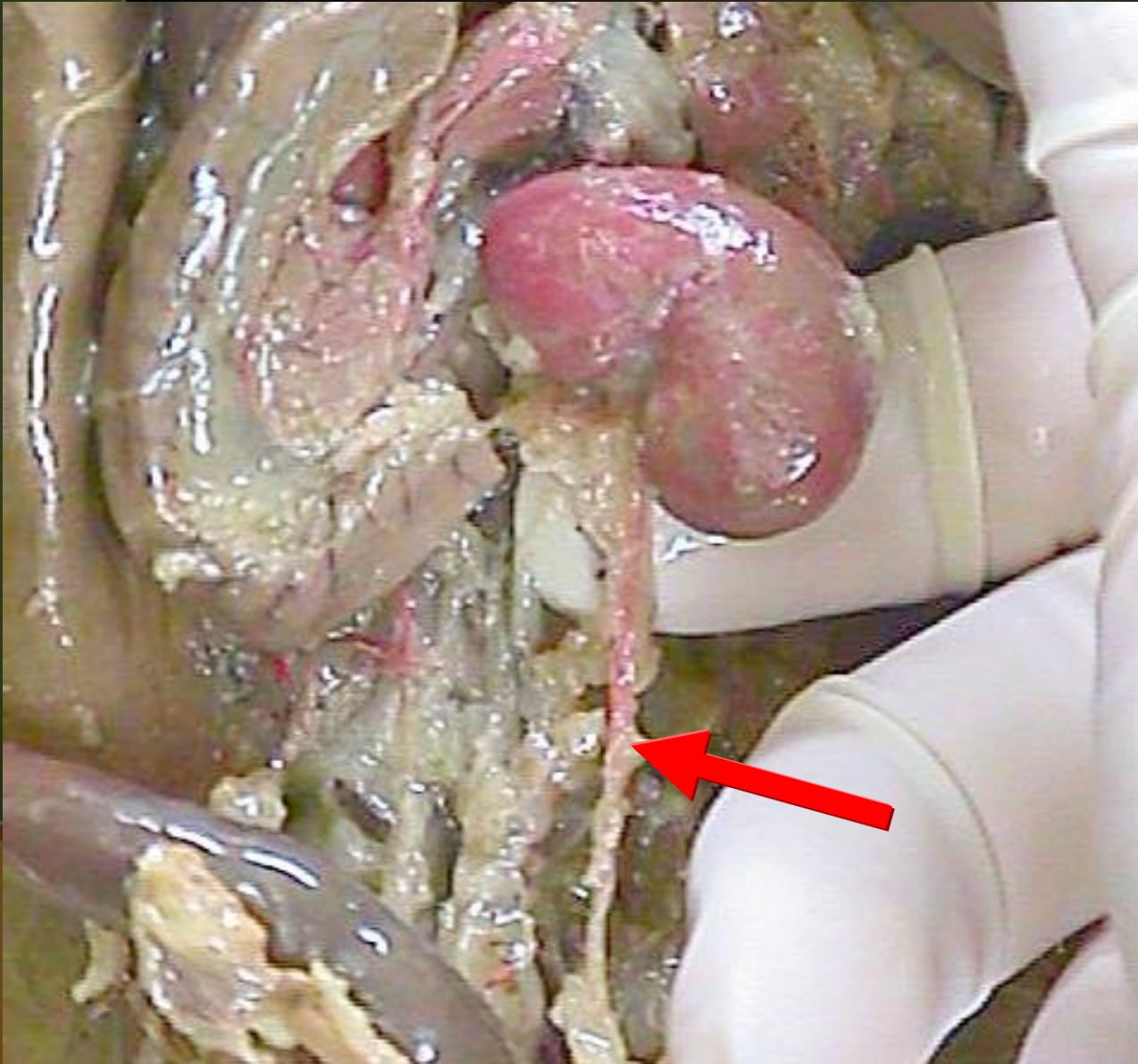
Kidney



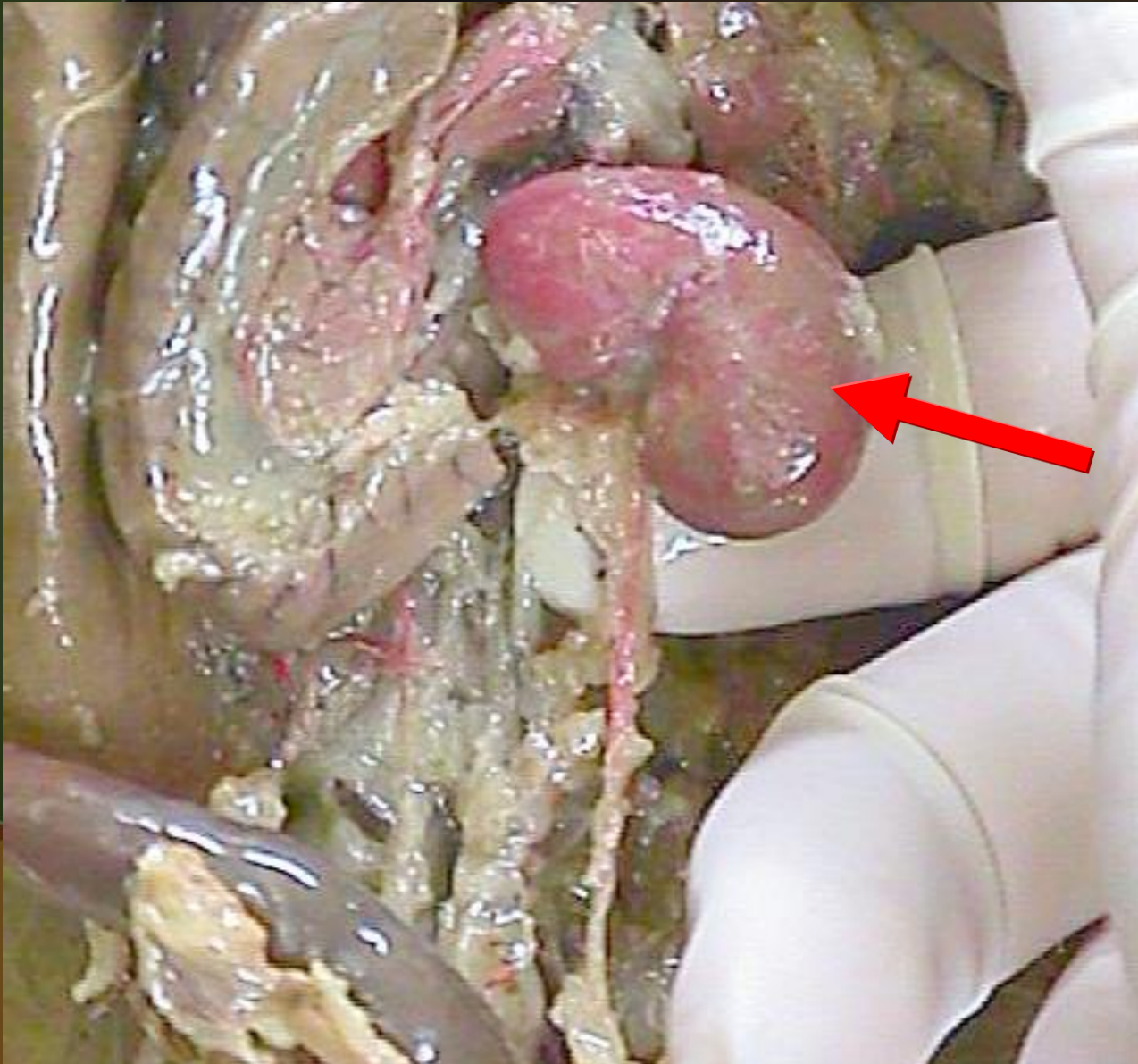
Renal vein



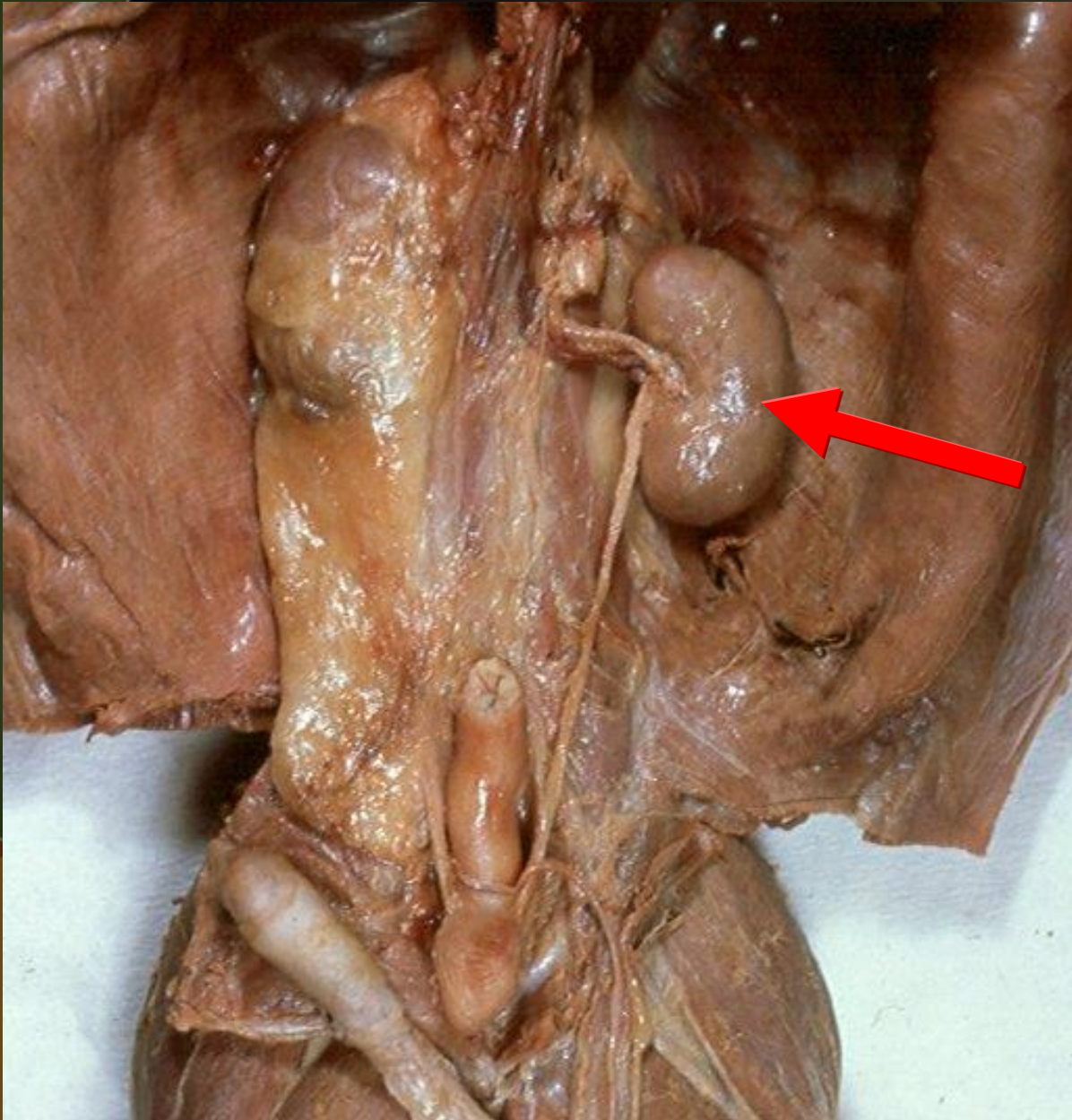
Ureter



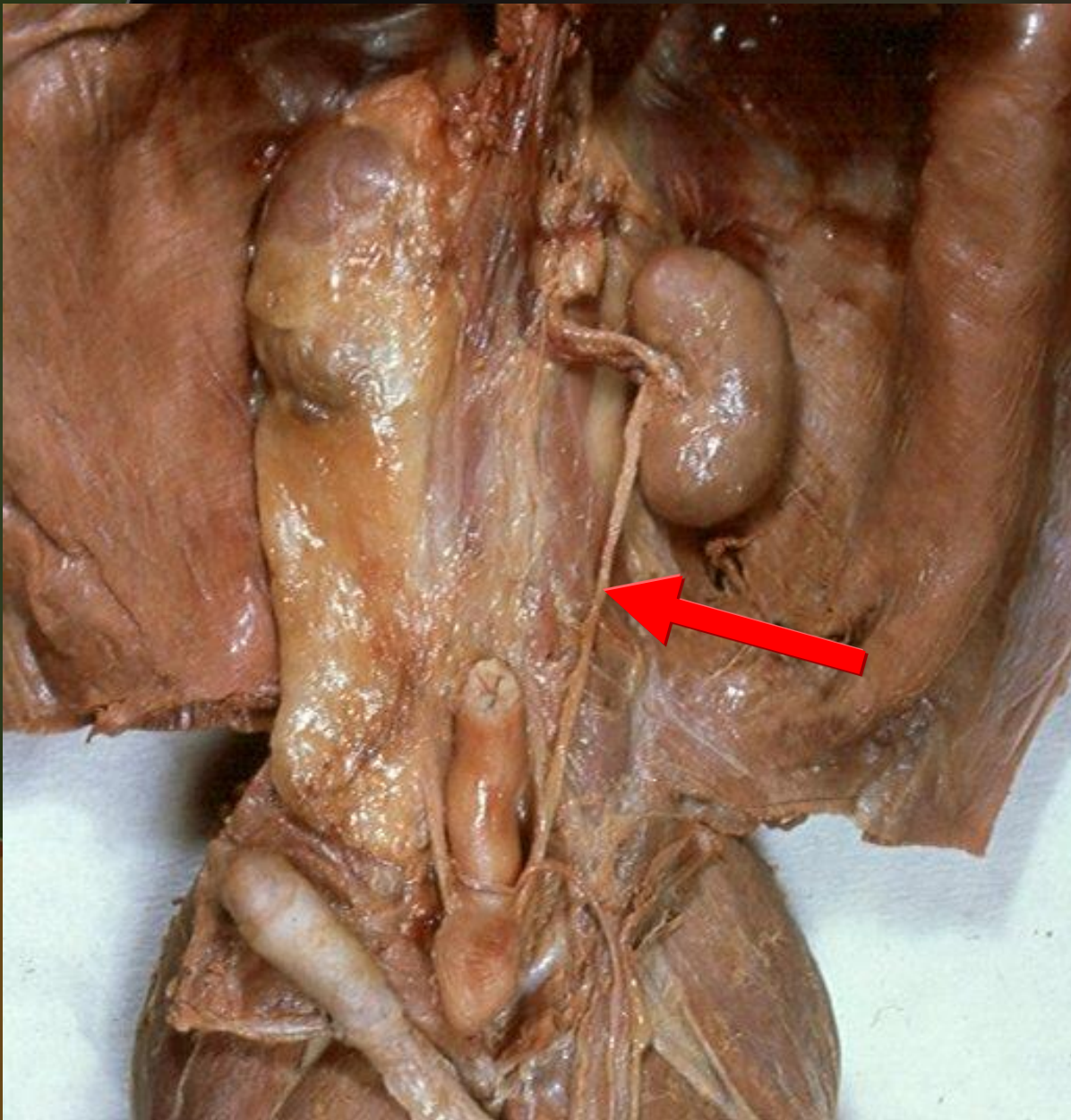
Kidney



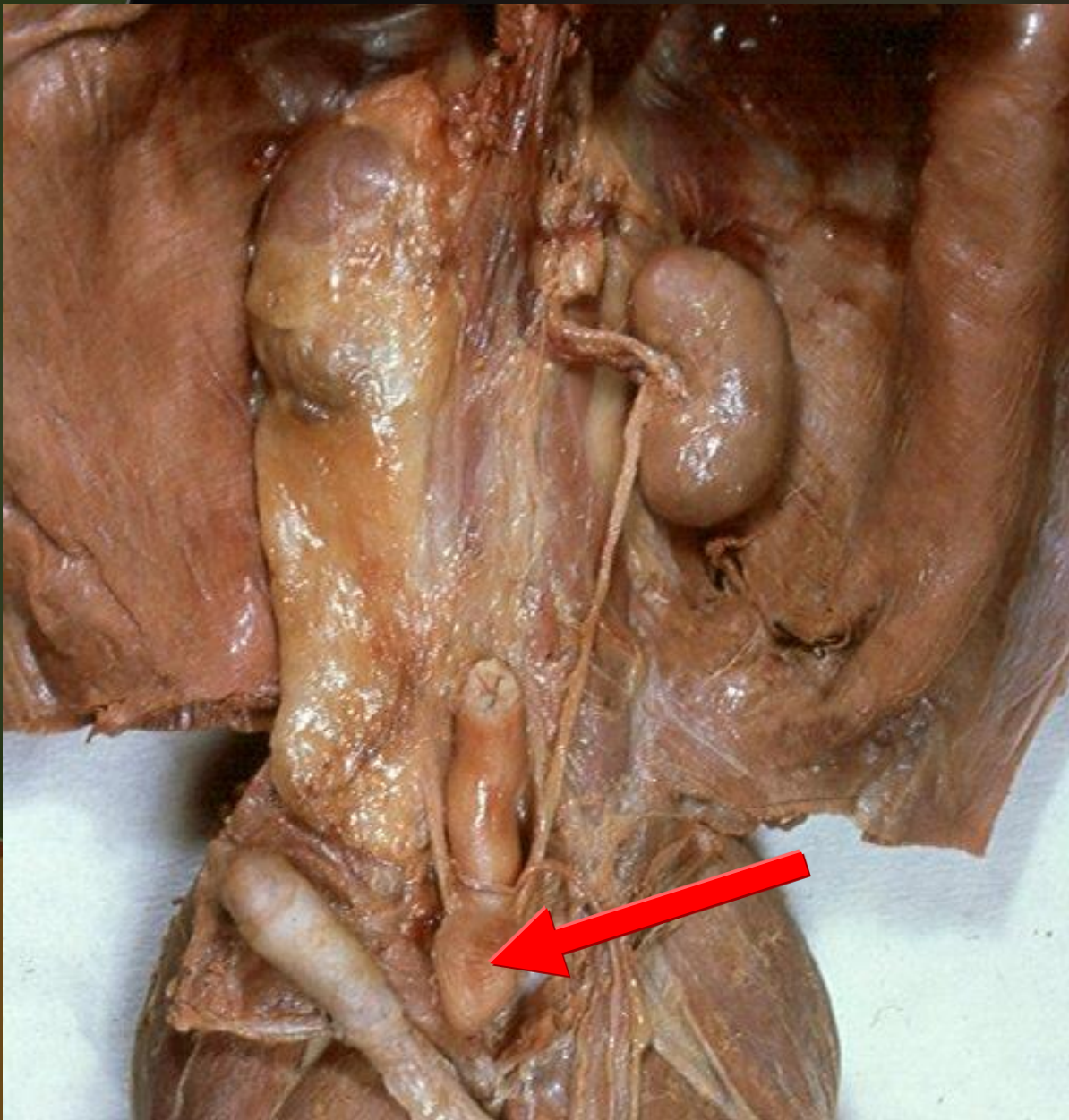
Kidney



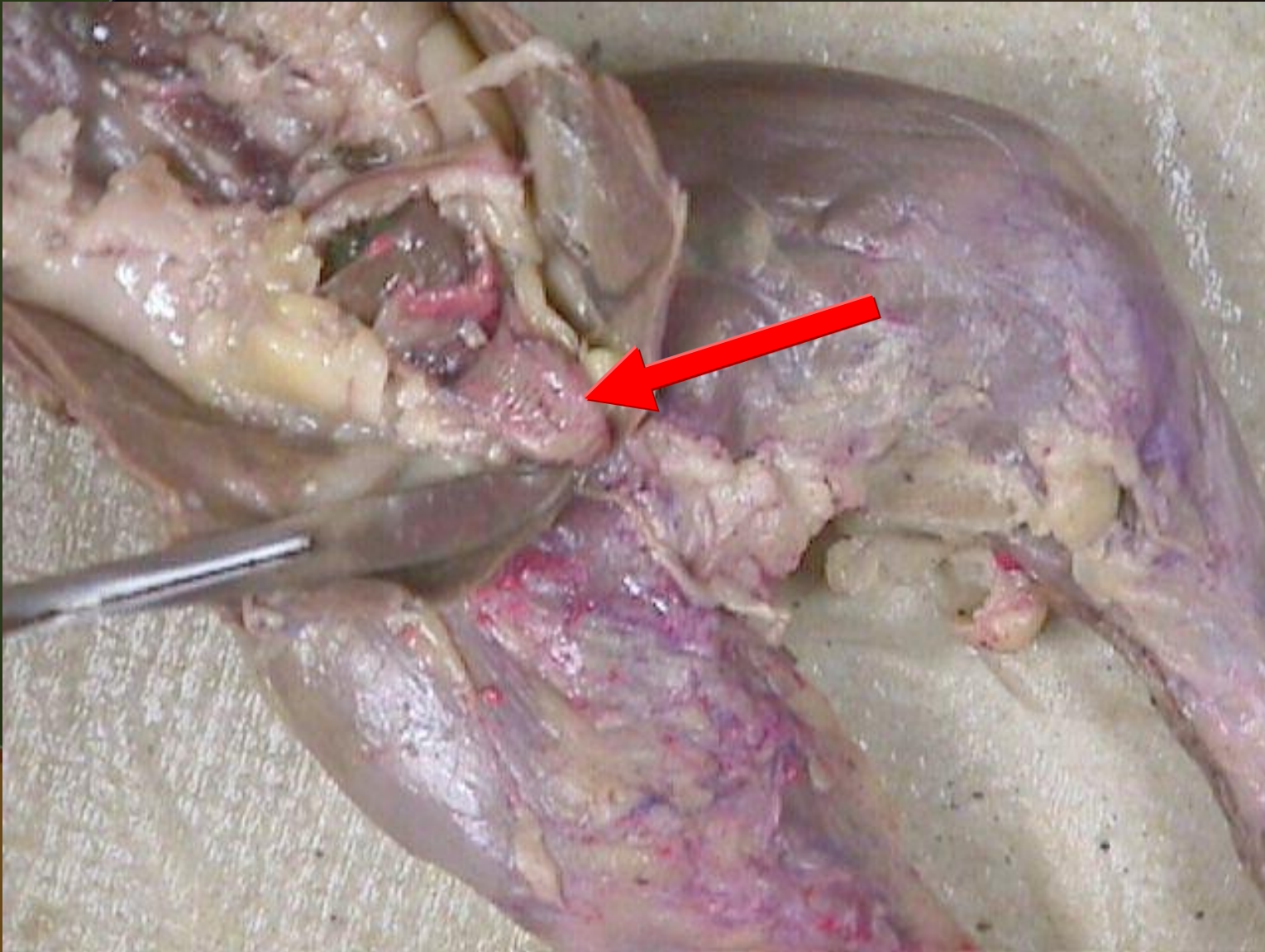
Ureter



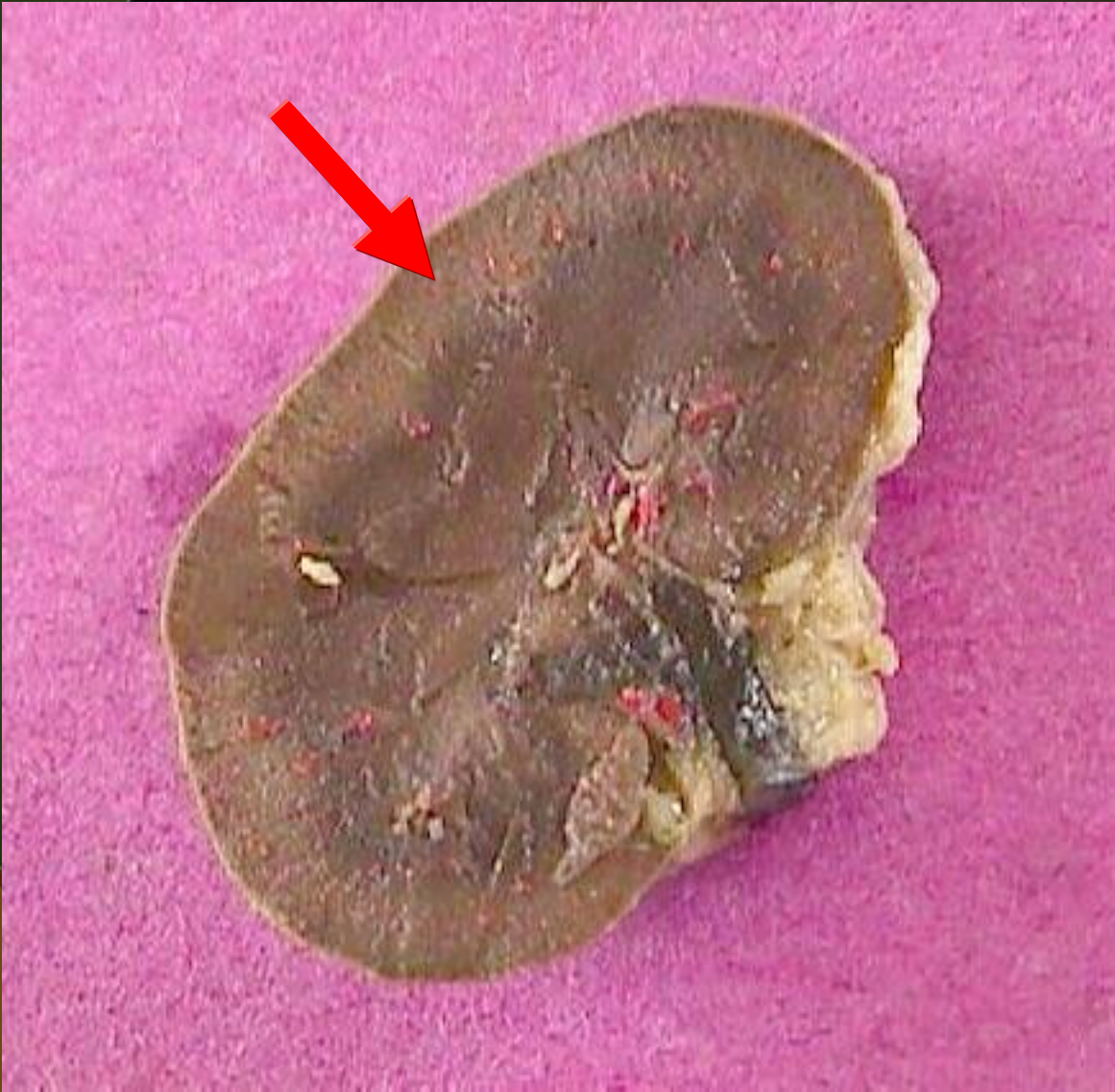Urinary bladder



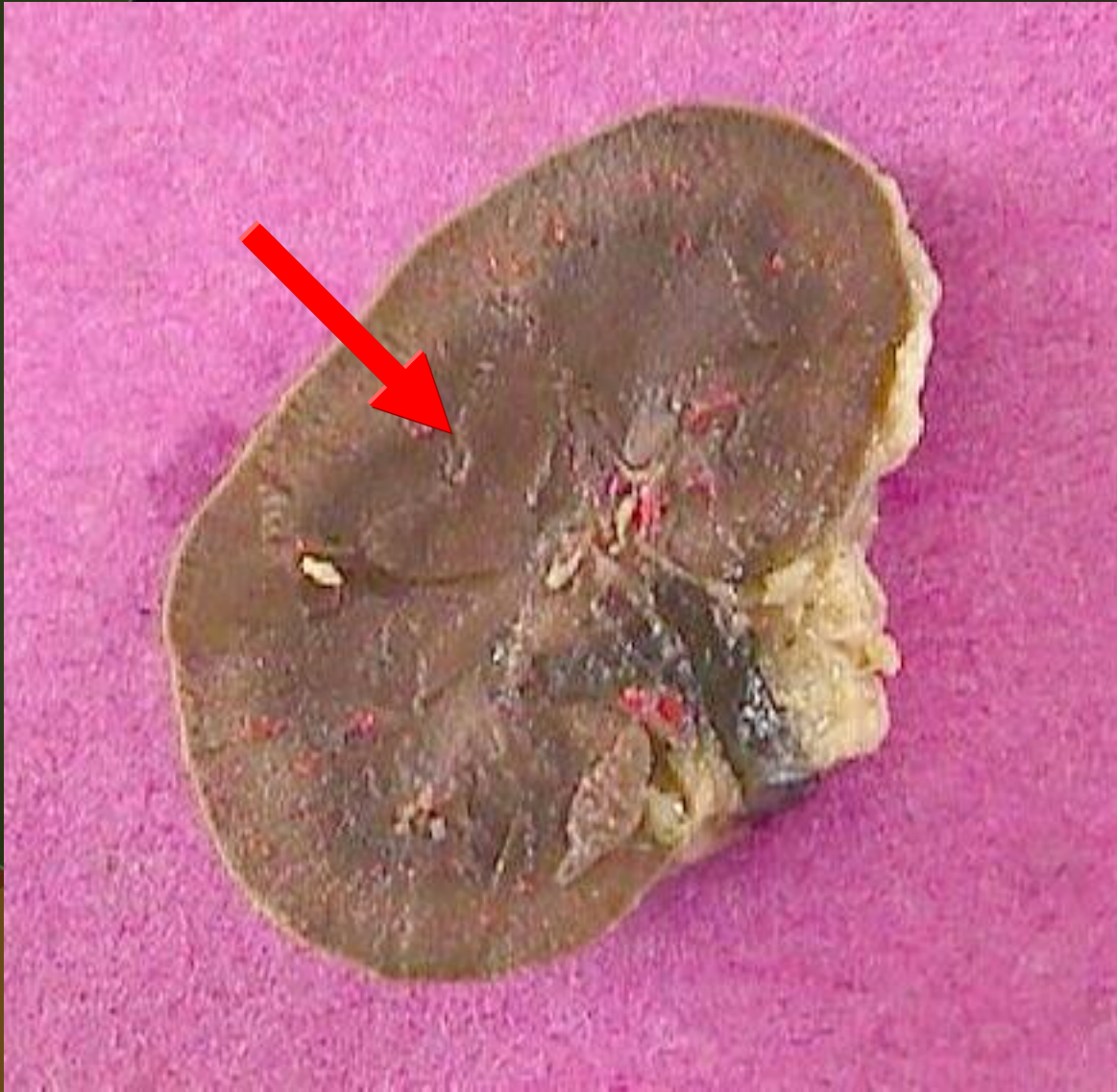Urinary bladder



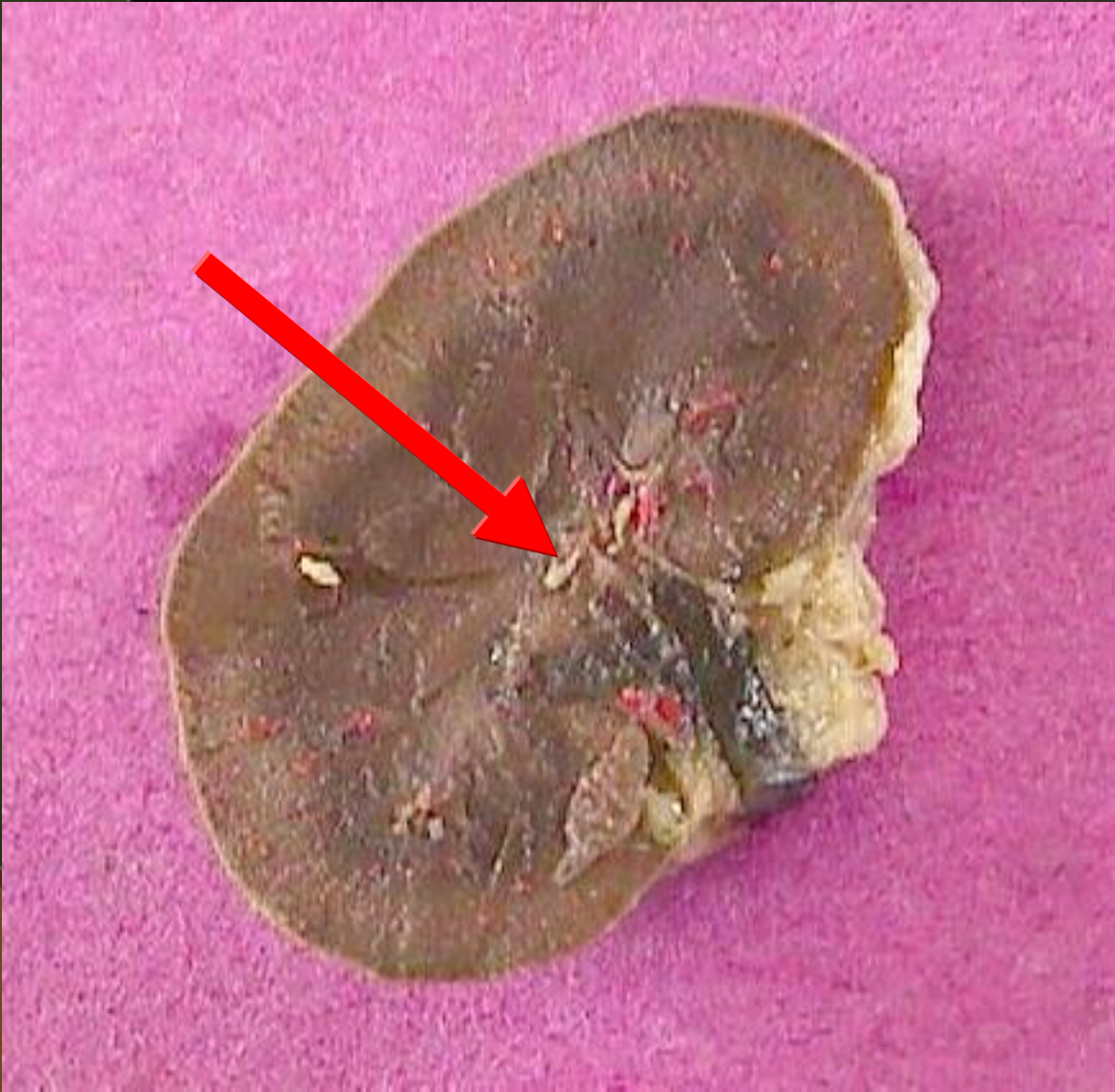Renal cortex



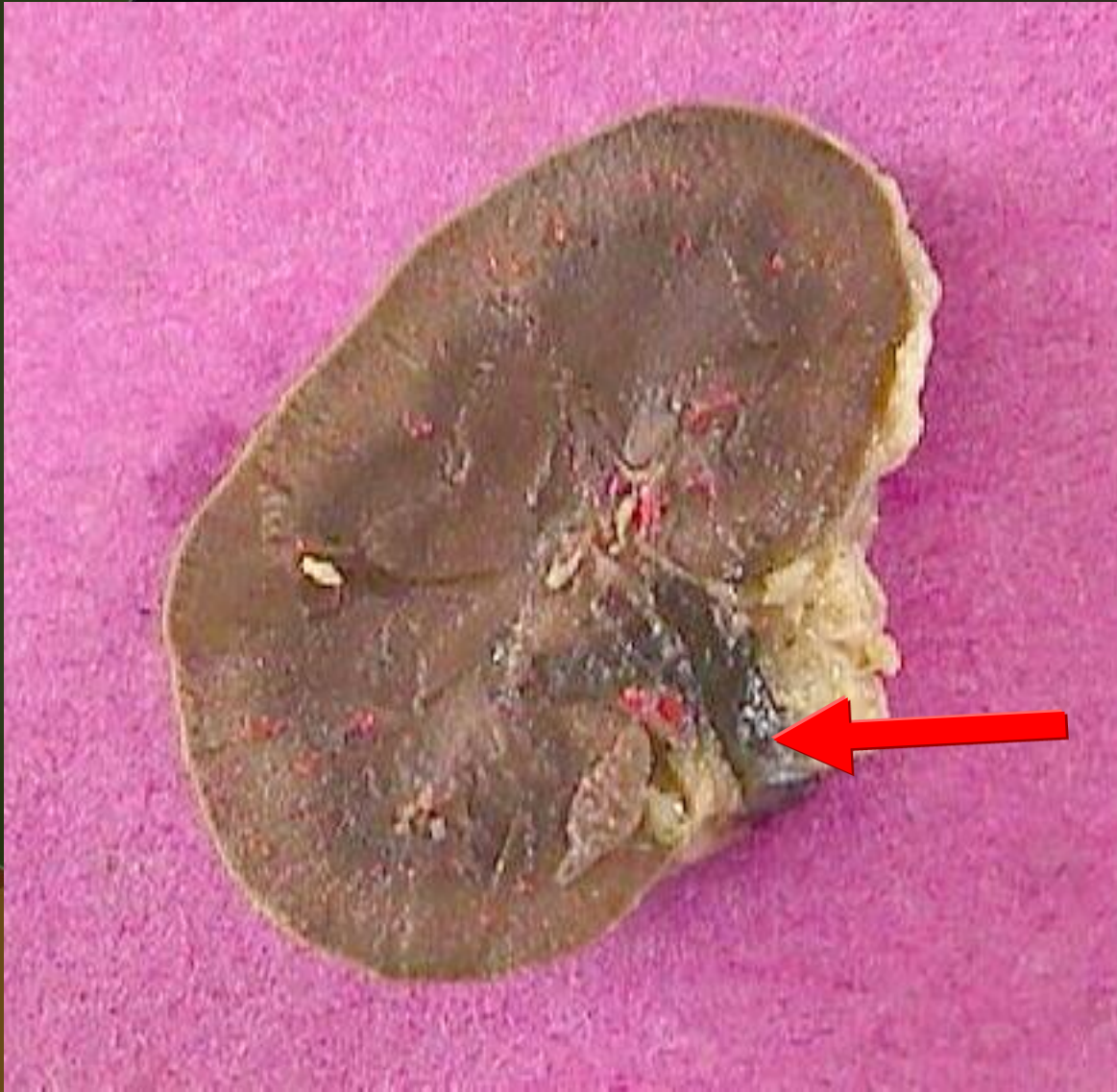Renal medulla



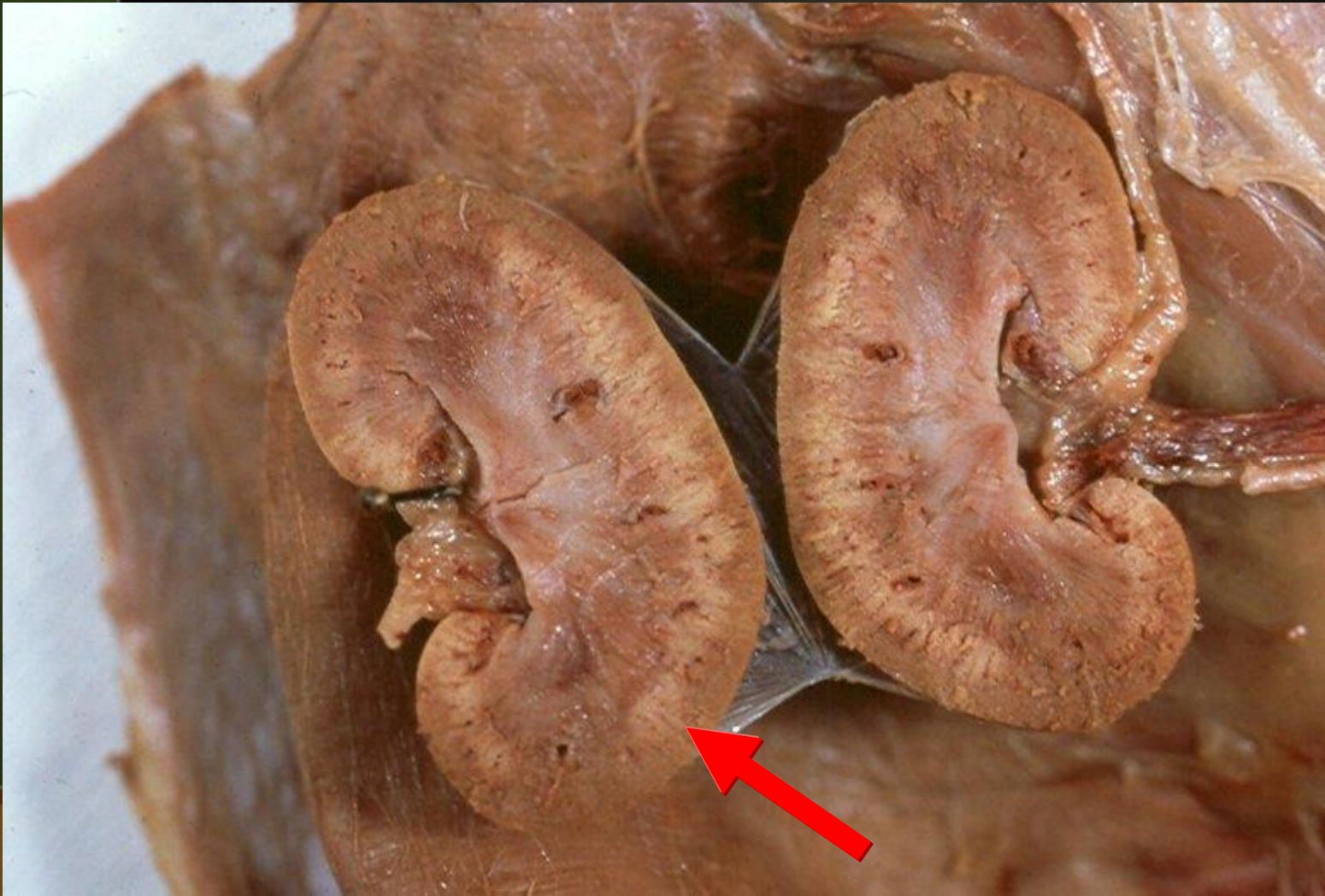
Renal pelvis



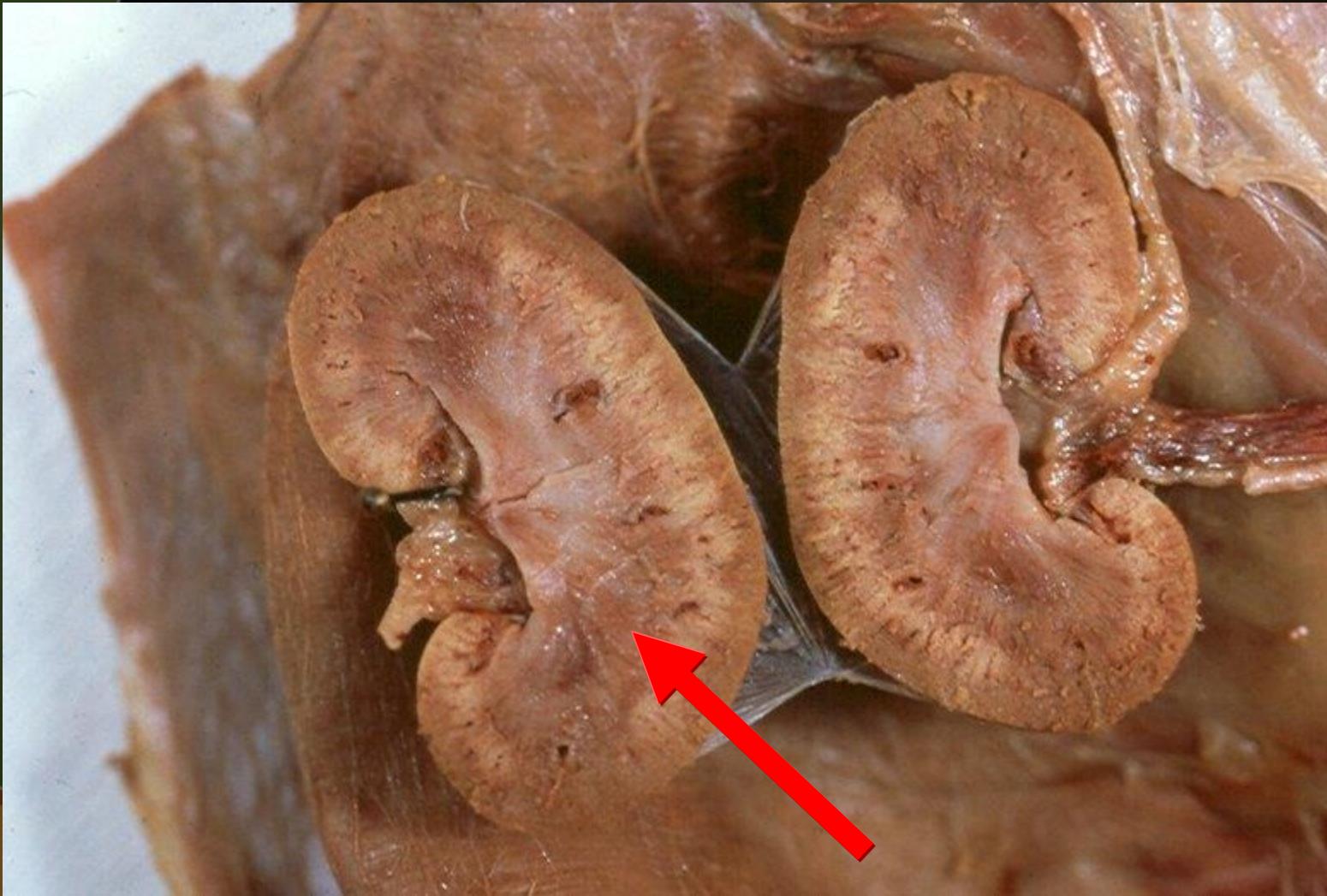
Renal vein



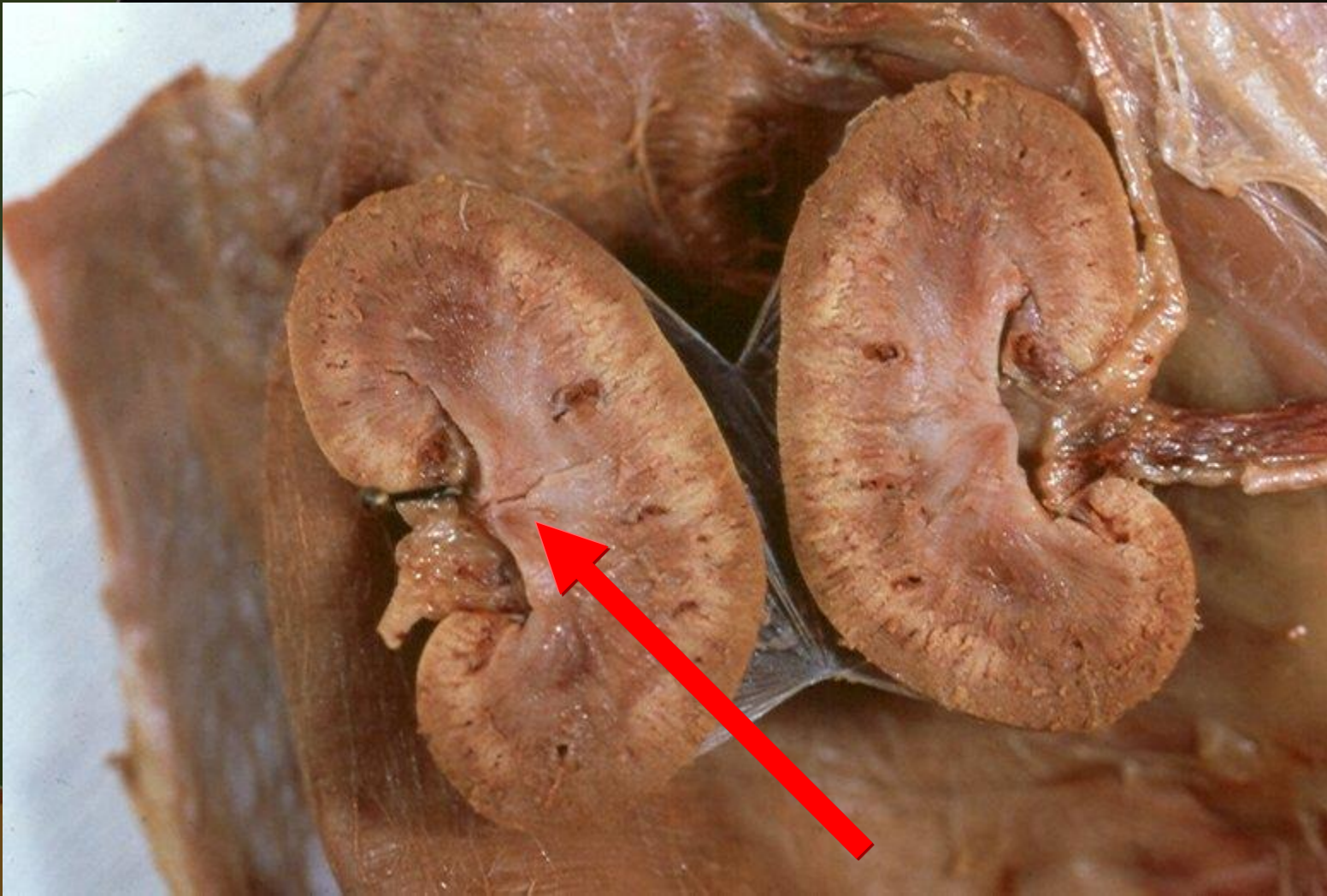
Renal cortex



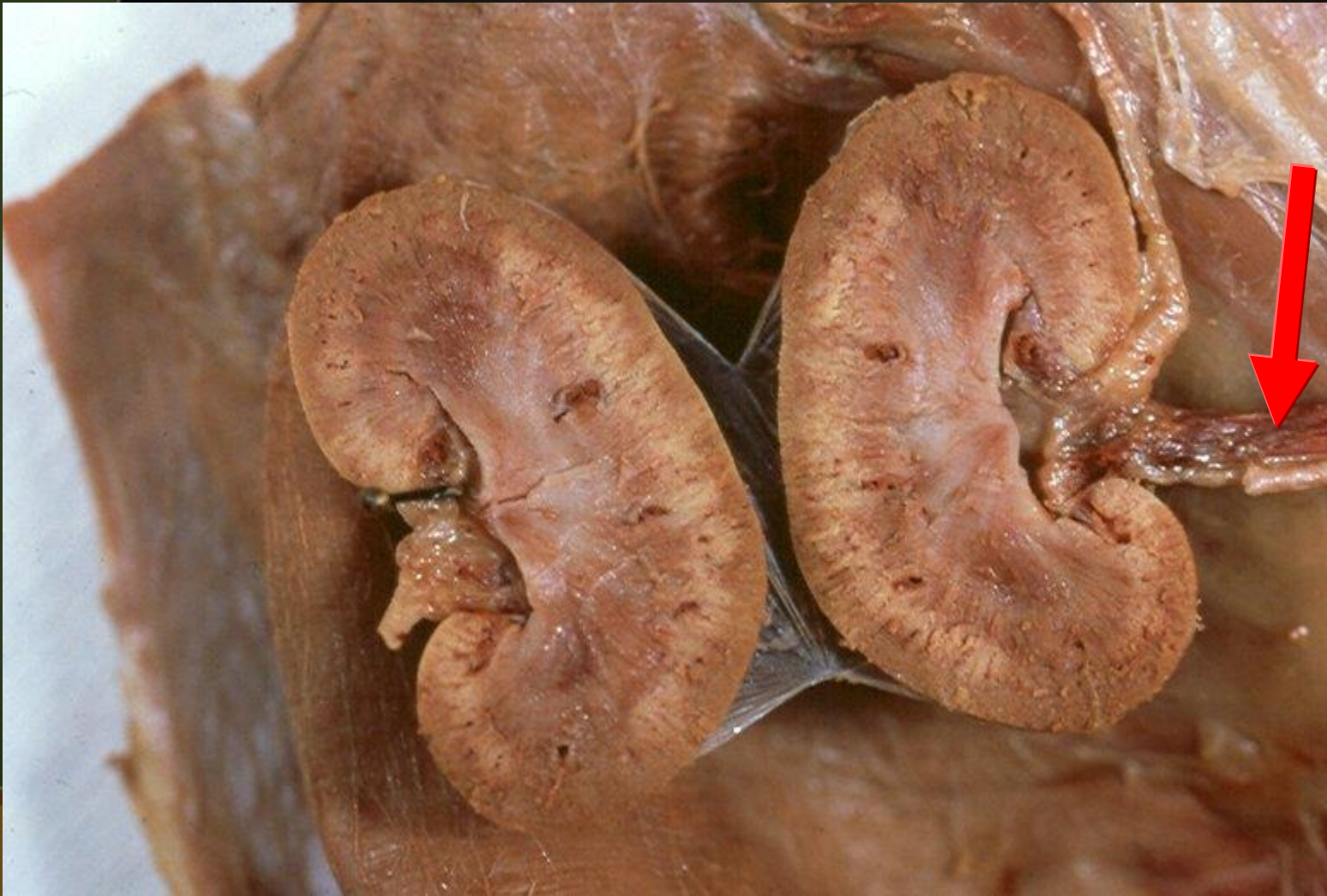Renal medulla



Renal pelvis



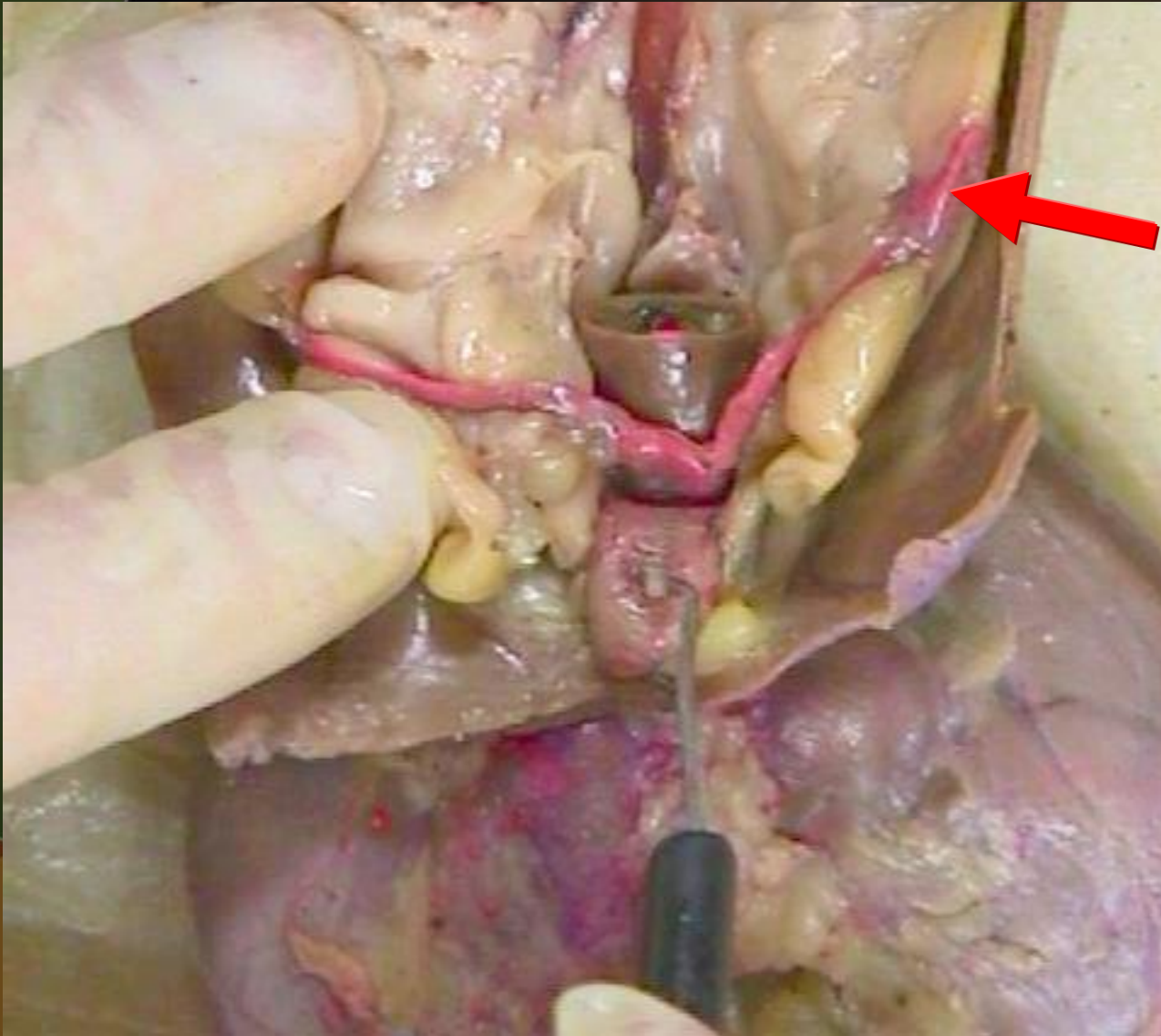
Renal Vein



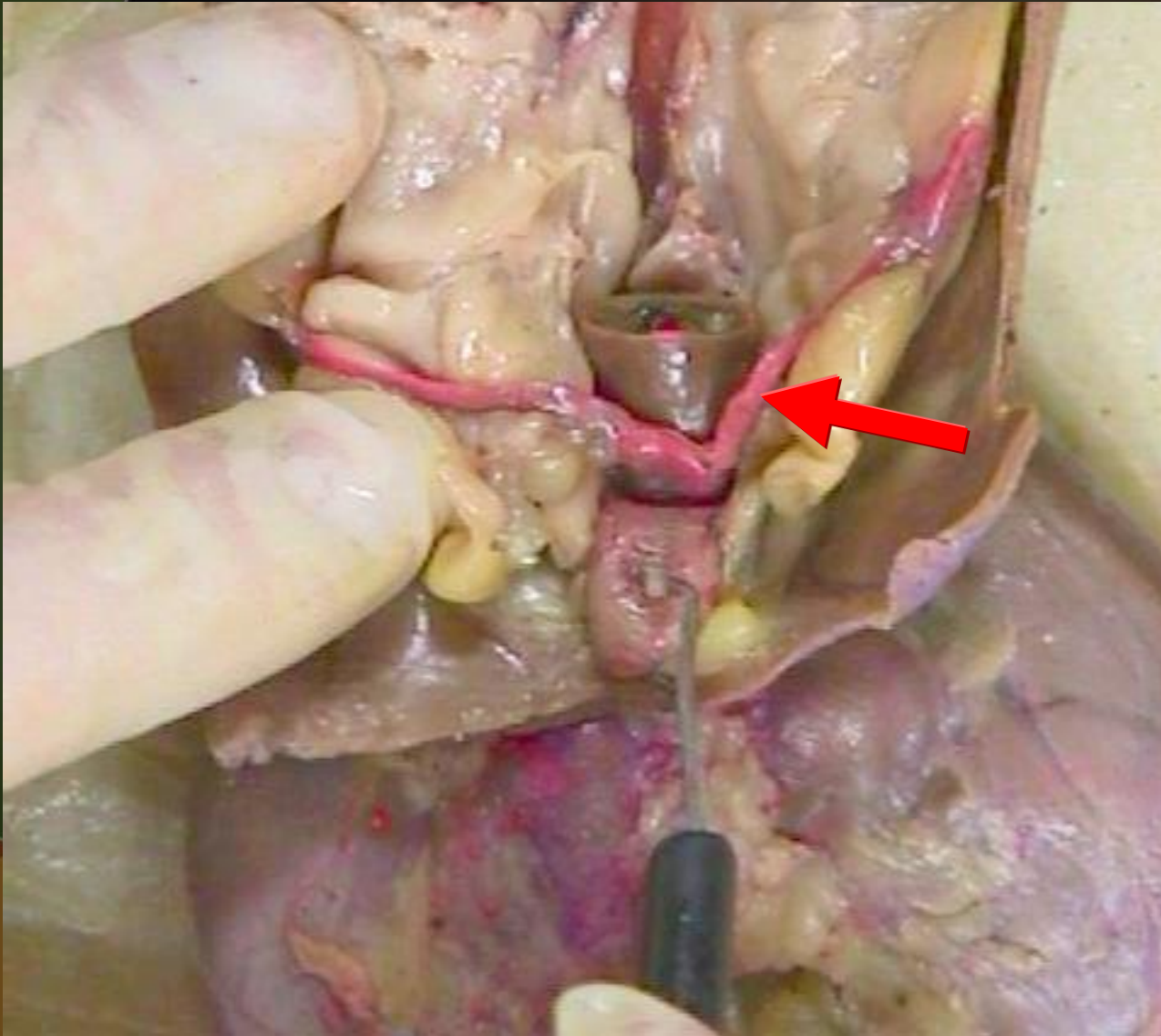
Reproductive Systems



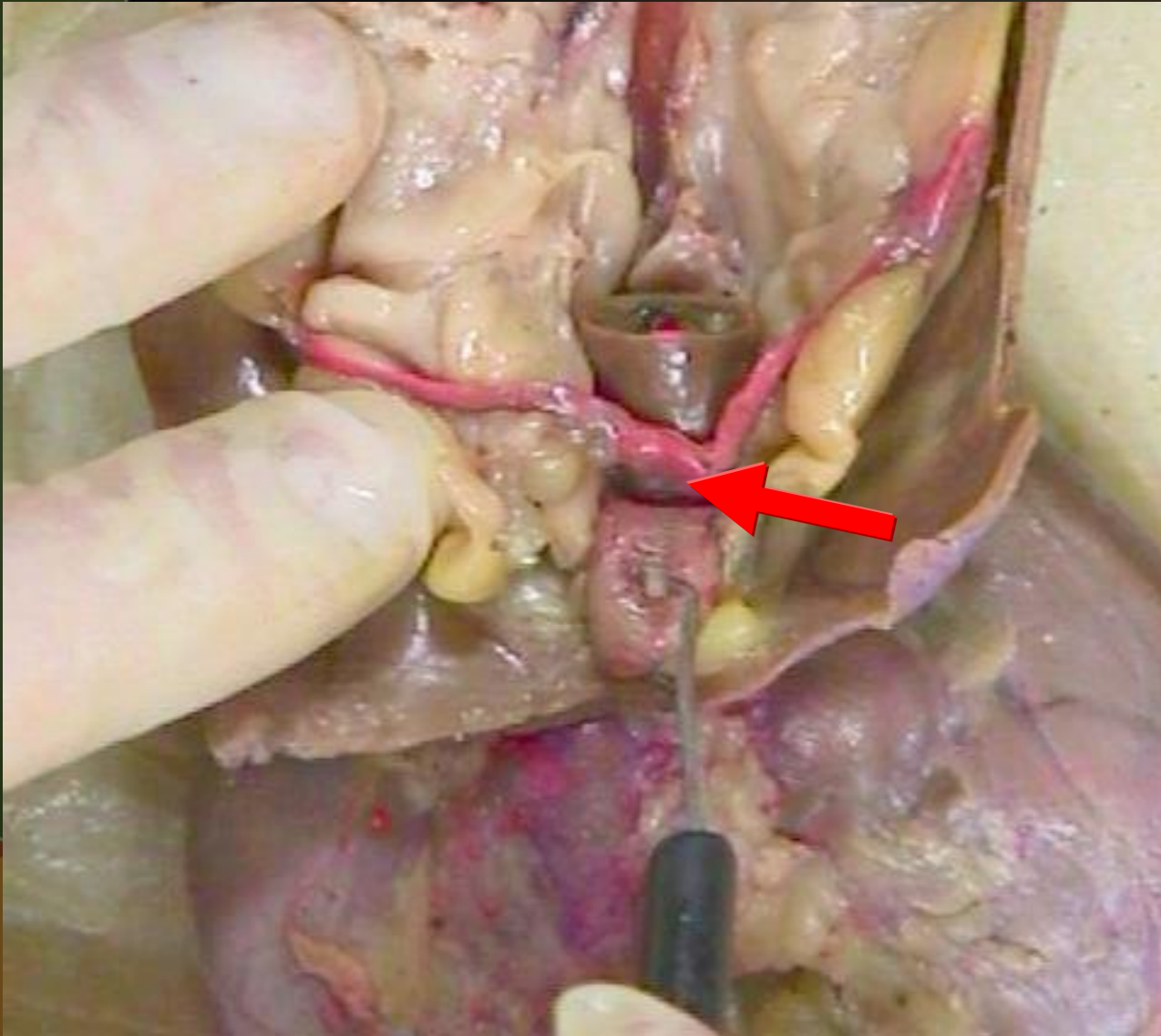
Ovary



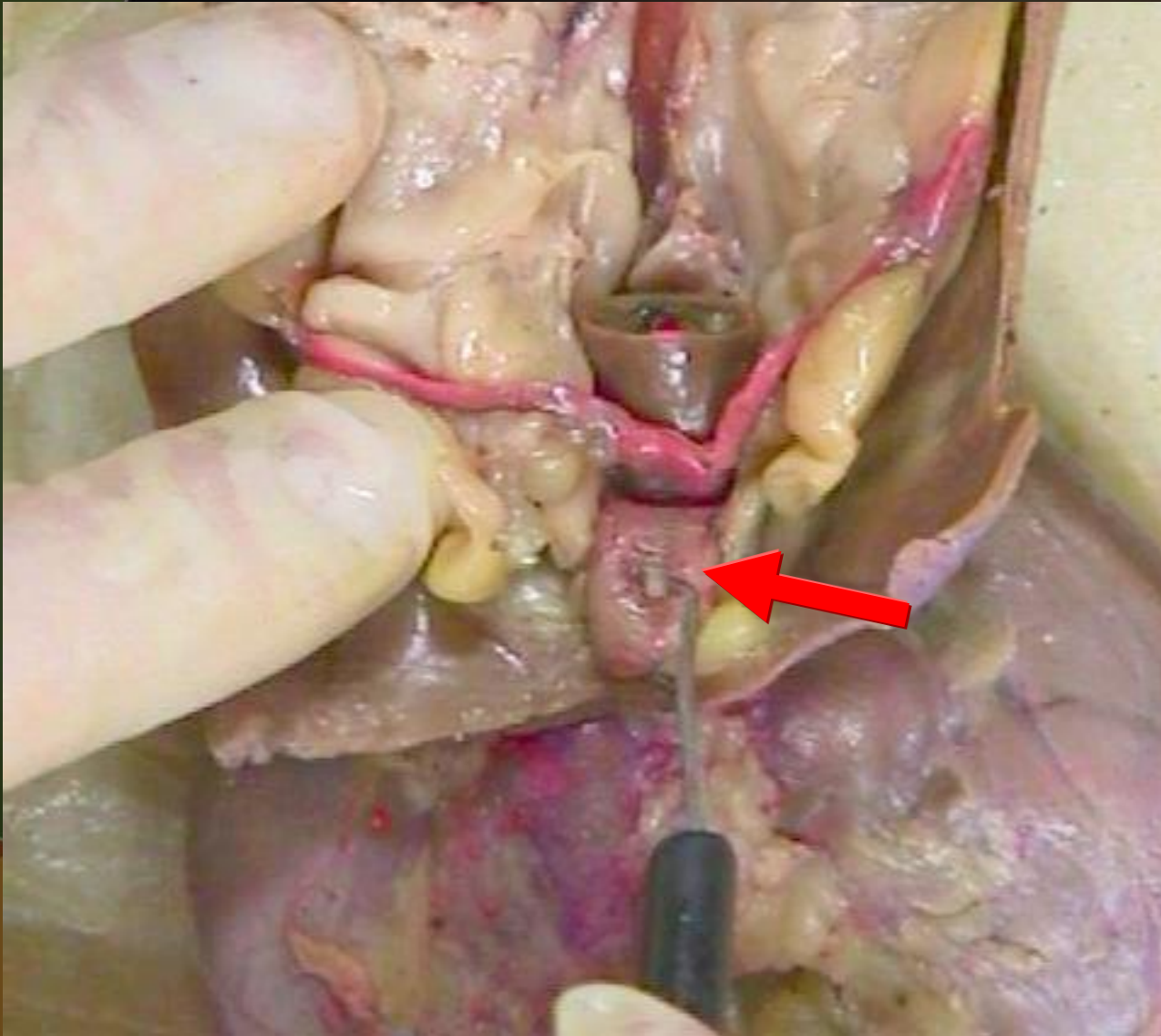
Uterine horn



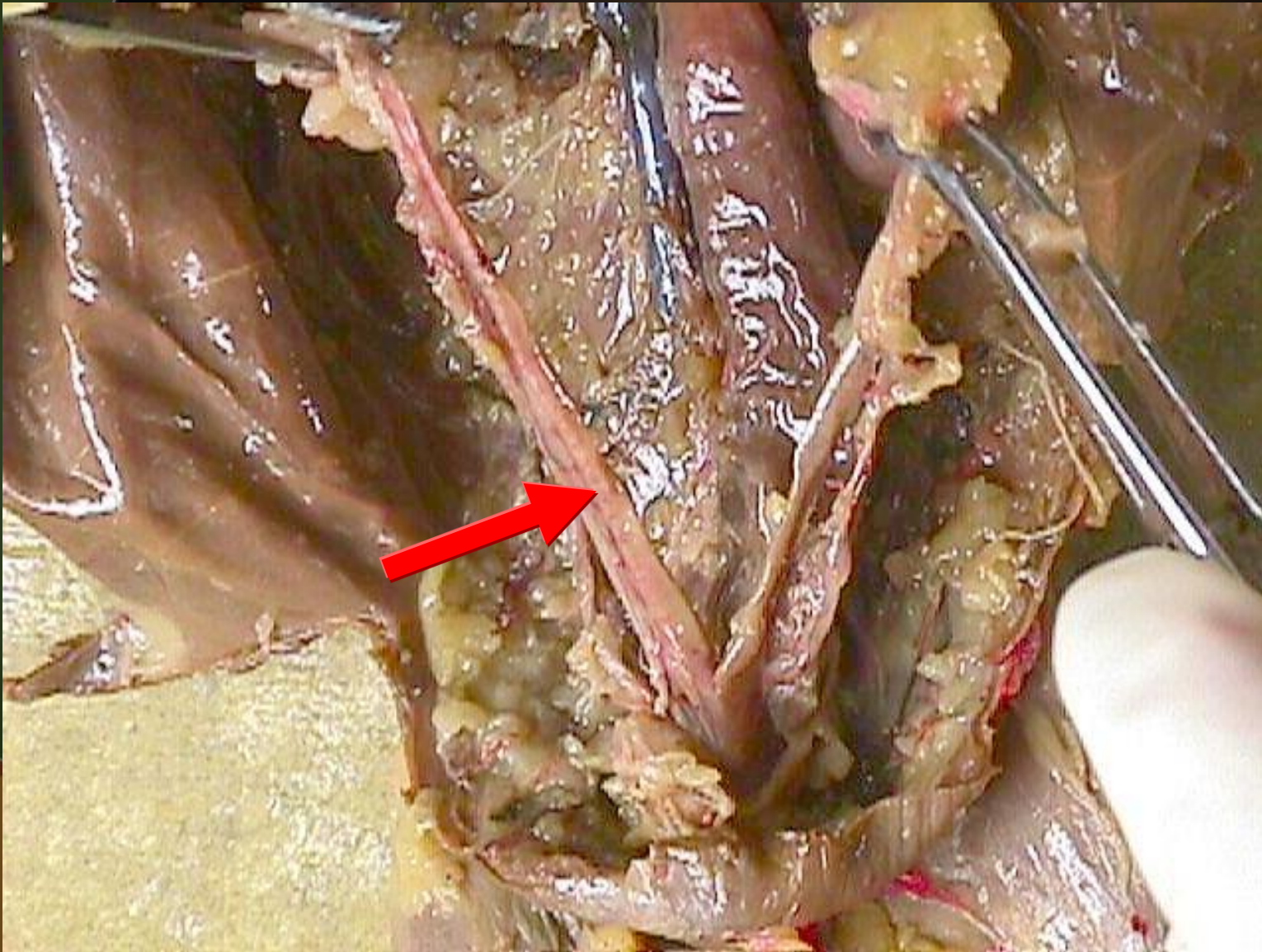
Uterine body



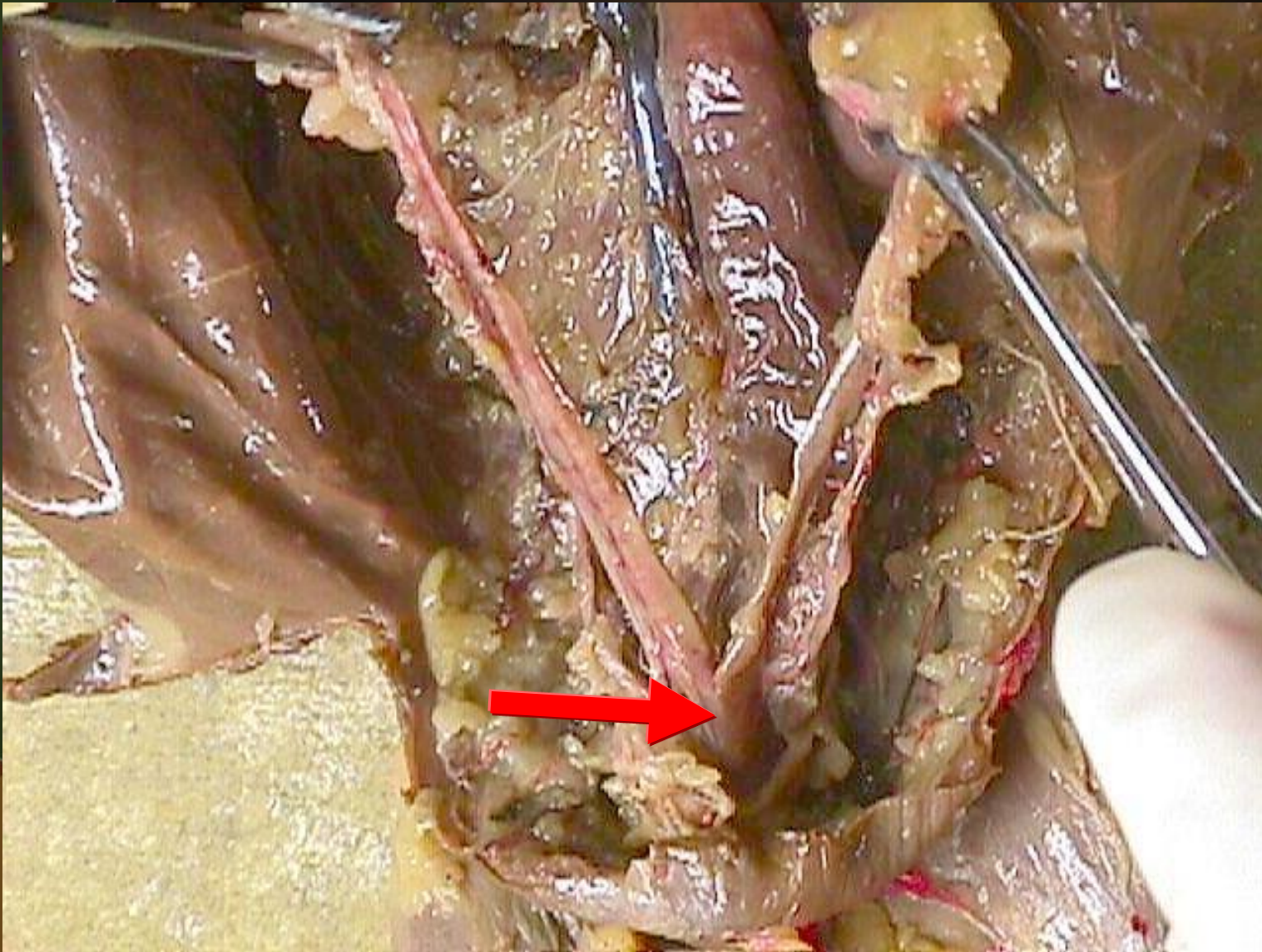
Urinary bladder



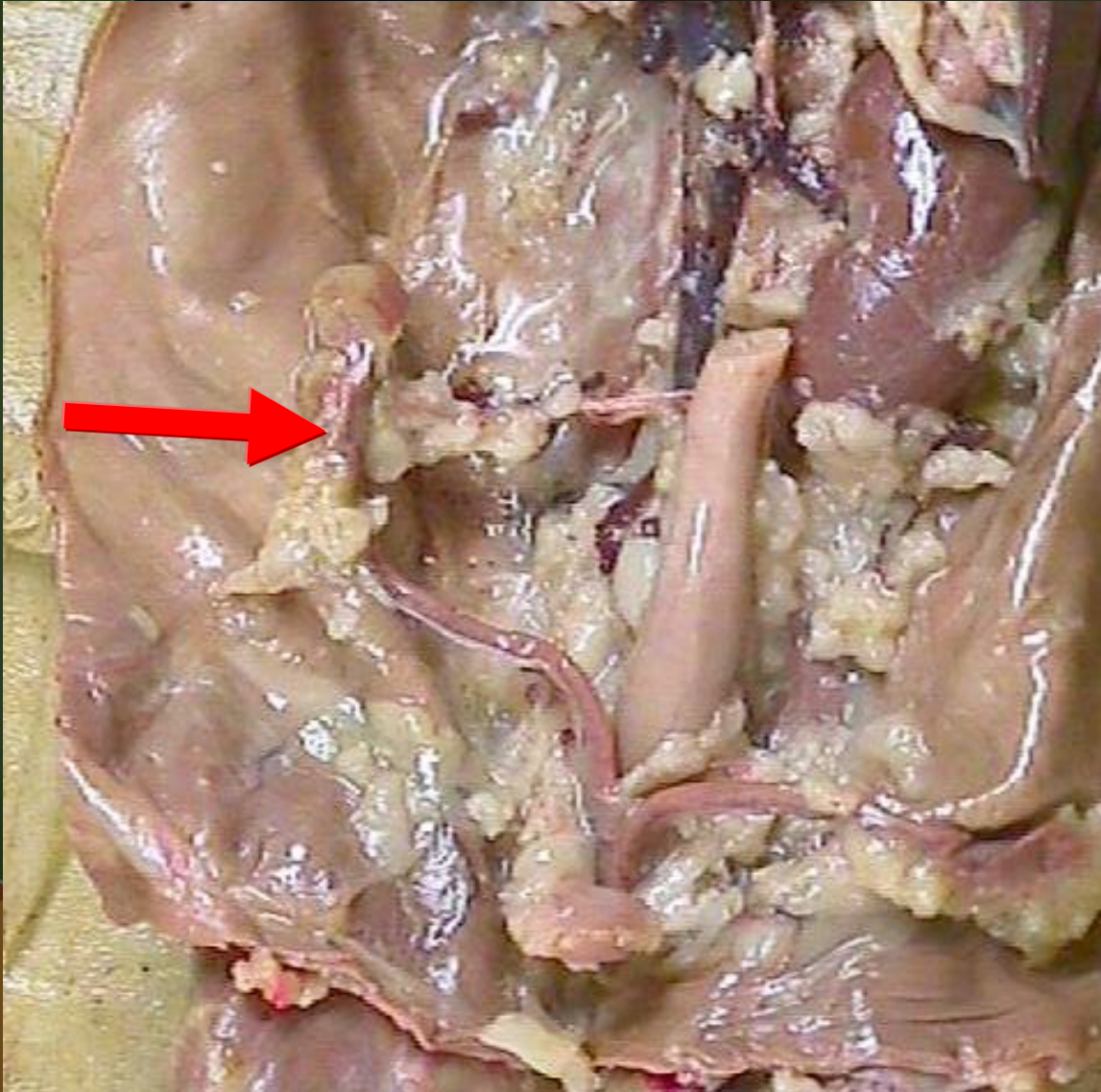
Uterine horn



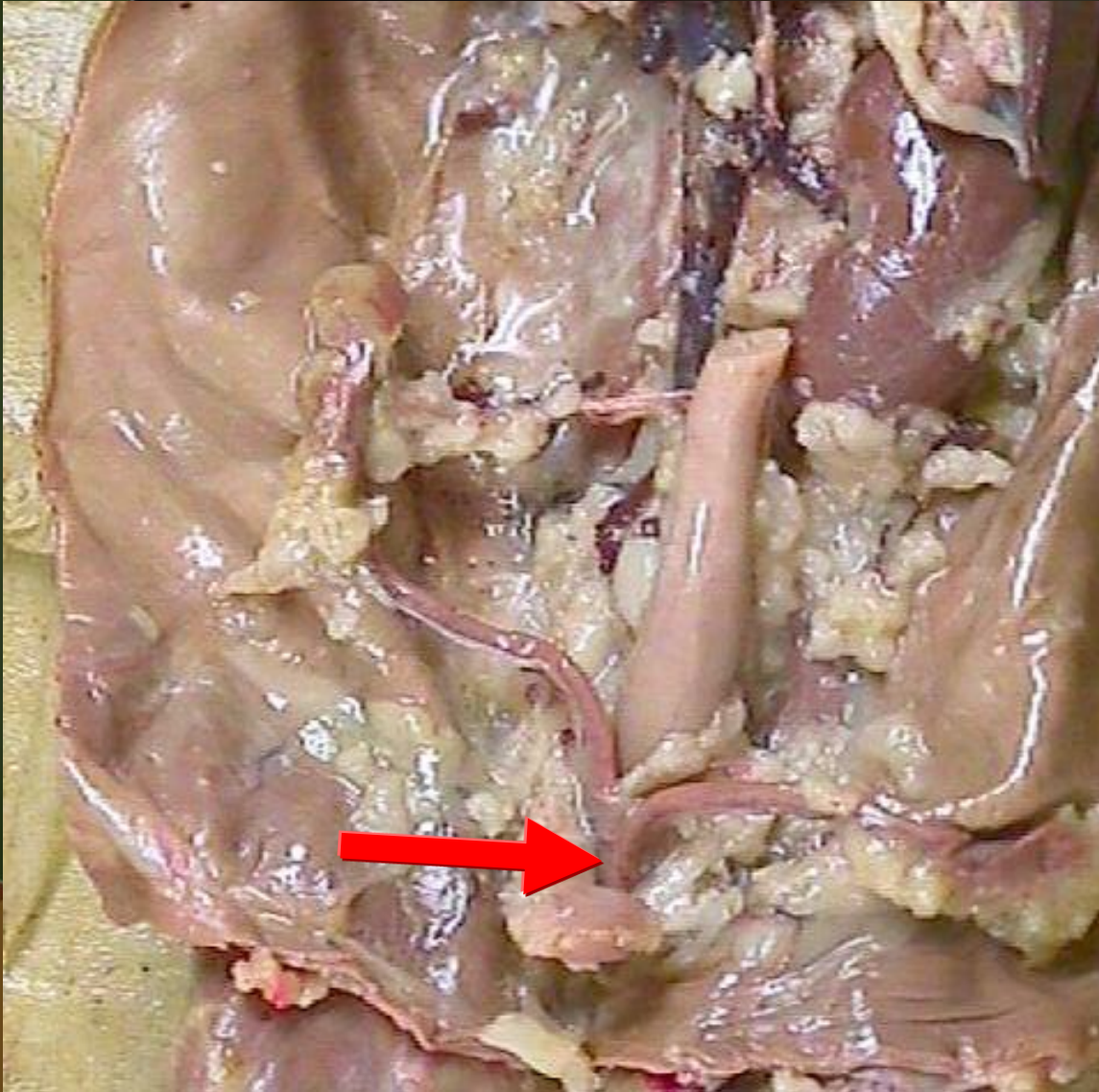
Uterine body



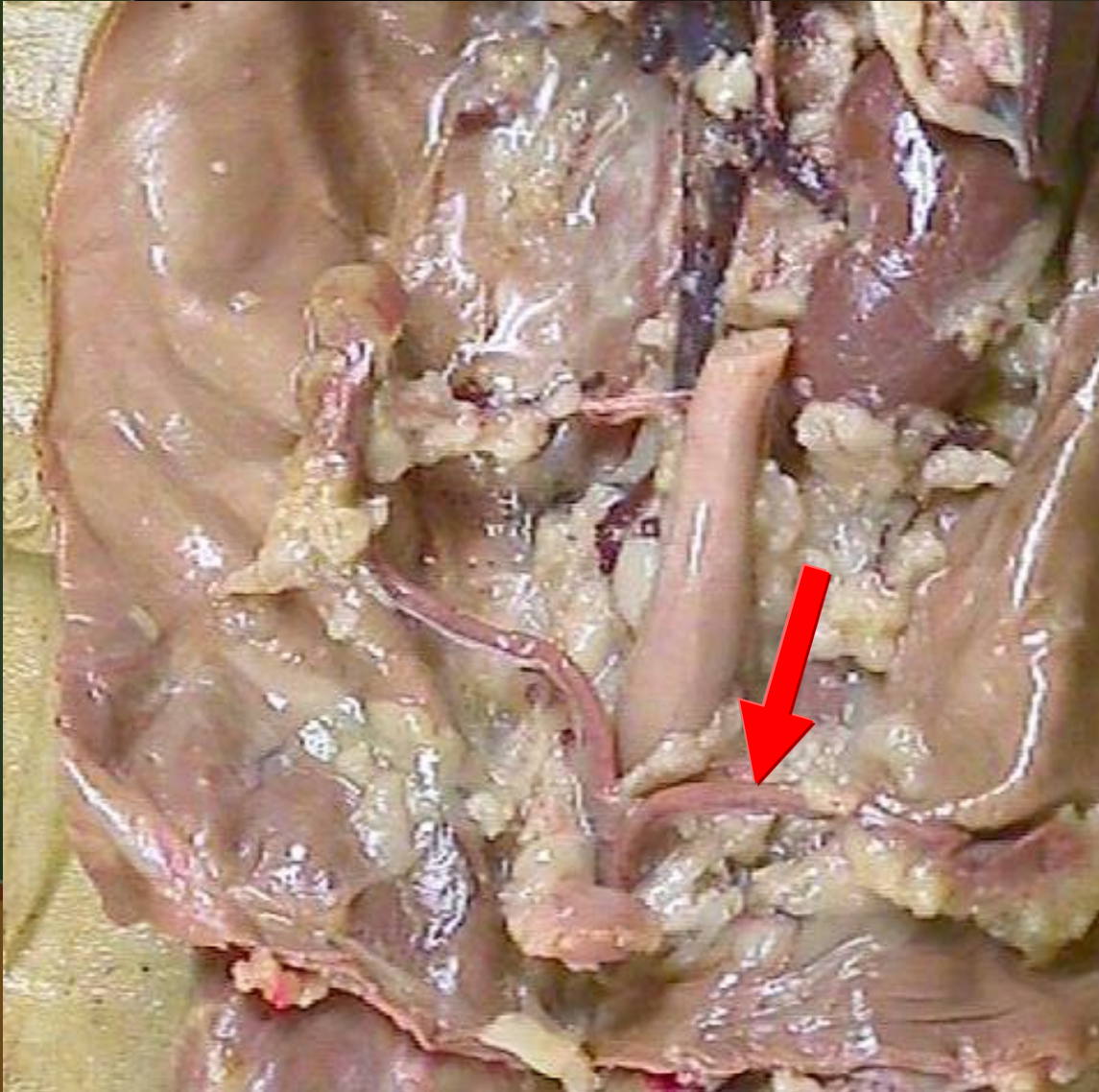
Ovary



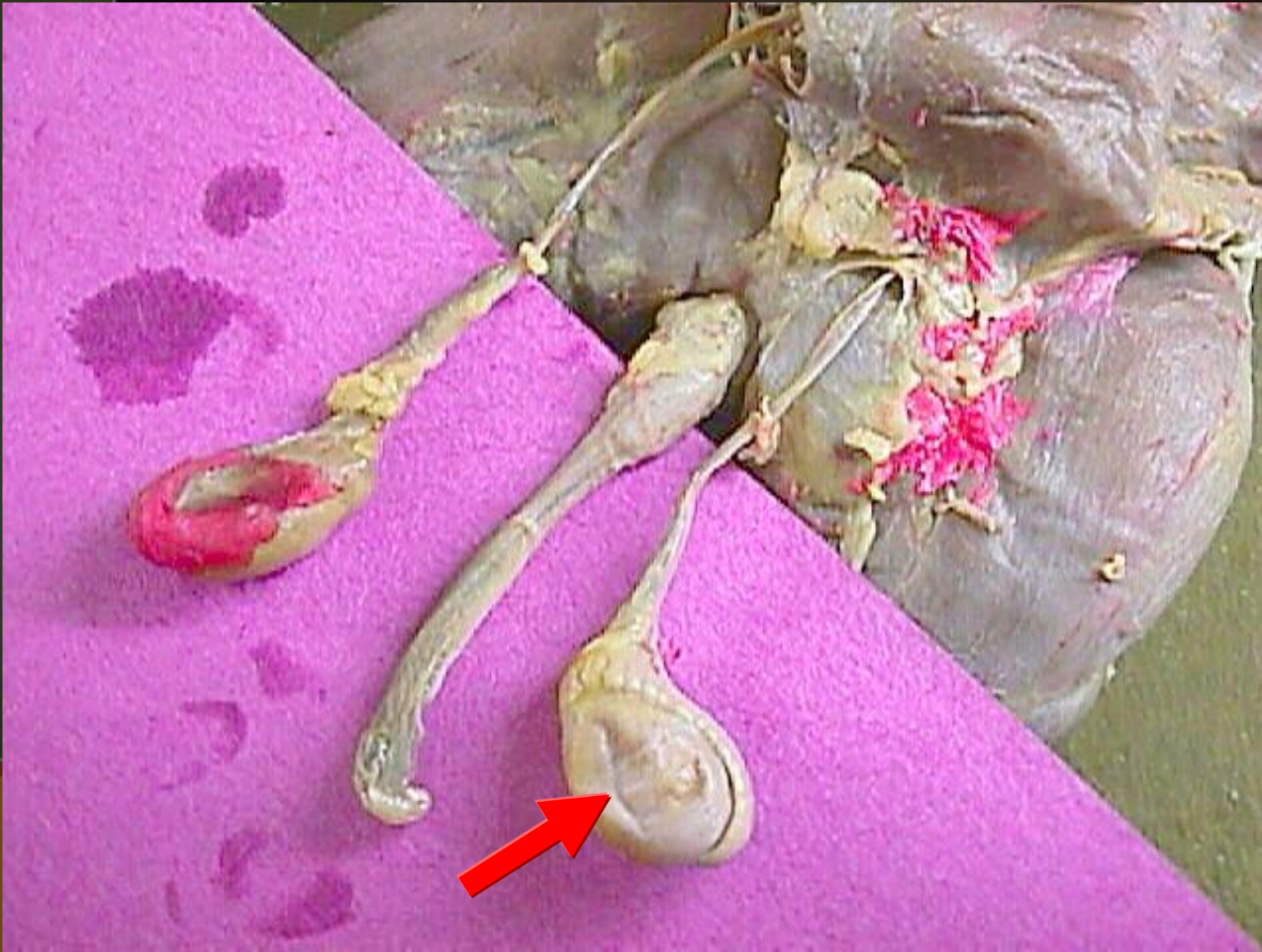
Uterine body



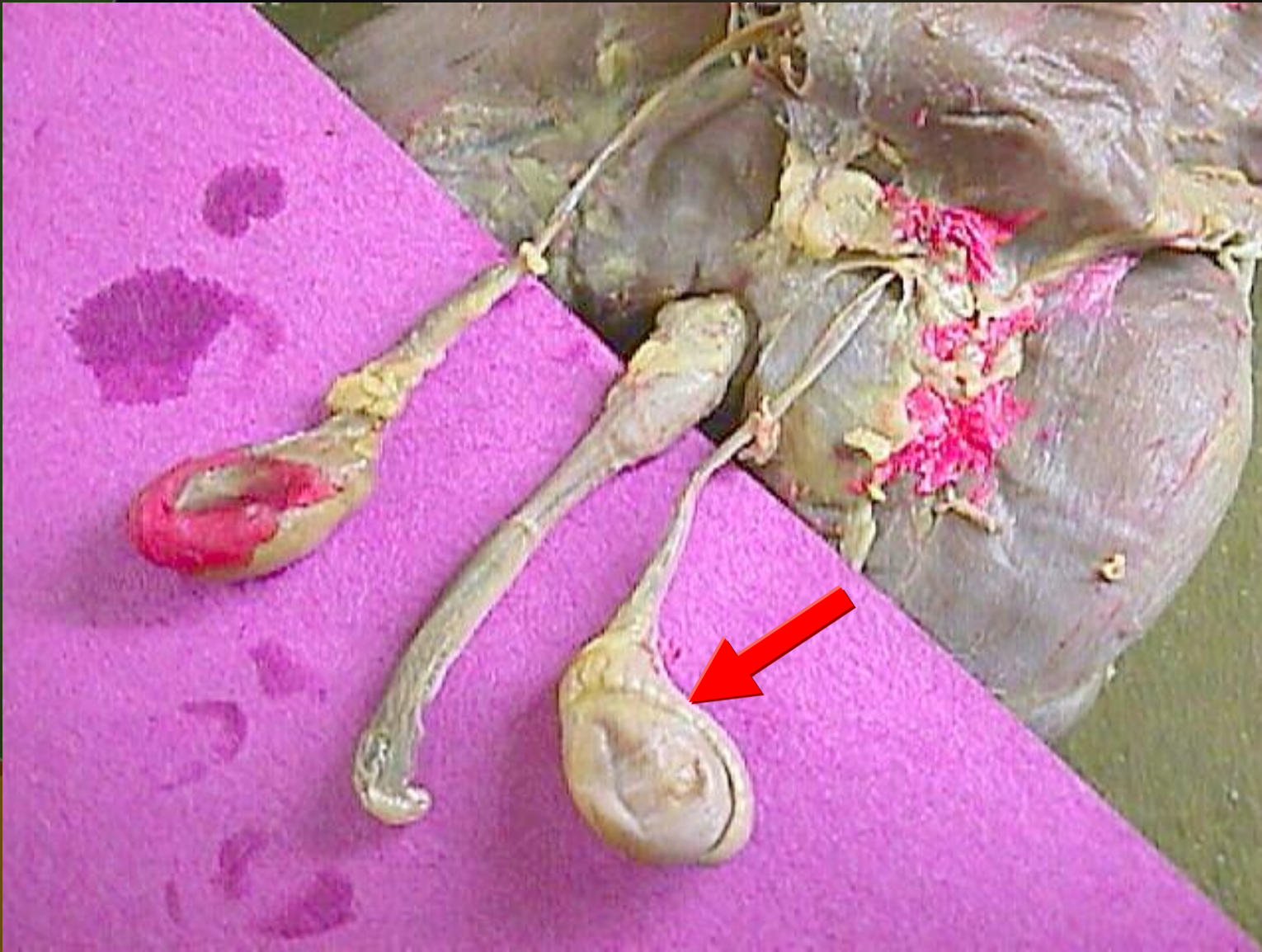
Uterine horn



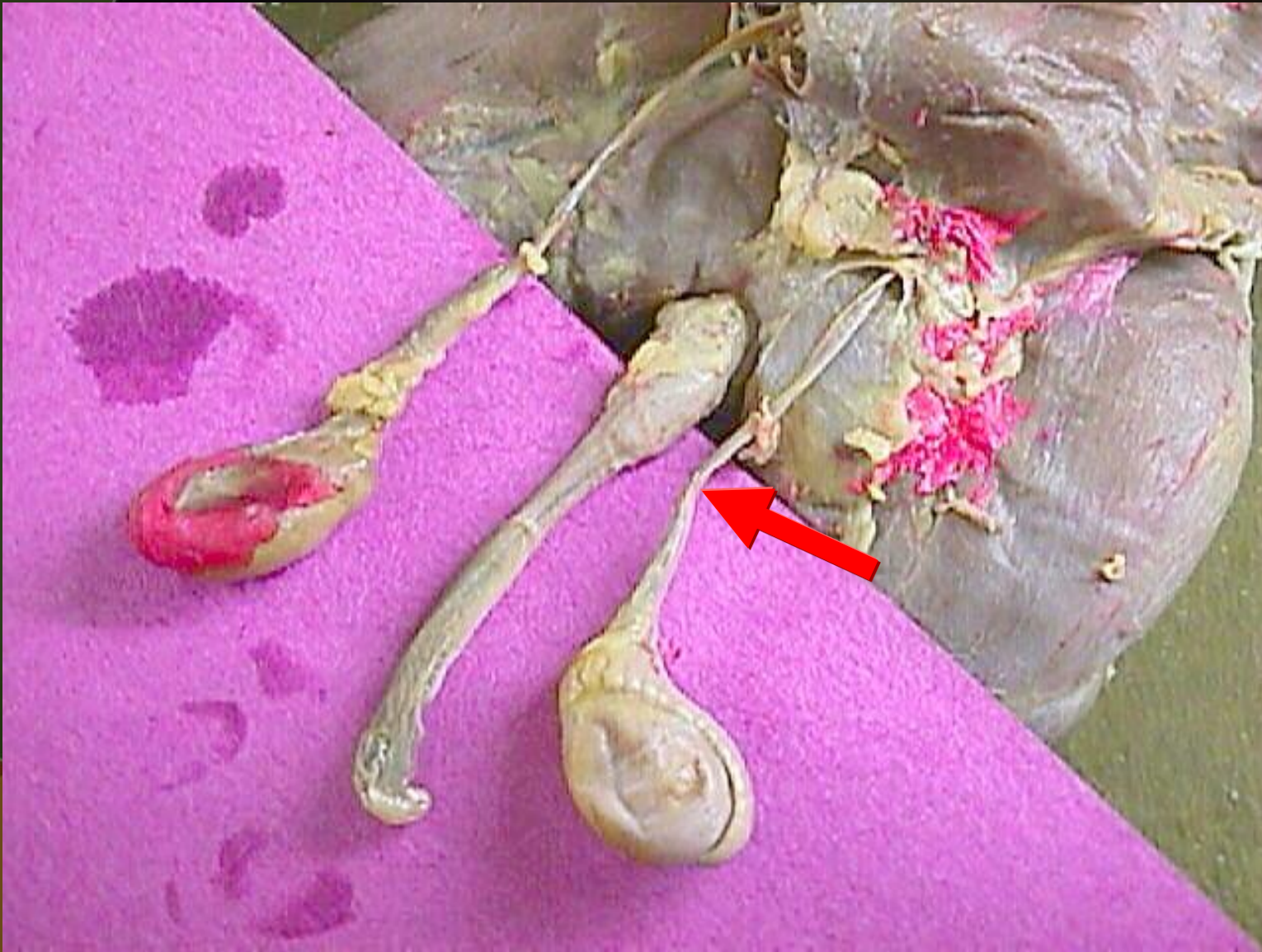
Testis



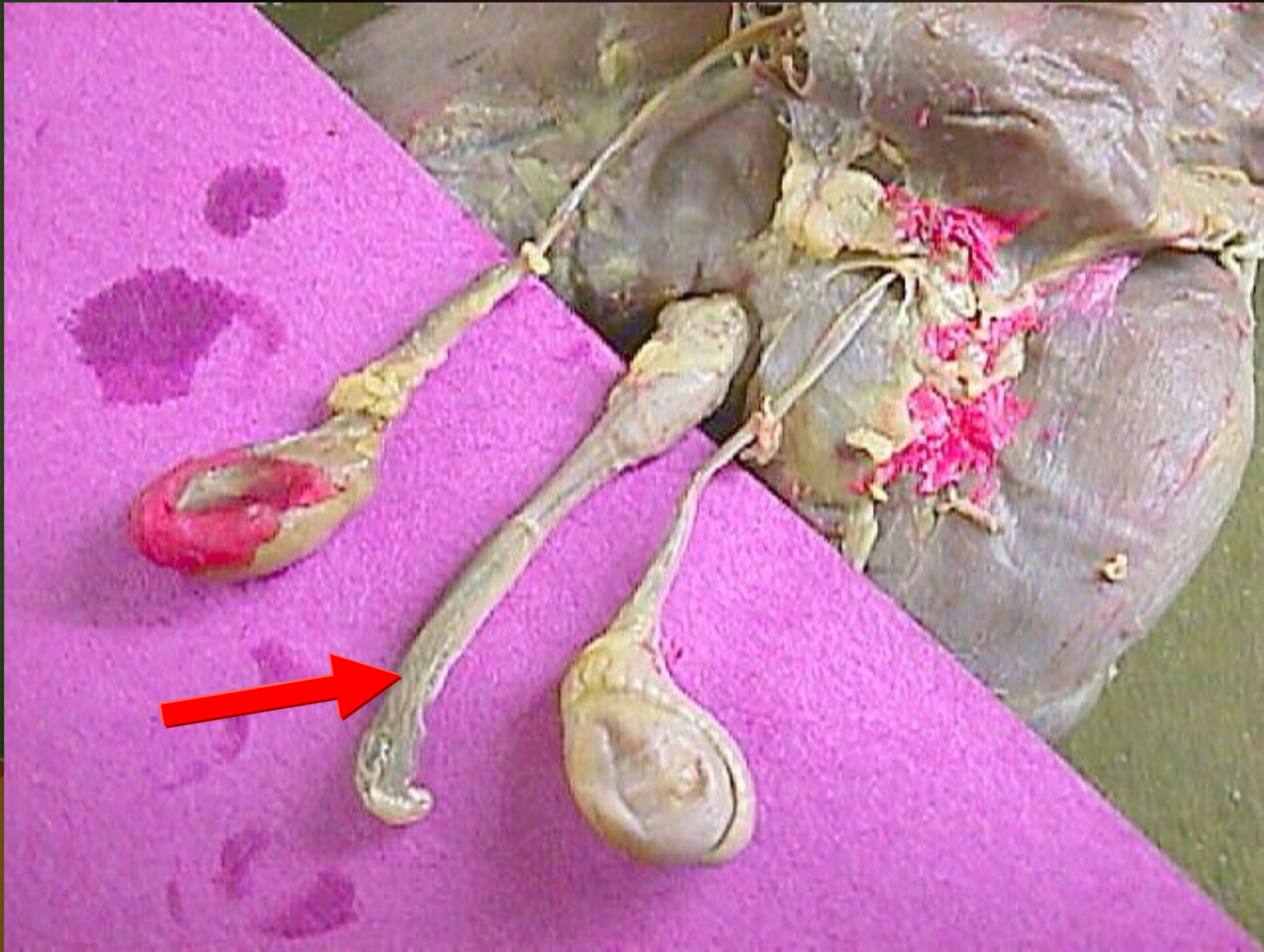
Epididymis



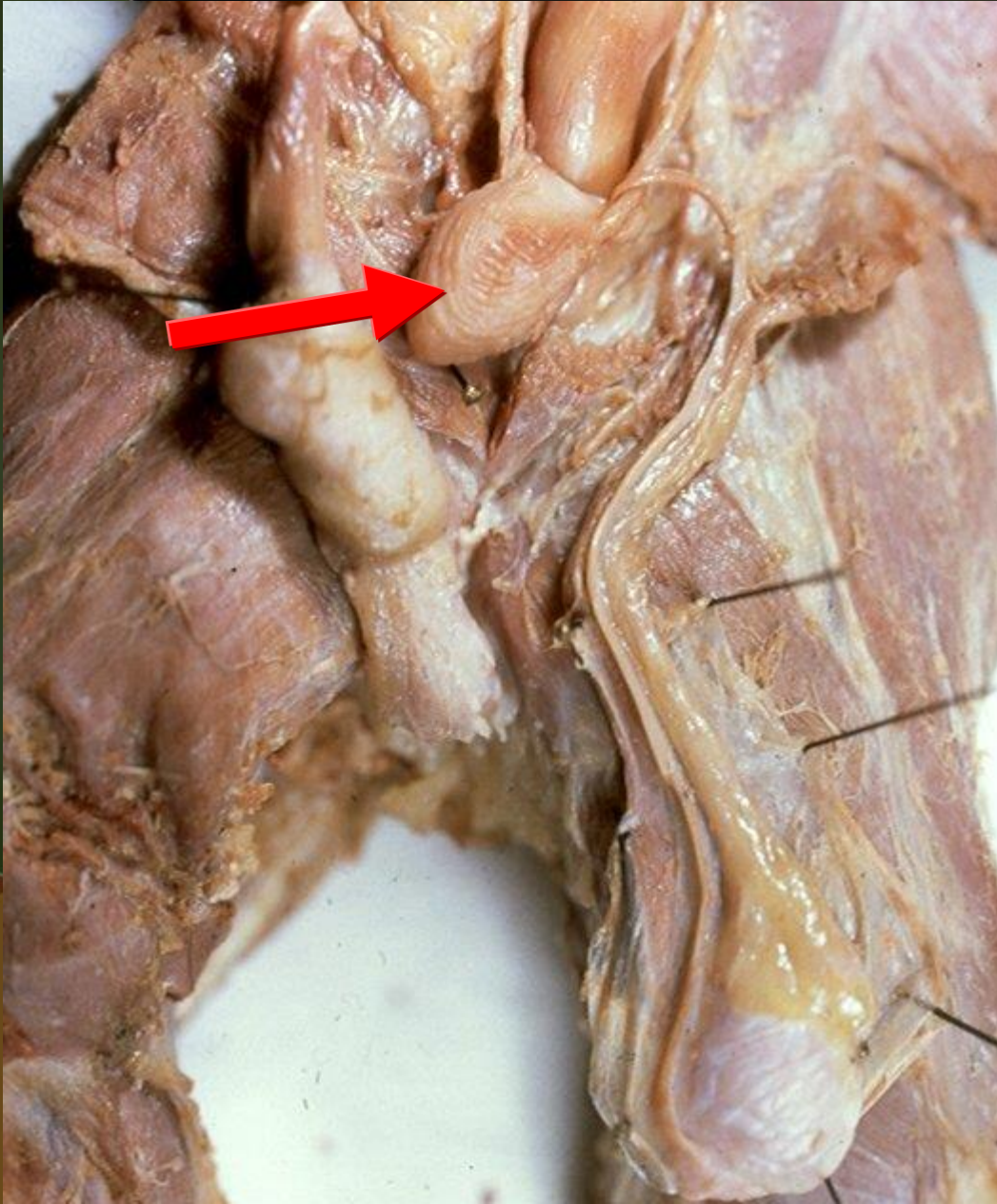
Vas deferens



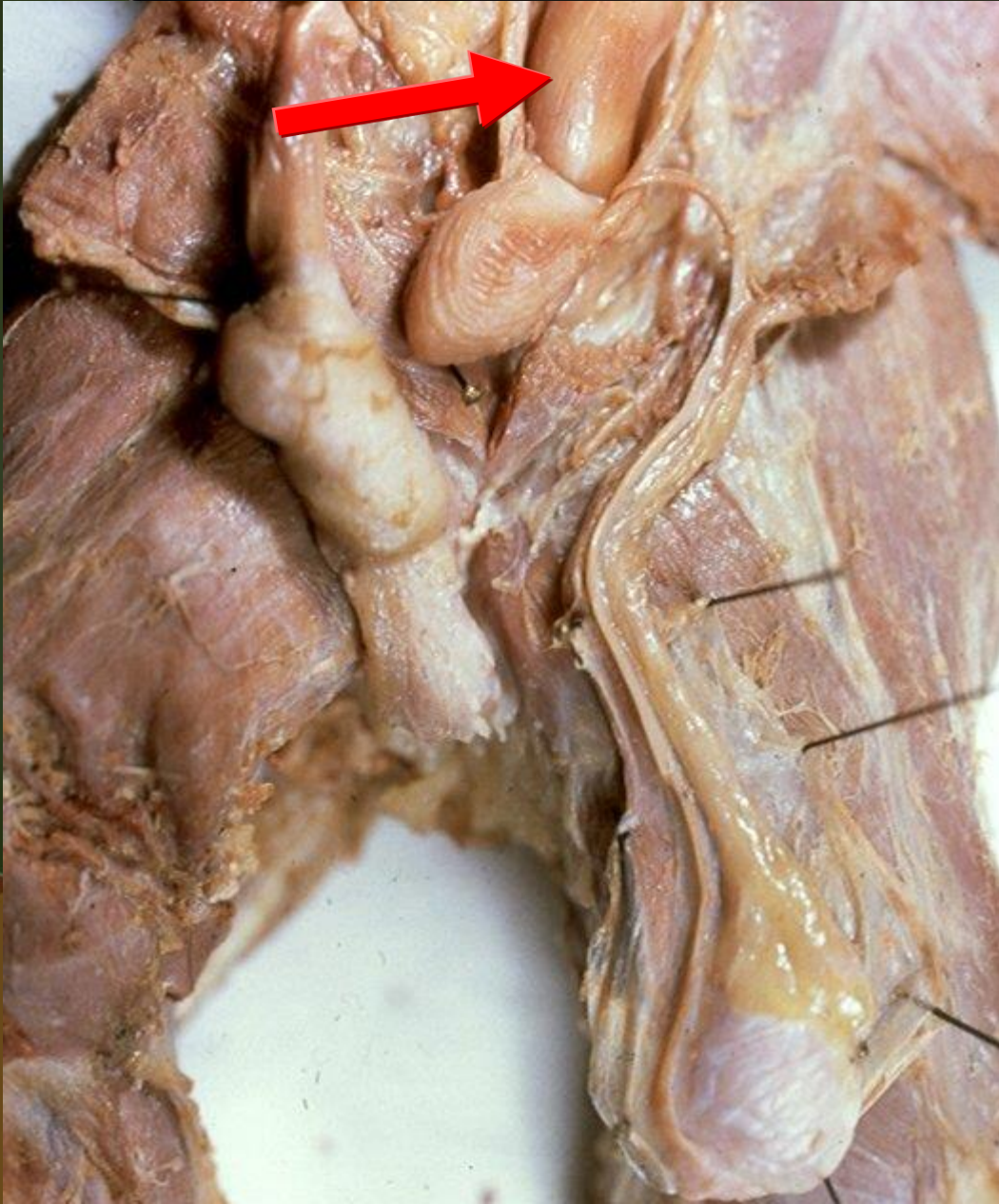
Penis



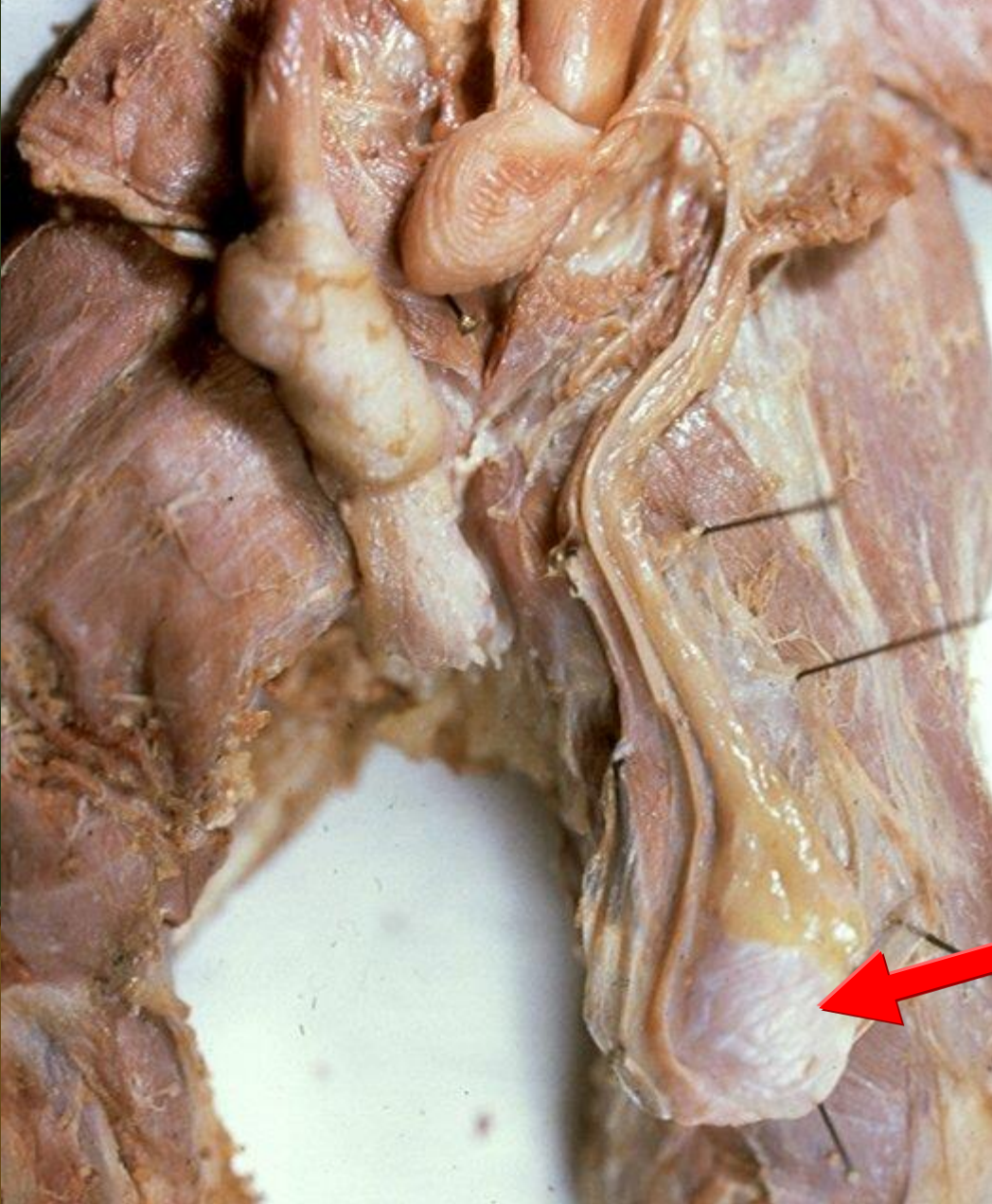
Urinary bladder



Rectum



Testis



Vas deferens

